Phil. Trans. R. Soc. Lond. B **306**, 159–189 (1984) [159]
Printed in Great Britain

THE STATOCYST–OCULOMOTOR SYSTEM OF *OCTOPUS VULGARIS*: EXTRAOCULAR EYE MUSCLES, EYE MUSCLE NERVES, STATOCYST NERVES AND THE OCULOMOTOR CENTRE IN THE CENTRAL NERVOUS SYSTEM

By B. U. BUDELMANN[1] and J. Z. YOUNG[2], F.R.S.
[1] *Zoological Institute, University of Regensburg, D* 8400 *Regensburg, F.R.G.*
[2] *The Wellcome Institute for the History of Medicine*, 183 *Euston Road, London NW*1 2*BP, U.K.*

(*Received* 15 *September* 1983)

[Plates 1–8]

CONTENTS

Seven extraocular eye muscles are described in *Octopus vulgaris*. There are three powerful recti muscles that produce linear movements and four oblique muscles producing rotation. Some of these oblique muscles are very thin sheets passing halfway round the eyeball. The eye muscles are controlled by seven nerves, but several of these innervate more than one muscle. Stimulation of the individual nerves produces the linear and rotatory movements, or both, to be expected from the morphological organization of the muscles they innervate. Two of the nerves run only to extraocular eye muscles, the other five contain additional fibres for the iris, chromatophores or skin.

Cobalt filling of the central ends of the eye muscle nerves showed that all have fibres originating in the ipsilateral anterior lateral pedal lobe which is the oculomotor centre. The two nerves whose stimulation gave expansion of the chromatophores of the iris were shown to contain fibres with somata in the ipsilateral anterior chromatophore lobe. Two nerves gave constriction of the pupil and proved to contain fibres with somata in an area between the posterior pedal and magnocellular lobes, demonstrating the position of a pupillary control centre. Stimulation of one nerve gave dilation of the pupil but the origin of the relevant cells remains unclear.

Cobalt filling of the central ends of the macula and crista nerves of the statocyst showed the destinations of their afferent fibres in many parts of the brain, including the oculomotor centre and higher motor centres of the basal and peduncle lobes. In addition, many somata of efferent fibres to the statocyst were filled in the oculomotor centre, in the posterior lateral pedal lobe, and in the posterior pedal and magnocellular lobes.

The statocyst–oculomotor system of *Octopus* thus includes two pathways from the statocyst equilibrium receptor organs to the motoneurons of the eyes: one direct pathway, and another indirect path via higher integrative centres where visual information about movement is combined with that coming from the statocysts. This situation points to a remarkable convergence between the *Octopus* statocyst–oculomotor system and the vestibulo-ocular system of vertebrates.

1. INTRODUCTION

Octopus, like many other cephalopods, shows pronounced compensatory eye movements under the control of equilibrium receptor systems and visual reflexes (Wells 1960; Dijkgraaf 1961; Budelmann 1970, 1976; Collewijn 1970; Messenger 1970, 1977; Hartline *et al.* 1979). As in vertebrates, these compensatory eye movements serve to avoid retinal image motion during active and passive head movements. They include linear and rotatory eye movements. In an unrestrained octopus rotatory movements may reach 80° in either direction. In restrained experimental conditions they are rather less (Budelmann 1970). In *Sepia* rotatory eye movements are in the range of about 45° (Budelmann 1975).

These eye movements are controlled by several extraocular eye muscles (Isgrove 1909; Glockauer 1915), but their arrangement and innervation have never been described in detail. In *Octopus*, six eye muscle nerves are known to leave the brain (Young 1971), but one of them has two roots which we now prefer to call separate nerves. The fibre compositions of the eye muscle nerves are complex: besides efferent motor fibres to the various eye muscles some of them include others for the pupil reflexes and for chromatophores of the iris and skin of the head, as well as afferent fibres (Young 1965). Therefore, some of the nerves have been called 'ophthalmic' and others 'oculomotor' nerves. The terminology is further confused by differences between octopods and decapods (Pfefferkorn 1915; Thore 1939; Tompsett 1939; Young 1971).

In *Octopus*, the position of the oculomotor centre in the lateral pedal lobe has been defined anatomically as well as by electrical stimulation (see Young 1971). This centre receives large afferent inputs from the equilibrium receptor organs in the statocyst (Young 1971; Colmers 1982). It also receives inputs from the higher motor centres in the peduncle lobe and anterior and median basal lobes, which have certain features analogous to the vertebrate cerebellum (Messenger 1967*a*, 1971; Hobbs & Young 1973; Young 1976*b*; Woodhams 1977).

In recent years the equilibrium receptor systems of the statocysts of *Octopus* for the detection of gravity and angular acceleration have been investigated in considerable detail, both morphologically and physiologically (Budelmann 1970, 1975, 1976, 1977; Budelmann & Wolff 1973; Budelmann & Thies 1977; Colmers 1977, 1981; Budelmann & Bonn 1982; Budelmann *et al.* 1984). The central afferent and efferent organization of the gravity receptor system has also been described (Colmers 1982).

In the present work we have tried to make the understanding of the *Octopus* statocyst–oculomotor system more complete, in various respects: (i) by dissection and staining of the extraocular eye muscles to show their exact arrangements and attachments to the cartilage and eyeball; (ii) by silver staining and centrifugal cobalt filling of the eye muscle nerves to show their course to and within the various eye muscles; (iii) by electrical stimulation of the nerves to analyse the function of their appropriate eye muscles; (iv) by centripetal cobalt filling of the eye muscle nerves to analyse the origin and course of their efferent motor fibres; (v) by centripetal cobalt filling of all nerves innervating the statocyst equilibrium receptor systems to trace their central afferent and efferent projections; and (vi) by cobalt filling of the fibres from the statocyst to the peduncle lobe to trace their origin in the statocyst receptor epithelia.

This work is part of a more detailed analysis of the uptake and central processing of information from equilibrium receptor systems in the statocysts of cephalopods, which is concerned with the statocyst–oculomotor system.

2. MATERIALS AND METHODS

All *Octopus vulgaris* (50–450 g, both males and females) used in this study were obtained from the Gulf of Naples. Some of the stimulation and cobalt filling experiments were performed at the Stazione Zoologica di Napoli. All the others were done at the University of Regensburg; there the animals were kept separately in a closed circulation of artificial seawater at 15–18 °C. The experiments were performed on both the right and left side of the animals, but to compare the results more easily, especially those involving the directions of the eye movements, all results are reported as being from the left eye, throughout the text and the figures. The terminology of the *Octopus* eye muscle nerves and central nervous system (c.n.s.) is based on Young (1971).

2.1. *Anatomy of the extraocular eye muscles and their innervation*

Ten *Octopus* were used for this study. The muscles were first described in preparations in which, after formol fixation (4 %), the skin was removed and the whole eye lightly stained with haemalum. In later preparations the eyeball was opened by a cut around the margin at the edge of the argentea taking away the iris and lens. The eye muscles were then separated from their attachments to the eye, and the white body and other contents of the orbit carefully removed. The attachments to the cranium were then severed and the muscles removed as a ring, their nerves being peeled away from the cartilage. After removal of the connective tissue from both inner and outer surfaces the muscles were lightly stained with haemalum and cleared in glycerine and viewed from various aspects. After cutting open the ring the muscles were mounted as flat preparations under a cover slip. For the course of their fibres, some muscles were viewed with a Zeiss polarization microscope fitted with a γ Quartz Rot I colour filter. Some details of the nerve fibres were studied in preparations stained with the Bielschowsky method and mounted in Canada balsam.

2.2. *Stimulation of the eye muscle nerves*

Seven *Octopus* were used for this study. The animals were decapitated without prior anaesthesia and the arms and body removed. The isolated head preparation was pinned in a dish and kept under cooled seawater of 10–15 °C. The skin over the top of the head and around the eyes was removed. The cranium was opened dorsally and the brain jelly carefully removed. Each nerve was stimulated through a single fine silver wire hooked under it to act as a cathode with the distant anode in the bath of seawater surrounding the preparation.

Bursts of square wave stimuli, each 10 ms in duration and with a frequency of ten per second, were given by a Grass SD 9 stimulator. The voltage varied between 10 and 20 V. The preparations were cooled with fresh seawater at intervals and continued to respond for up to 2 h. Each nerve was stimulated several times with bursts lasting a few seconds and the movements of the eyes were recorded visually using the notation of a clockface to indicate the directions. In each animal the experiments were made with all the seven eye muscle nerves of both the left and right side (with a few exceptions), beginning with the superior ophthalmic nerves (table 3).

2.3. *Centripetal cobalt filling of the eye muscle nerves*

Isolated head preparations of 20 *Octopus* were used. The preparation was kept in seawater and the left or right eye, optic lobe and peduncle lobe were removed. The ophthalmic or oculomotor nerve in question was dissected from its surrounding muscle and connective tissue and cut close to the point where it passes through the orbital cartilage on its way to the brain. The anterior and posterior root of the posterior superior ophthalmic nerve and the inferior ophthalmic nerve were cut centrally to their ganglion, except where otherwise stated. The cut end of the nerve was dilated for a few minutes with distilled water and introduced into a matching polyethylene suction electrode filled with a 1.0 M $CoCl_2$ solution. The Co^{2+} ions were injected iontophoretically into the nerve fibres by passing positive current pulses (six per second, 13–15 μA, 100 ms in duration) for 15–25 h at a temperature of 3–5 °C. Subsequently, the brain was dissected from its cartilaginous capsule and the Co^{2+} ions were precipitated as black cobalt sulphide by treating the c.n.s. tissue with saturated ammonium sulphide (about one drop per millilitre of seawater) for 5–10 min. The tissue was fixed in a 10% formaldehyde–seawater solution, with a few drops of glacial acetic acid added, for 2.5–6 h, dehydrated in graded ethanol solutions and cleared in cedar wood oil.

A first analysis of the course of the stained fibres and the location of the somata of the motoneurons was made by viewing the whole brains under low magnification. Photographs were taken with a Wild M 400 photomacroscope, using various illumination techniques (incident light, bright- or dark-field transmitted light, or a combination thereof). For a further analysis the c.n.s. preparation was embedded in Epon A and sections were cut with a Reichert sliding microtome at 40 μm. From those sections stained with Co^{2+} ions the Epon was dissolved away with a solution of 1% NaOH in ethanol (5 ml), acetone (20 ml) and petroleum benzine (20 ml) for about 15 min. Thereafter the sections were hydrated back to water and individually intensified with a modified Timm's method (Tyrer & Bell 1974). After counterstaining with Richardson blue, the sections were dehydrated in graded ethanol solutions and covered with Depex–xylene (9:1).

2.4. *Centrifugal cobalt filling of the eye muscle nerves*

Twenty-five eye muscle preparations made from 14 *Octopus* were used. The isolated head preparation was kept in seawater and cut in the sagittal plane, giving a left and a right eye muscle preparation. The brain tissue was removed and the eye muscle nerve in question was cleaned intracranially from its surrounding brain jelly. The nerve was cut close to the point where it passes through the cranial cartilage on its way to the eye muscles. The further treatment of the nerve was as for the cobalt fillings towards the brain. Before dehydration and clearing the eye muscle tissue the eye ball was removed. The eye muscles were either left attached to the cranial cartilage, or the muscle(s) in question was cut out of the muscular ring. For the analysis of the course of the stained fibres whole mounts of the muscular ring or part of it mounted as a flat preparation under a cover slip were used.

2.5. *Centripetal cobalt filling of the statocyst nerves*

In 12 *Octopus* the isolated head preparation was kept in seawater and the eye of one side was removed, leaving the optic and peduncle lobes intact and the brain capsule unopened. The statocyst cavity was opened ventro-laterally on the same side, the nerve dissected from the statocyst sac and cut close to the point where it enters the cartilage on its way to the brain. The further treatment of the preparations was as for the eye muscle nerves. We could not make successful preparations of the anterior crista nerve because its widely spread fibres do not form a compact bundle before entering the cartilage on its way to the brain.

2.6. *Cobalt filling of fibres running between the peduncle lobe and the statocyst*

In eight *Octopus* the eyeball and white body were removed and the optic tract cut centrally to the peduncle lobe. The optic tract includes the tract of fibres that runs between the statocyst and the peduncle lobe. The further treatment of the cut end of the optic tract was as for the cobalt fillings of the nerves described above. Before precipitation of the Co^{2+} ions as cobalt sulphide, the statocyst sac was opened ventrally allowing careful removal of the statolith. The endolymph was then washed out with a fine jet of seawater.

2.7. *Limits of evidence of the cobalt filling technique used in this study*

The whole-nerve cobalt filling technique has some limitations which have to be considered in any interpretation of the data obtained.

(i) The results can not be taken as being quantitative. In cutting a nerve some fibres, especially the very fine ones, are sealed and there is no assurance that all of them will be made accessible for the Co^{2+} ions by the treatment of the cut end of the nerve with distilled water. Consequently, it can not be ruled out that some small-diameter fibres exist that were not traced in this study.

(ii) Unlike filling a single cell, whole-nerve impregnations result in a meshwork of stained afferent or efferent fibres, or both. Therefore, in a neuropil it is often very difficult to decide whether both afferent and efferent fibres are present. This limit of interpretation becomes even more obvious when efferent fibres give rise to collaterals.

(iii) It has been reported in insects that Co^{2+} ions can migrate from one cell to another (Strausfeld & Obermayer 1976). However, in this study, and in previous ones (Budelmann & Wolff 1976; Colmers 1982; Budelmann *et al.* 1984), there was no sign of evidence for such a cobalt coupling. There also was no sign of extracellular cobalt migration.

(iv) When blood vessels run together with nerves, these may also be filled with Co^{2+} ions and can cause some background staining. However, even very fine vessels could easily be distinguished by light microscopy from the stained neuronal fibres.

3. Results

3.1. *Anatomy of the extraocular eye muscles*

The extraocular eye muscles are best described as seven muscles (table 1), four thick and powerful and three thin sheets (figures 1–4 and 8–12, plate 1). Three of the thick muscles consist of nearly parallel fibres and run more or less straight across the anterior, superior or posterior part of the eyeball. Experiments show that they cause linear movements forwards, upwards and backwards, with little rotation. We propose to call these 'recti muscles'. The remaining muscles run obliquely around the circumference of the eyeball. The fourth powerful muscle is a posterior inferior oblique, consisting of two sets of fibres which cross and have slightly different orientation. The three thin sheets run for long distances round the eyeball, and they act as rotators. They are named 'anterior' or 'posterior' according to their origin on the cranium.

We have used names related to those given to the muscles by Glockauer (1915) as far as possible. He recognized the four powerful muscles and two thin sheets. His descriptions of them are brief and the figures are not very clear. The comparison between his names and ours is

TABLE 1. THE SEVEN EXTRAOCULAR EYE MUSCLES OF *OCTOPUS VULGARIS* AND THE NERVES BY WHICH THEY ARE INNERVATED

(For comparison, the names used by Glockauer (1915) are given on the right.)

muscles	nerves	names of muscles used by Glockauer (1915)
m.rect.ant.mai.	n.oc.ant.	m.inf.
m.rect.ant.min.		(m.ant.I of Decapods)
m.rect.sup.	n.oph.sup.ant. n.oph.sup.med.	m.sup. (Schalenmuskel)
m.rect.post.	n.oc.post.	m.post.II
m.obl.sup.ant.	n.oph.sup.med. n.oph.sup.post.rad.ant. n.oph.sup.post.rad.post.	m.sup. (Schalenmuskel)
m.obl.sup.post.	n.oph.sup.ant. n.oph.sup.med.	mentioned, but unnamed
m.obl.inf.ant.	n.oc.ant.	(m.inf.II of Decapods)
m.obl.inf.post.	n.oph.inf.	(m.inf.I of Decapods)

shown in table 1. His names are largely derived from his more thorough study of the more complex arrangement of the muscles of decapods.

3.1.1. *Recti muscles*

M. rectus anterior. This muscle may be considered to have two parts. M. rectus anterior major is a thick muscle arising from a narrow base at the antero-ventral cranial arch (figures 2–4 and 8). It ends at a sharp border ventrally, but dorsally continues as m. rectus anterior minor. This is a thinner sheet of fibres running upwards and backwards for insertion along the upper surface of the eyeball, inside m. rectus superior as far back as the anterior border of m. rectus posterior (figure 4). The whole muscle is innervated by fibres of n. oculomotorius anterior.

M. rectus superior. This is a powerful muscle arising from a narrow attachment to the anterior cranial arch and inserted round the upper anterior part of the eyeball (figures 1, 3, 4 and 8). Posteriorly the muscle is continuous with m. obliquus superior anterior. The muscle is innervated by n. ophthalmicus superior anterior and n. ophthalmicus superior medius.

M. rectus posterior. This powerful muscle originates from the cartilaginous arch at the posterior edge of the orbit. Its fibres run outwards for insertion all round the postero-dorsal surface of the eyeball (figures 2–4 and 8). The most ventral fibres run somewhat obliquely (figure 4). The muscle is innervated by n. oculomotorius posterior.

3.1.2. *Superior oblique muscles*

The two superior oblique muscles consist of thin sheets of very long fibres.

M. obliquus superior anterior. The fibres of this muscle arise from an attachment to the anterior arch of the cranium with those of m. rectus superior and along the dorsal orbital cartilage; the muscle is thus a continuation of m. rectus superior (figures 1, 4 and 8). Its fibres pass back to be inserted along the upper and back side of the eyeball inside those of m. rectus posterior (figure 1). These fibres extend round to the mid-ventral surface overlapping those of m. obliquus inferior anterior. They are innervated by n. ophthalmicus superior medius and n. ophthalmicus superior posterior radix anterior and posterior.

M. obliquus superior posterior. The fibres of this muscle arise near the front of m. rectus posterior and along the dorsal orbital cartilage (figures 1, 3, 4 and 8). They run forwards across the upper surface of the eyeball outside m. rectus superior (figure 1) and spread out to be inserted along the anterior surface of the eyeball, continuing right round to the ventral surface. They are innervated by n. ophthalmicus superior anterior and n. ophthalmicus superior medius.

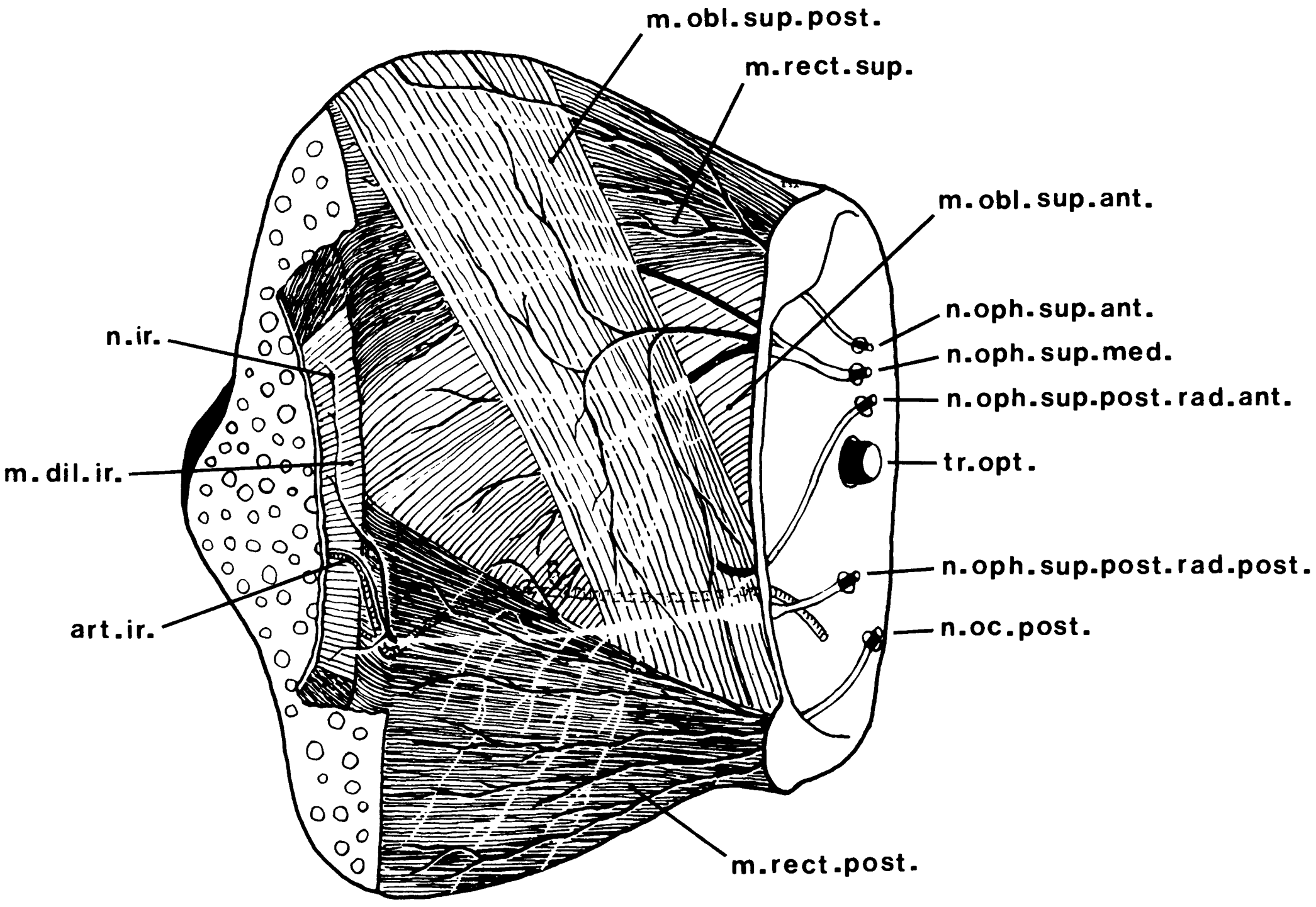

Figure 1. The arrangement of the extraocular eye muscles of the dorsal part of the left eye of *Octopus vulgaris*. The course of the nerves within the muscles are shown diagrammatically in this and the following figures. The nerves are shown in white when passing underneath the outermost muscle layers.

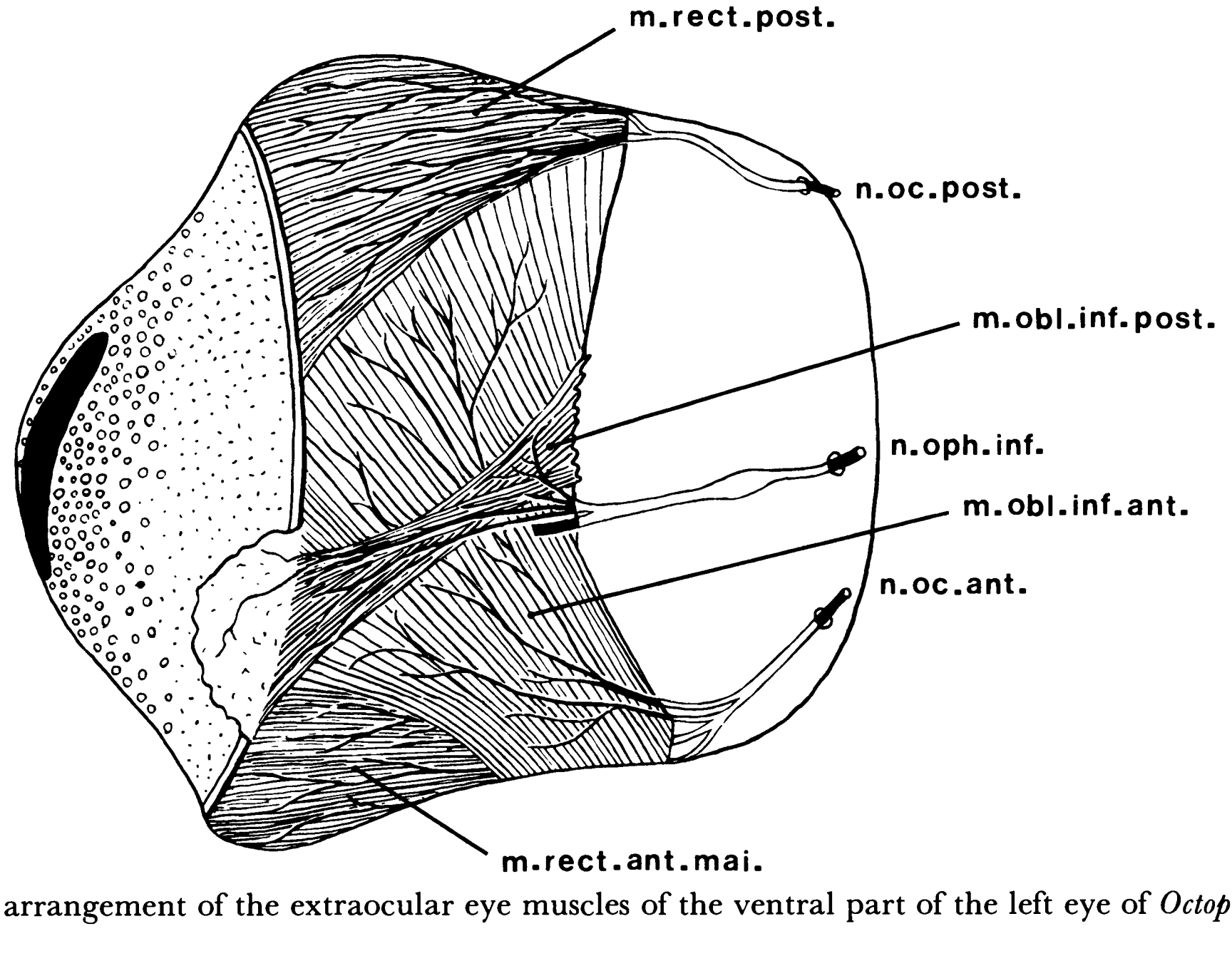

Figure 2. The arrangement of the extraocular eye muscles of the ventral part of the left eye of *Octopus vulgaris*.

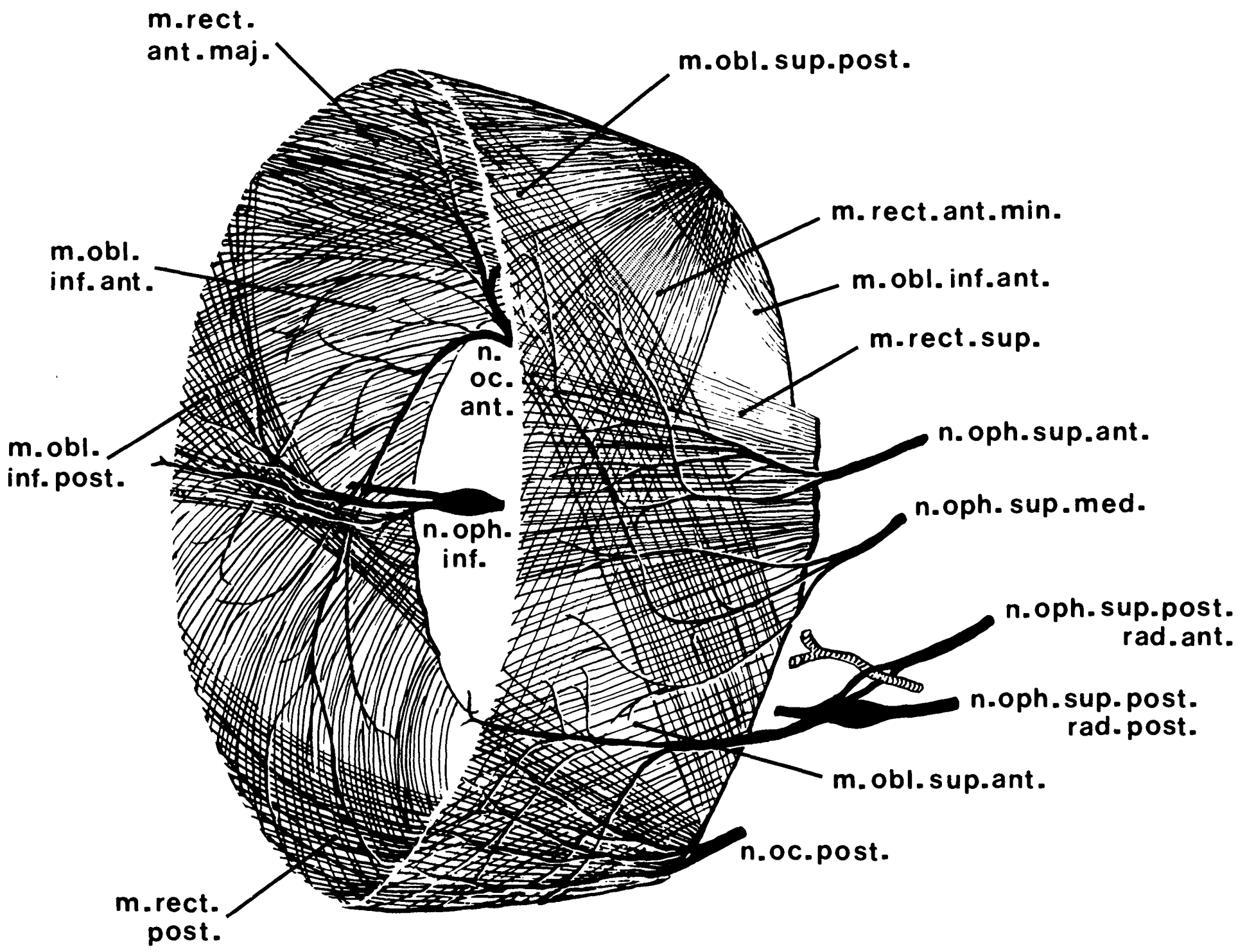

FIGURE 3. The ring of extraocular eye muscles of the left eye of *Octopus vulgaris* after removal from the eye and cartilaginous cranium.

3.1.3. *Inferior oblique muscles*

The two inferior oblique muscles are very different from each other. The posterior inferior oblique is the narrowest of all the eye muscles, while the anterior is a broad, extremely long, thin sheet (figures 4, 8 and 12).

M. obliquus inferior anterior. This muscle extends more than half-way round the ventral side of the eyeball, from in front of m. rectus anterior to the middle of m. rectus posterior (figures 3 and 4). It is a sheet only one or two fibres thick. The fibres arise with those of m. rectus anterior along the lower border of the orbit. They insert along the whole ventral surface of the eyeball, overlapping the insertions of m. obliquus inferior posterior, m. obliquus superior anterior and m. rectus posterior. The fibres run outside those of m. rectus anterior, but inside those of m. obliquus inferior and m. rectus posterior (figure 2). The muscle is innervated by a large posterior branch of n. oculomotorius anterior.

M. obliquus inferior posterior. This muscle consists of two sets of fibres which cross and thus have slightly different directions giving the muscle an unusual shape, with a narrow waist (figures 2–4 and 8–12). The origin of the muscle is over a short length of the cartilage of the floor of the orbit above the statocyst. In all the other eye muscles the fibres diverge from the origin, but in this one there are two sets which come together and cross (figures 9–11). They then diverge to be inserted along the lower anterior surface of the eyeball, slightly overlapping m. rectus anterior (figure 4). The fibres that arise more anteriorly thus run almost directly outwards but a little forwards. The fibres with a more posterior origin run more obliquely forwards. The muscle is innervated by n. ophthalmicus inferior.

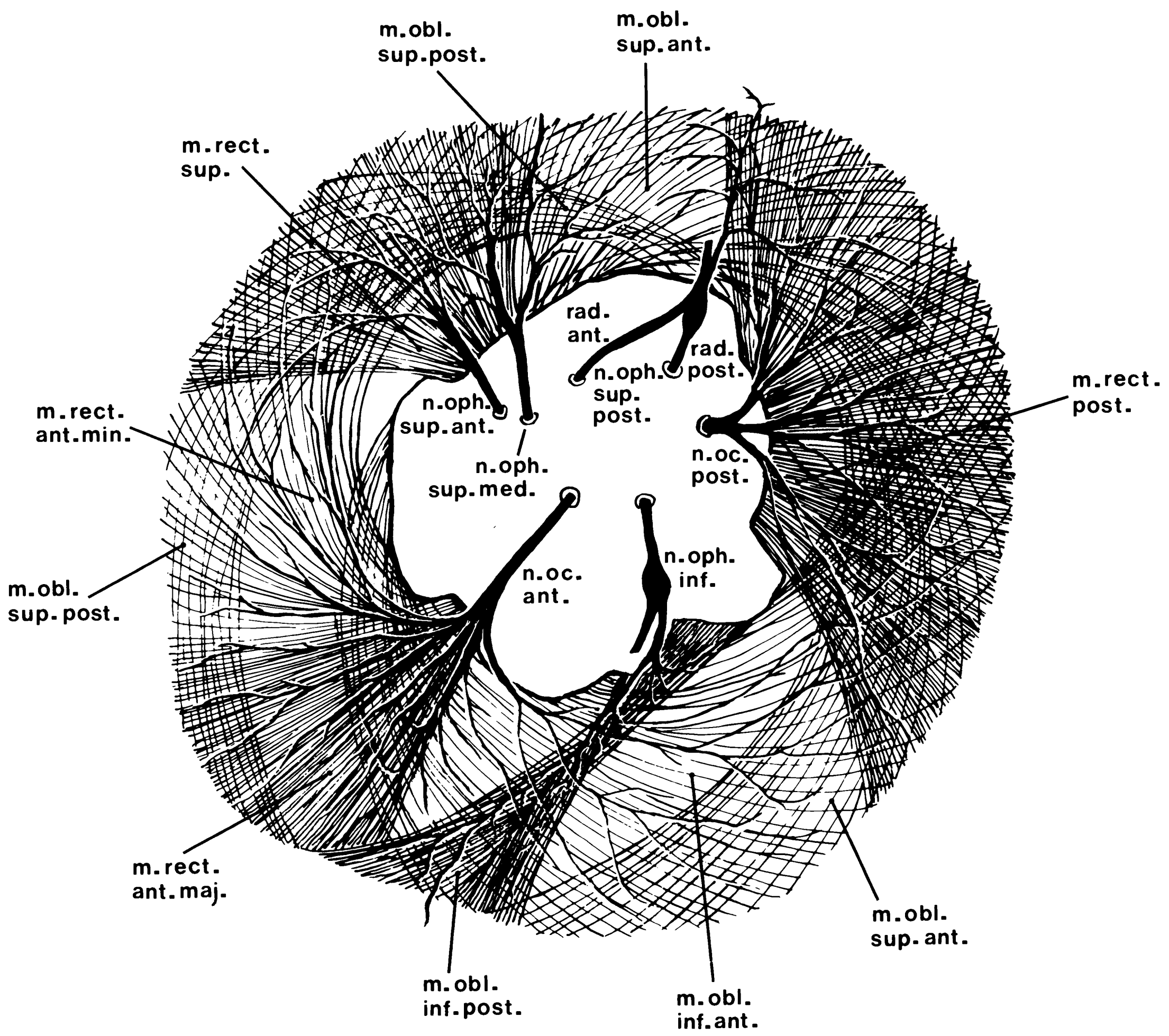

FIGURE 4. The ring of extraocular eye muscles of the left eye of *Octopus vulgaris* seen laterally as a flattened preparation. It shows especially the oblique muscles running for long distances around the eyeball.

3.2. *Nerves to the eye muscles*

There are seven nerves concerned with the extraocular eye muscles (table 2), some of them are also concerned with constriction and dilation of the pupil, perhaps with accommodation, and certainly with the chromatophores of the iris and the skin around the eye. The nerves believed to run only to eye muscles have therefore been called 'oculomotor', the others 'ophthalmic', but without experimental evidence, so that there is confusion among the authors. We have kept strictly to the names used in Young (1971; see tables 1 and 2). Each of the seven nerves has a root arising in the anterior lateral pedal lobe, which is therefore certainly an oculomotor centre.

The numbers and sizes of the fibres in these nerves were counted by Young (1965). In that study the roots of the nerves running to the eye muscles were estimated to contain about 5840 fibres greater than 2 μm, some over 20 μm. In a new count made with material fixed for electron microscopy there were 3136 fibres greater than 2 μm, the largest 16 μm (T. Plän & B. U. Budelmann, unpublished observations). This new count did not show the bimodal distribution of fibre sizes seen by Young (1965) in some nerves to the extraocular eye muscles.

Examples of the pattern of branching and distribution of the nerve fibres in the muscles are seen in figures 13 and 14. Cobalt filling sometimes continues even to the finest fibres, as seen in figures 18–20, plate 2. The varicosities seen in these figures are probably close to the synaptic contacts of the nerve fibres to the muscle cells. Figure 21 shows similar varicosities in a Bielschowsky preparation in nerve fibres in contact with fibres of the posterior rectus muscle.

TABLE 2. THE SEVEN NERVES THAT CONTAIN FIBRES FOR THE EXTRAOCULAR EYE MUSCLES OF *OCTOPUS VULGARIS*, THE MUSCLES THAT THEY INNERVATE AND THE MOVEMENTS THAT ARE PRODUCED BY STIMULATING THE NERVES

nerves	muscles	main eye movements on stimulation of the nerves (referred to the left eye)
n.oc.ant.	m.rect.ant. m.obl.inf.ant.	forwards–downwards rotation either way
n.oc.post.	m.rect.post.	backwards–upwards no rotation
n.oph.sup.ant.	m.rect.sup. m.obl.sup.post.	forwards–upwards clockwise rotation
n.oph.sup.med.	m.rect.sup. m.obl.sup.ant. m.obl.sup.post.	forwards–upwards rotation either way
n.oph.sup.post.rad.ant.	m.obl.sup.ant.	forwards–upwards anticlockwise rotation
n.oph.sup.post.rad.post.	m.obl.sup.ant.	forwards–upwards anticlockwise rotation
n.oph.inf.	m.obl.inf.post.	forwards–downwards anticlockwise rotation

N. oculomotorius anterior

This nerve has a complicated fibre composition with a wide distribution of fibre diameters. The function of the various components is not well known. The oculomotor component of large fibres runs to m. rectus anterior, and gives a large backward branch to m. obliquus inferior anterior (figures 2–4 and 17, table 2). In addition the nerve contains a bundle of medium sized fibres and two bundles of very small ones. Some of these arise in the anterior chromatophore lobe (see §3.4.1.).

N. oculomotorius posterior

This is a pure eye muscle nerve, arising in the anterior lateral pedal lobe and running to the large m. rectus posterior (figures 1–4 and 25, table 2). It has the simple composition of an eye muscle nerve, with 707 fibres nearly all larger than 0.5 μm (T. Plän & B. U. Budelmann, unpublished observations).

N. ophthalmicus superior anterior

This is also a pure oculomotor nerve, arising in the anterior lateral pedal lobe, with 391 fibres nearly all above 0.5 μm (T. Plän & B. U. Budelmann, unpublished observations). It sends fibres to both m. rectus superior and m. obliquus superior posterior (figures 1, 3, 4 and 15, table 2).

N. ophthalmicus superior medius

This nerve leaves the anterior lateral pedal lobe together with n. ophthalmicus superior anterior in a single trunk, but then separates. It is complex and has fibres with various destinations. It has large fibres and also many less than 0.5 µm in diameter. It gives branches to m. rectus superior and m. obliquus superior posterior and a large posterior branch to the front part of m. obliquus superior anterior (figures 1, 3, 4 and 24, table 2). In addition the nerve has presumably another branch passing to the iris, since it dilates this and when stimulated causes expansion of its chromatophores (see §3.3.), but we have not seen cobalt fillings of this branch.

N. ophthalmicus superior posterior radix anterior

This nerve arises far forward close to the anterior chromatophore lobe, from which most of its fibres originate. It contains 352 fibres greater than 2 µm and about 3150 smaller ones (T. Plän & B. U. Budelmann, unpublished observations). It has previously been wrongly assumed to be a pure chromatophore nerve (Young 1965). Its fibres join n. ophthalmicus superior posterior radix posterior beyond its ganglion for a short distance, and then it sends a branch that joins with part of the posterior root of the nerve and innervates the skin of the back of the head (figures 1, 3 and 4). In the course of this present work it has been shown both by centripetal cobalt filling (see §3.4.5.) and stimulation (see §3.3.) that this is not a pure chromatophore nerve but contains some fibres that arise in the anterior lateral pedal lobe and innervate m. obliquus superior anterior (table 2). Dissection confirms that a few large fibres from this root run together with fibres of n. ophthalmicus superior posterior radix posterior to that muscle. However, we have not been able to stain these fibres in centrifugal cobalt fillings.

N. ophthalmicus superior posterior radix posterior

This is the most complicated of all the nerves and carries a ganglion (figures 1, 3, 4 and 16). The nerve arises from three sources in the brain (see §3.4.6.). One part arises from the base of the median basal lobe and is presumed to be sensory. It probably contains the numerous very small fibres found in the nerve. They run past the ganglion and leave the orbit to innervate the skin of the papilla behind the eye. A second part arises from a region between the ventral magnocellular and posterior pedal lobes and contains 280 fibres of 5–10 µm (Young 1965), which probably end in the ganglion and serve to constrict the pupil. The postganglionic fibres run in a nerve that continues beyond the equatorial ring and passes round forwards giving branches to the tissue of the iris (figure 77, plate 8). The third part of this root arises in the anterior lateral pedal lobe. Its numerous large fibres run past the ganglion and innervate the hinder part of m. obliquus superior anterior (figures 1, 3 and 4, table 2).

N. ophthalmicus inferior

This nerve, like n. ophthalmicus superior posterior radix posterior, carries a ganglion (figures 2–4). It has two main roots. The more dorsal root contains three bundles: (i) an oculomotor bundle of large fibres runs past the ganglion to m. obliquus inferior posterior (figure 22, table 2); (ii) a bundle of medium sized fibres was presumed to innervate chromatophores (Young 1965) but in the present experiments no colour changes in the iris have been seen when the nerve was stimulated (see §3.3.); and (iii) a bundle of very fine fibres is presumed to be sensory. The more ventral root of this nerve contains medium sized and small fibres arising from an area between the ventral magnocellular and posterior pedal lobes (see §3.4.7.) and is presumed to end in the ganglion and serve to constrict the pupil. The fibres arising from the cells of the ganglion have been seen in a preparation where the nerve was filled with cobalt peripherally to the ganglion. This showed two branches proceeding beyond the end of the muscle towards the iris (figure 23).

3.3. *Stimulation of the eye muscle nerves*

In all experiments, stimulation of the various eye muscle nerves caused movements only of the ipsilateral eye. All experiments are reported as if the left eye were facing the observer during stimulation. That is to say the direction of the movements of the right eye were translated into those of a supposed left eye. All data are summarized in table 3.

TABLE 3. RESULTS OF STIMULATING THE NERVES TO THE EYE MUSCLES OF *OCTOPUS VULGARIS*

(Both eyes were investigated in seven animals but the results from the right eye (R^+) are presented as if from the left eye (L). Arrows indicate the direction of movement referred to a clockface seen from the left. Unfilled arrowheads indicate weak movement, filled arrowheads indicate strong movement. Key: expan. indicates expansion of the chromatophores of the iris, narrow and dilat. refer to movements (constriction, dilation) of the pupil. For each experiment the symbol in the upper line shows rotatory eye movements. The arrow in the second line shows linear eye movements. The words in the lower lines show where other actions were observed. Empty spaces indicate that there were no movement of the eye, pupil or chromatophores of the iris in that experiment. Shaded spaces indicate no stimulation experiments with that nerve.)

	0 257		0 258		0 259		0 262		0 266		0 270		0 276	
	L	R^+	L	R^+	L	R^+	L	R^+	L	R^+	L	R^+	L	R^+
n.oc.ant.	↺ ↙	↙	↙	↺ ↙	↙	↙	↻ ↙	↙	↖	↙	↙	↙	↻ ↙	↺ ↙
n.oc.post.	▨	→	↻ ↗	↻ ↗	↗	↗	↘	↻ ↘	↗	↗	↗	↗	↗	↗
n.oph.sup.ant.	↻ ↖	↻ ↖	↺	↻ ↖	↖	↻ ↖	▨	↻ ↖	▨	↻ ↖	▨	▨	↻ ↖	↻ ↖
n.oph.sup.med.	↻ ↖ expan.	↖	↖ expan. dilat.	↺ ↖ expan.	▨	↺ ↖ expan. dilat.	↻ ↑ expan. dilat.	↺ ↑ expan.	▨	↺ ↖ expan. dilat.	↑ expan.	▨	↖ expan.	↖ expan.
n.oph.sup.post.$^{\text{rad.}}_{\text{ant.}}$	▨	▨	▨	▨	↺ ↖ expan.	↺ ↖ expan.	↺ ↖ expan.	↺ ↖	↺ ↖	↺ ↖	↺ ↖	↺ ↖ expan.	↺ ↖ expan.	↺ ↖
n.oph.sup.post.$^{\text{rad.}}_{\text{post.}}$	↺ ↖ narrow	▨	↺ narrow	↖	↺ narrow	↺ narrow	↺ ↖ narrow	↺ ↖ narrow	↺ ↖ narrow	↺ ↖ narrow	▨	▨	↺ ↖ narrow	↺ ↖ narrow
n.oph.inf.	↺ ↙ narrow	↺ ↙ narrow	↺ narrow	↺ ↙ narrow	↺ ↙ narrow	↺ ↙ narrow	▨	↙	↺	↺ ↙ narrow	↺ ↙ narrow	↺ ↓	↺ ↓ narrow	↺ ↓

N. oculomotorius anterior

In 13 out of 14 experiments stimulation consistently produced an eye movement forwards–downwards in a direction of 7–8 o'clock (referred to a clock face seen from the left). In one experiment a small movement was to be seen forwards–upwards to 10 o'clock. In two experiments there was a clockwise and in three a slightly anticlockwise rotation; in the remaining nine experiments no signs of rotation were observed. From the anatomy, the strong m. rectus anterior major would be expected to move the eye forwards–downwards (figure 5). The thinner dorsal bundles of m. rectus anterior minor run obliquely and would be expected to give some anticlockwise rotation (figure 5). Conversely, m. obliquus inferior anterior, which is also innervated by n. oculomotorius anterior, would rotate the eye clockwise (figure 5). This situation presumably explains the ambiguous rotations during stimulation.

N. oculomotorius posterior

In 11 of 13 experiments stimulation produced a marked movement of the eye backwards–upwards in the direction of 2–3 o'clock; in two experiments the movement was backwards with a slight component downwards to 4 o'clock. In three experiments a weak clockwise rotation was observed. From the anatomy, m. rectus posterior would be expected to produce the movements reported (figure 5). No marked rotations would be expected since most of the fibres of this muscle run straight. A very few are oblique at the most dorsal part of the muscle and these are the probable source of the weak clockwise rotation.

N. ophthalmicus superior anterior

In nine out of ten experiments stimulation caused a movement of the eye forwards–upwards in a direction of 10–11 o'clock. Additionally in eight experiments a clockwise rotation was observed, in one an anticlockwise rotation, and in one no rotation at all. From the anatomy, m. rectus superior would be expected to produce the forwards–upwards movement that has been observed (figure 5). M. obliquus superior posterior, innervated by this nerve would cause the clockwise rotation. The most dorsal fibres of m. obliquus superior anterior, also innervated by the nerve, may have produced the anticlockwise rotation seen in the one experiment (figure 5).

N. ophthalmicus superior medialis

The results with stimulation of this nerve were variable and this is not surprising since it innervates two muscles with opposite actions. In all 11 experiments the eye was moved forwards–upwards in a direction of 10–12 o'clock. Additionally, a rotation was observed in an anticlockwise direction in four experiments, and a weak clockwise rotation in two experiments; in the remaining five experiments no rotation was seen in either direction. From the anatomy, fibres of m. rectus superior and those of m. obliquus superior anterior that are close to m. rectus superior should produce the forwards–upwards movement of the eye. The very oblique fibres of the latter muscle should produce the anticlockwise rotation, whereas the clockwise rotation should be caused by m. obliquus superior posterior (figure 5). Stimulation of n. ophthalmicus superior medialis also produced a dilation of the pupil in four of 11 experiments, and in eight of the experiments an expansion of the chromatophores of the iris was observed.

N. ophthalmicus superior posterior radix anterior

This nerve has been supposed to contain fibres only for the chromatophores of the skin of the head (Young 1965) and of the iris (Froesch 1973). However, in all ten experiments stimulation of the nerve produced a forwards–upwards movement to about 11 o'clock, and additionally anticlockwise rotation. Besides the eye movements an expansion of the chromatophores of the iris was observed in five experiments. This nerve has now been shown to contain some fibres that arise in the anterior lateral pedal lobe (see §3.4.5.) and joins the radix posterior which innervates m. obliquus superior anterior. These fibres would produce a forwards–upwards movement and anticlockwise rotation (figure 5).

N. ophthalmicus superior posterior radix posterior

In eight of 11 experiments stimulation of this nerve produced a movement forwards–upwards in a direction of about 11 o'clock, whereas in three of the experiments no linear movement was observed. In 10 experiments an anticlockwise rotation was seen, whereas no rotation was observed in one experiment. From the anatomy, m. obliquus superior anterior innervated by this nerve should produce an anticlockwise rotation (figure 5) and should also be able to cause the forwards–upwards movement of the eye. Stimulation of the nerve also produced a narrowing of the pupil in ten of the 11 experiments.

N. ophthalmicus inferior

In 11 of 13 experiments stimulation of this nerve produced a movement forwards–downwards in a direction of 7–8 o'clock; in the remaining two experiments no linear movement was observed. In 12 experiments an anticlockwise rotation of the eye also occurred. In the remaining one experiment there was no rotation. From the anatomy, m. obliquus inferior posterior should produce the forwards–downwards movement (figure 5) and it should also be able to cause the anticlockwise rotation described. In nine of the 13 experiments the pupil slit became narrow during stimulation of the nerve.

3.4. *Projections of the eye muscle nerves in the central nervous system*

By centripetal cobalt filling both the origin of the efferent nerve fibres, that is, the location of the somata of the eye muscle motoneurons, and the course and destination of the afferent fibres, which are present in some of the nerves, were analysed.

All seven eye muscle nerves originate, at least partly, in the anterior lateral pedal lobe of the same side in the middle suboesophageal mass of the brain (figures 26, 29, 32, 35, 43, 46 and 49, plates 3–5). The stained somata have different distributions within the lobe. They vary in number and in diameter from about 10 to 90 μm. In the following text they will be called according to their diameter: small (10–20 μm), medium (20–40 μm), large (40–60 μm) and very large (60–90 μm). Medium and large somata were found mainly in the middle and outer perikaryal layers, whereas smaller somata were found in the inner ones.

Three of the eye muscle nerves (n. oculomotorius anterior, n. ophthalmicus superior medius, and n. ophthalmicus superior posterior radix anterior) additionally carry fibres whose somata lie in the ipsilateral anterior chromatophore lobe (figures 26, 32, plate 3 and 43, plate 5). The two nerves that carry ganglia (n. ophthalmicus superior posterior radix posterior, n. ophthalmicus inferior) have even more complex projections. They carry some efferent fibres that presumably end in the ganglia. These come from an area between the ipsilateral ventral magnocellular and posterior pedal lobes. These two nerves also contain some afferent fibres that reach to various parts of the supra- and suboesophageal lobes of the brain, both ipsi- and contralaterally. We found no evidence of cobalt filling of afferent fibres in any of the other five nerves.

3.4.1. *N. oculomotorius anterior (figures 26–28)*

Somata of the efferent fibres of n.oc.ant. were stained in two areas of the brain: in the anterior chromatophore lobe and in the anterior lateral pedal lobe. In the latter they are very numerous and arranged in an approximately triangular area as seen laterally, curved outwards both anteriorly and posteriorly, and slightly tapered ventrally (figure 26). A line almost free of cells indicates the boundary between the anterior chromatophore and the anterior lateral pedal lobes (figure 27).

In the anterior chromatophore lobe, medium sized somata were found predominantly in the outer half of the perikaryal layers, whereas small somata occur in the inner layer, close to the neuropil. In the anterior lateral pedal lobe, small, medium and large somata are scattered all

DESCRIPTION OF PLATE 1

FIGURE 8. Preparation of the ring of extraocular eye muscles opened out, after staining with haemalum. The posterior rectus muscle has been turned out to show the course of the oblique muscles.

FIGURES 9 AND 10. The posterior inferior oblique muscle seen in polarized light at two different filter positions (20° change).

FIGURE 11. The crossing fibres of the posterior inferior oblique muscle seen in polarized light.

FIGURE 12. The two inferior oblique muscles showing their different forms. The anterior muscle is a very thin sheet, the posterior muscle is thick with crossing fibres. Haemalum stain.

FIGURES 13 AND 14. Parts of the posterior oculomotor nerve showing the large fibres branching in the muscle. The finer branches run for long distances parallel to the muscle fibres. Bielschowsky stain.

DESCRIPTION OF PLATE 2

FIGURE 15. Fibres of the anterior superior ophthalmic nerve. Centrifugal cobalt filling.

FIGURE 16. Fibres of the posterior root of the posterior superior ophthalmic nerve passing to the anterior superior oblique muscle. Centrifugal cobalt filling.

FIGURE 17. Distribution of branches of the anterior oculomotor nerve to the anterior rectus muscle, with a large branch (to the right) to the anterior inferior oblique muscle. Centrifugal cobalt filling.

FIGURES 18–20. Details of stained branches of fibres of the inferior ophthalmic nerve. In this preparation even very fine fibres were filled, perhaps to their synaptic sites. Centrifugal cobalt filling.

FIGURE 21. Varicosities of nerve fibres of the posterior oculomotor nerve, seen in contact with muscle cells of the posterior rectus muscle. Bielschowsky stain.

FIGURE 22. Fibres of the inferior ophthalmic nerve passing to both parts of the posterior inferior oblique muscle. Centrifugal cobalt filling.

FIGURE 23. Nerve fibres (arrow) proceeding to the iris from the outer end of the inferior ophthalmic nerve where they leave the posterior inferior oblique muscle. Centrifugal cobalt filling.

FIGURE 24. Branching pattern of fibres of the medial superior ophthalmic nerve. Centrifugal cobalt filling.

FIGURE 25. Distribution of branches of the posterior oculomotor nerve to the posterior rectus muscle. Centrifugal cobalt filling.

DESCRIPTION OF PLATE 3

FIGURES 26–28. Centripetal cobalt filling of the anterior oculomotor nerve showing somata in the anterior lateral pedal lobe and in the anterior chromatophore lobe. Lateral view of the brain (figures 26 and 27) and transverse section of the anterior lateral pedal lobe (figure 28).

FIGURES 29–31. Centripetal cobalt filling of the anterior superior ophthalmic nerve showing somata in the anterior lateral pedal lobe. Lateral view of the brain (figures 29 and 30) and transverse section of the anterior lateral pedal lobe (figure 31).

FIGURES 32–34. Centripetal cobalt filling of the medial superior ophthalmic nerve showing somata in the anterior lateral pedal lobe and anterior chromatophore lobe. Lateral view of the brain (figures 32 and 33) and transverse section of the anterior lateral pedal lobe (figure 34) showing fine collaterals running parallel to the perikaryal layer.

DESCRIPTION OF PLATE 4

FIGURES 35 AND 36. Lateral (figure 35) and dorso-lateral (figure 36) views of the same brain after centripetal cobalt filling of the posterior root of the posterior superior ophthalmic nerve showing somata in the anterior lateral pedal lobe and in the region between the posterior pedal and magnocellular lobes. Filling of fibres in other regions appear as shadows. Figure 36 shows that the somata in the anterior lateral pedal lobe extend some way medially (compare figure 39).

FIGURE 37. Oblique view from behind of the preparation of figure 35 showing somata in the more dorsal region between the posterior pedal and magnocellular lobes.

FIGURE 38. Lateral view of the brain in figure 35. Somata in the anterior lateral pedal lobe and in the region between the posterior pedal and magnocellular lobes, ventrally, dorsally and inbetween (the latter two sets are out of focus and indicated by stars). Fibres are also filled in the neuropil of these lobes and in the median basal lobe.

FIGURE 39. Somata in the anterior lateral pedal lobe. Transverse section of the preparation of figure 35.

FIGURES 40 AND 41. Somata in the dorsal (figure 40) and ventral region (figure 41) between the posterior pedal and magnocellular lobes. In figure 40 fibres are seen proceeding to the median basal lobe and suprapedal commissure. Transverse section of the preparation of figure 35.

FIGURE 42. Somata in the ventral and some between the ventral and dorsal sets in the region between the posterior pedal and ventral magnocellular lobes. Transverse section of the preparation of figure 35.

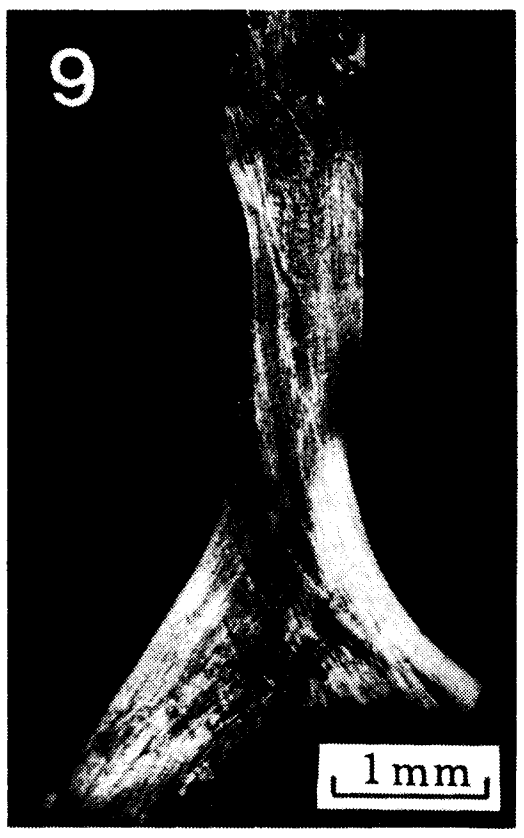

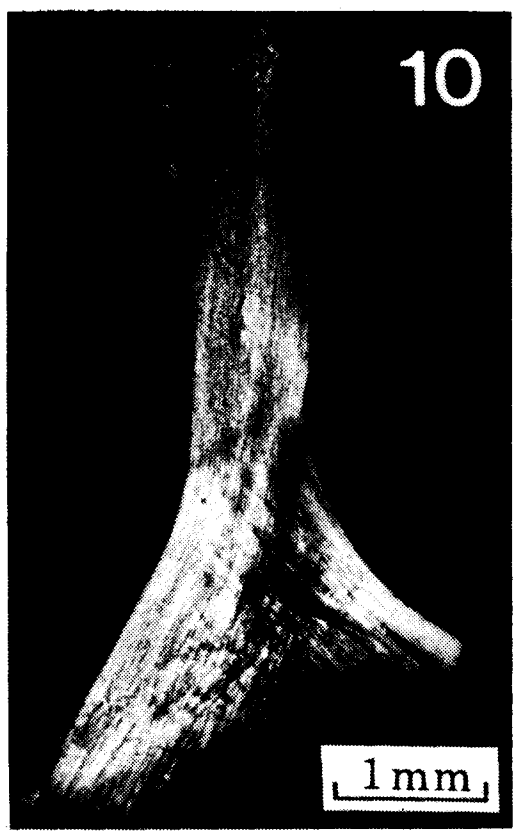



FIGURES 8–14. For description see opposite.

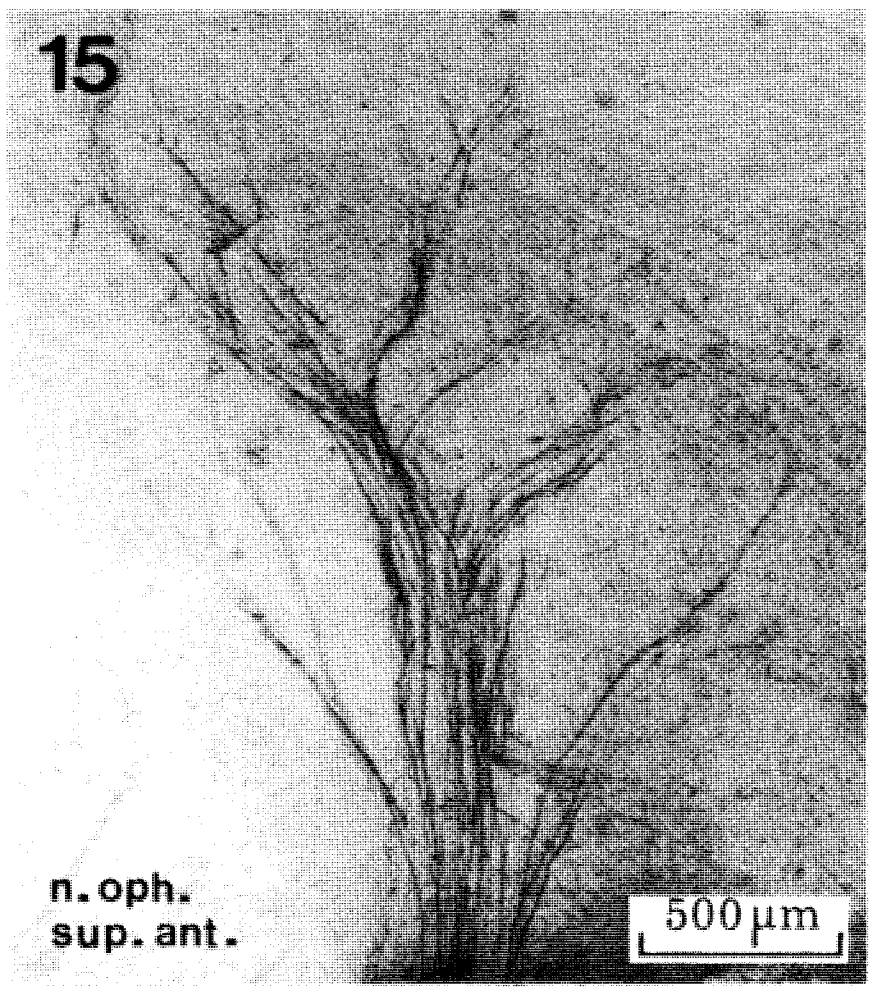

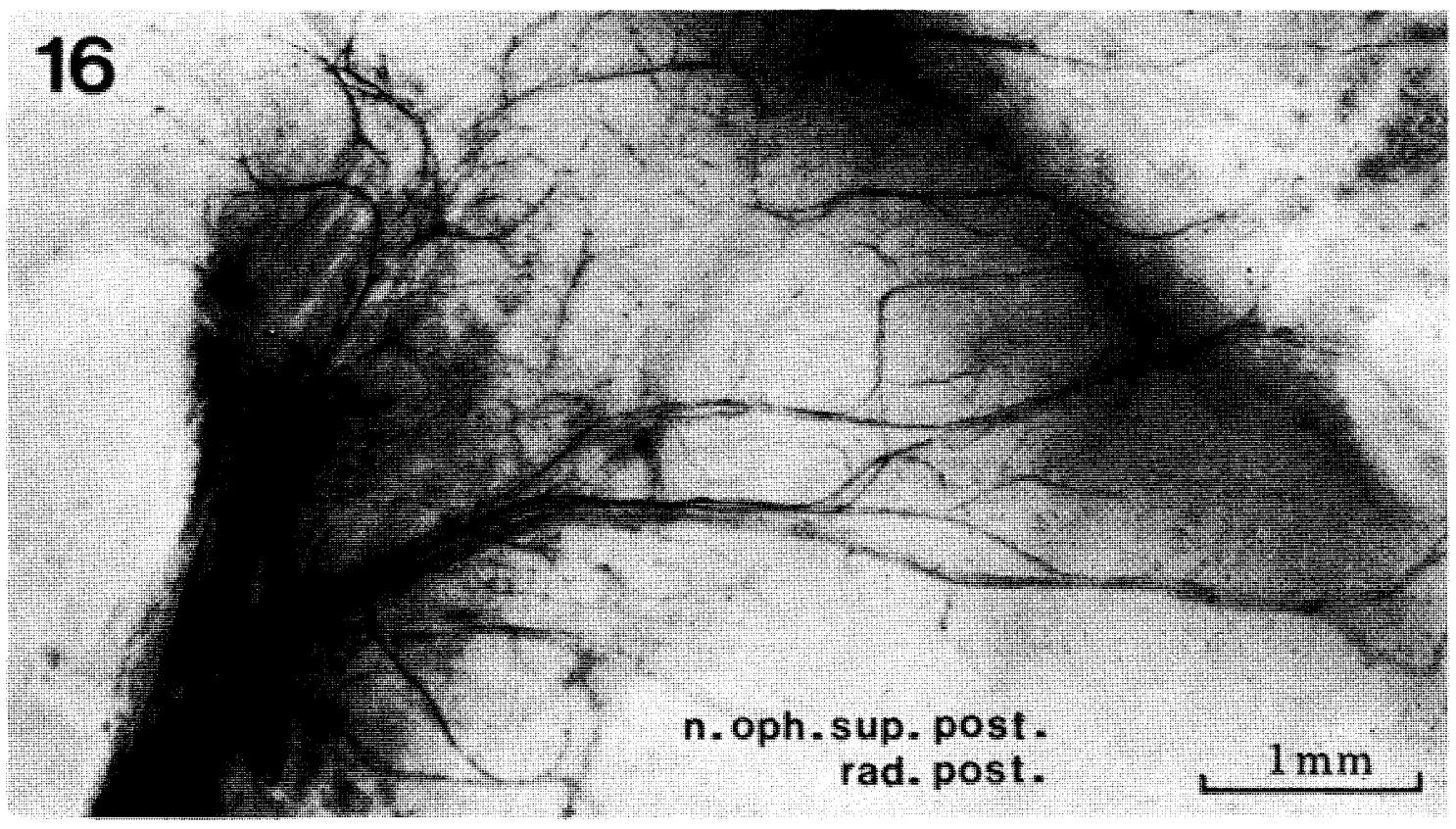

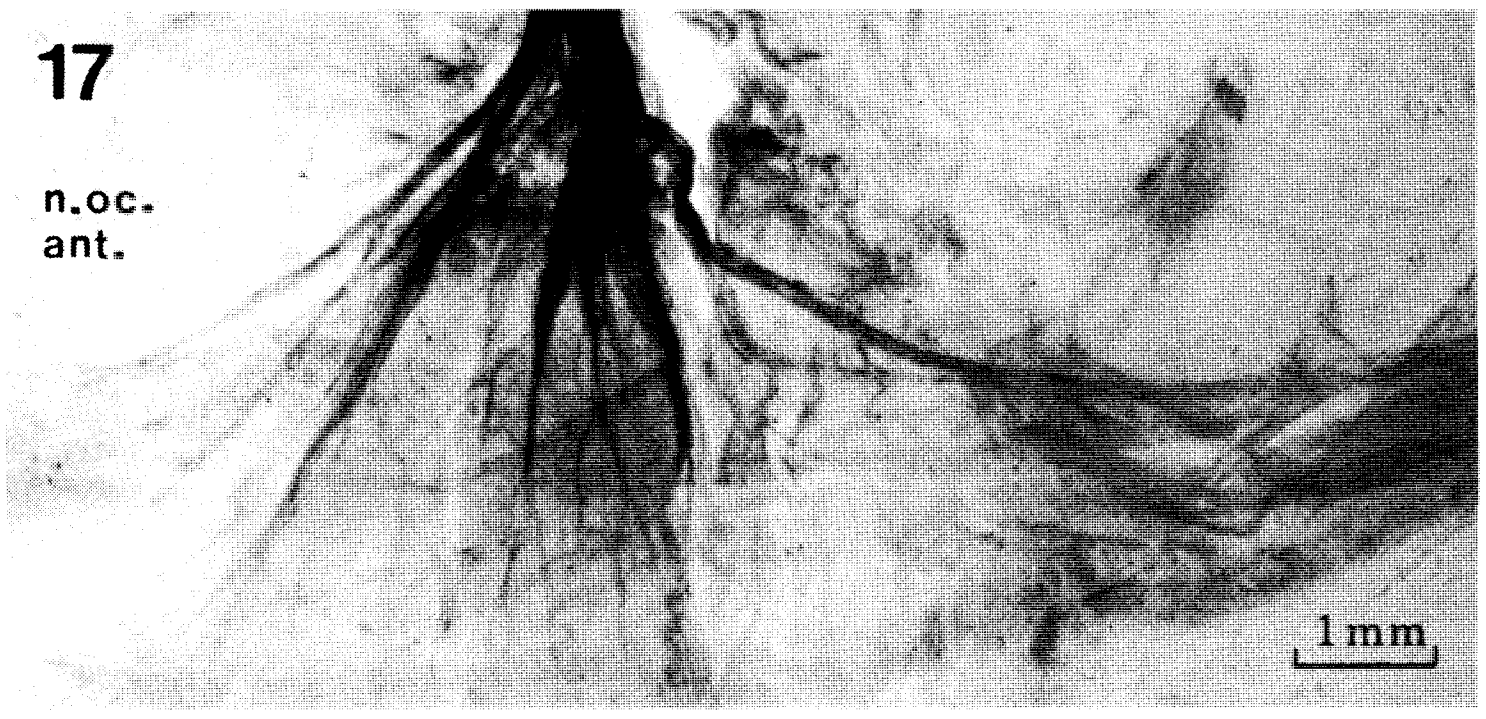

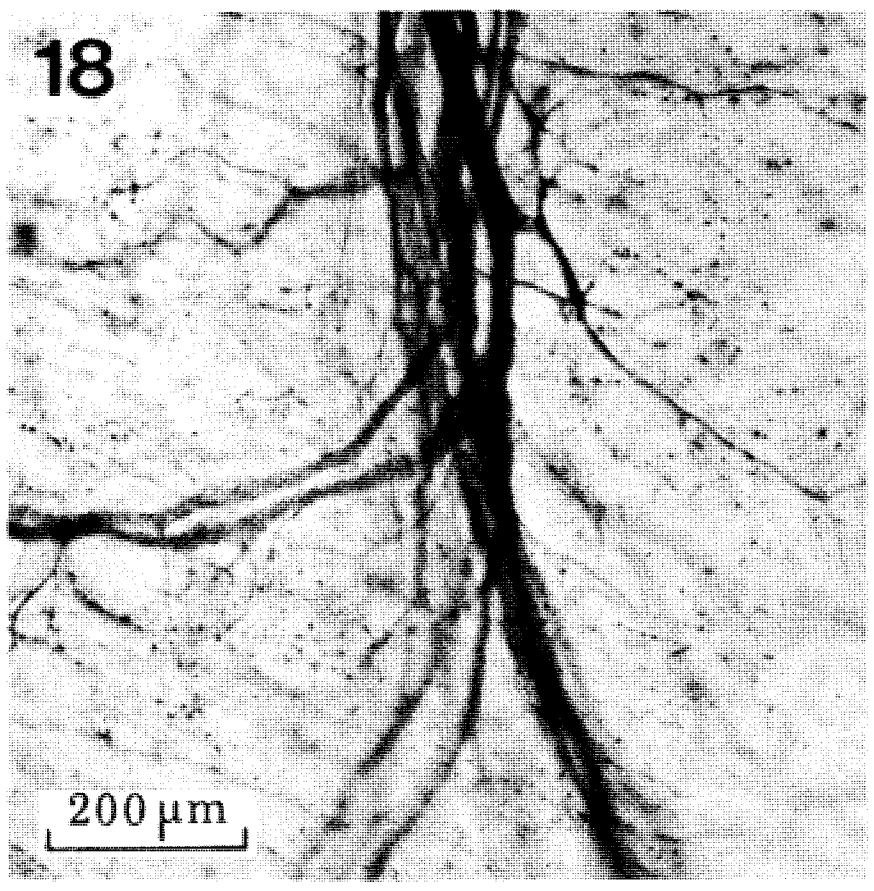

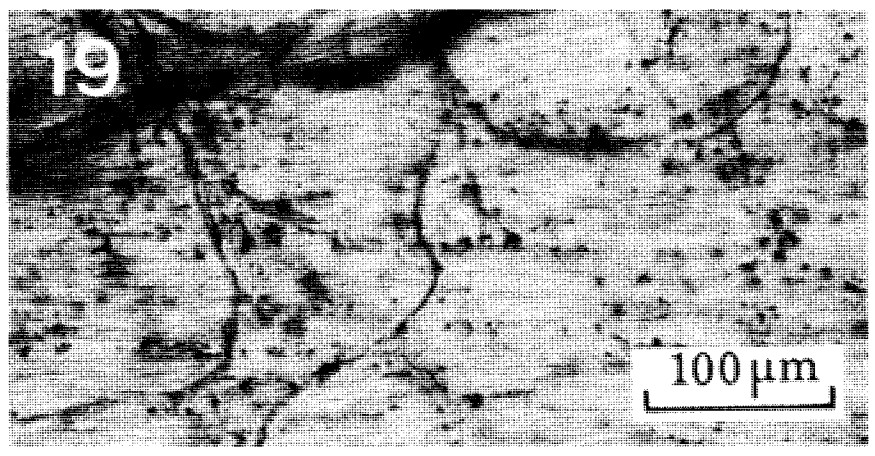

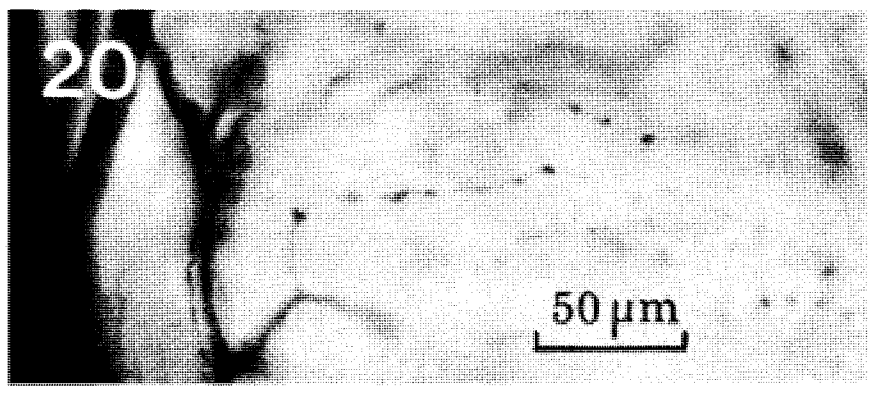

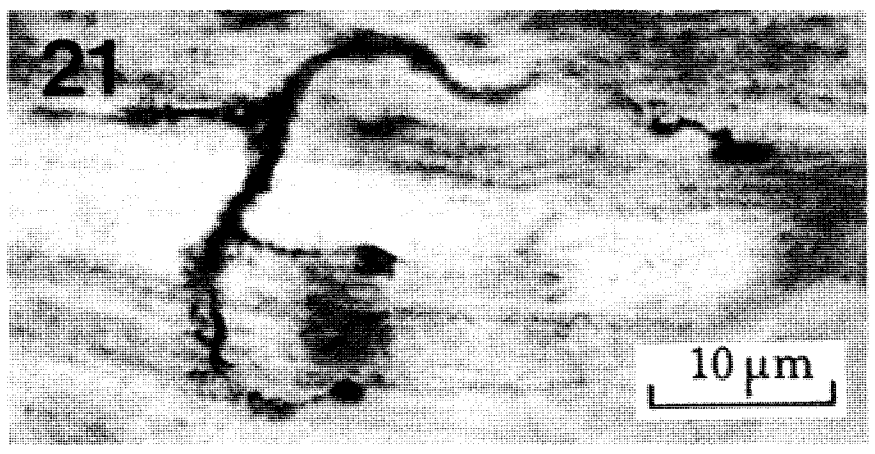

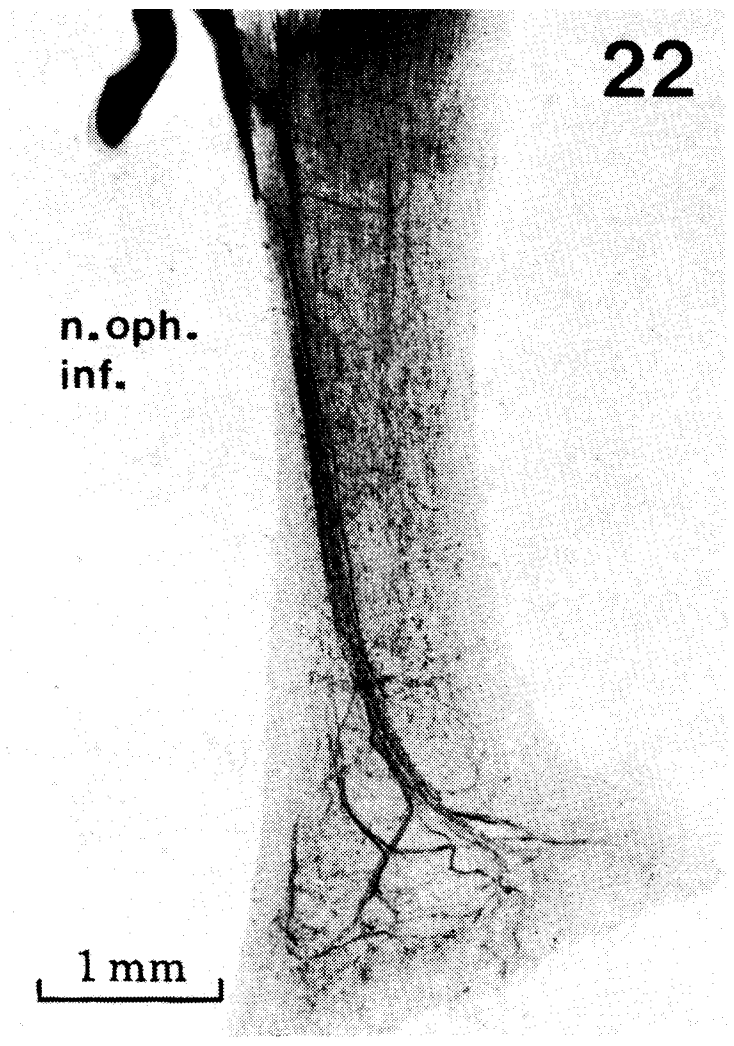

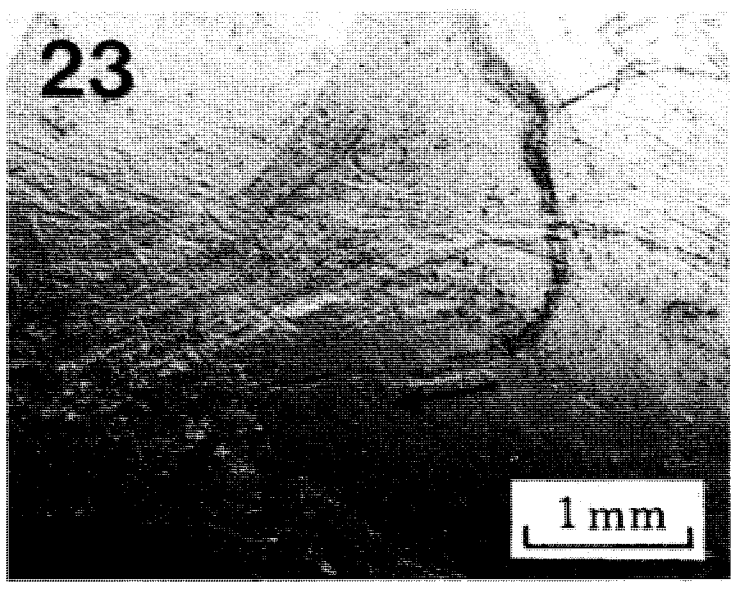

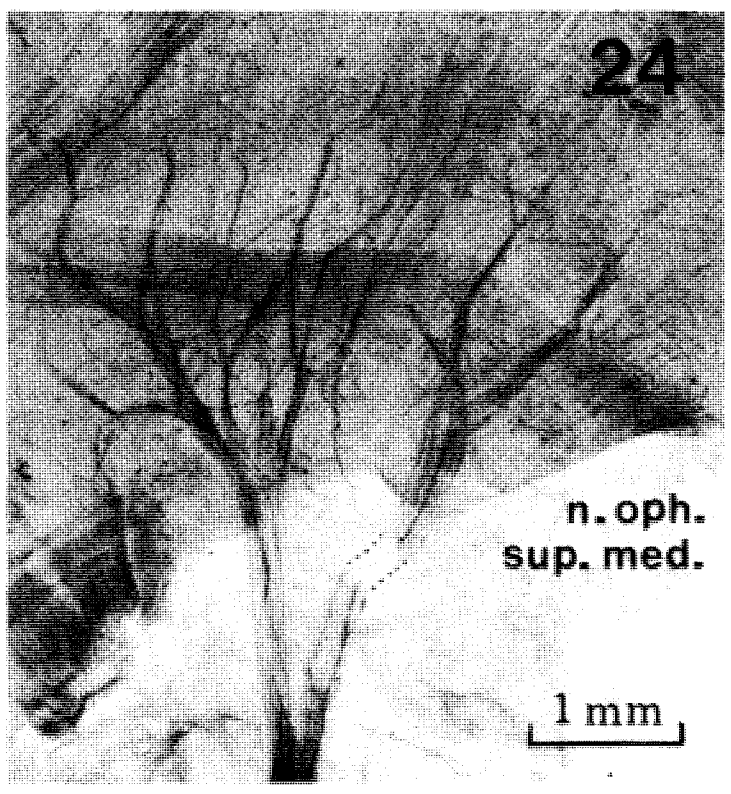

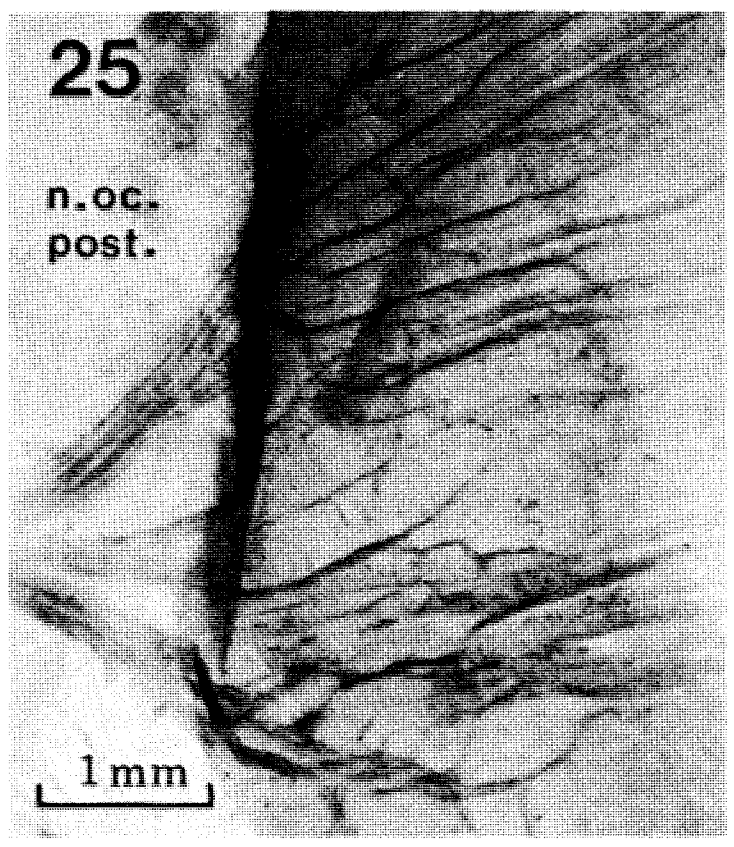

FIGURES 15–25. For description see p. 174.

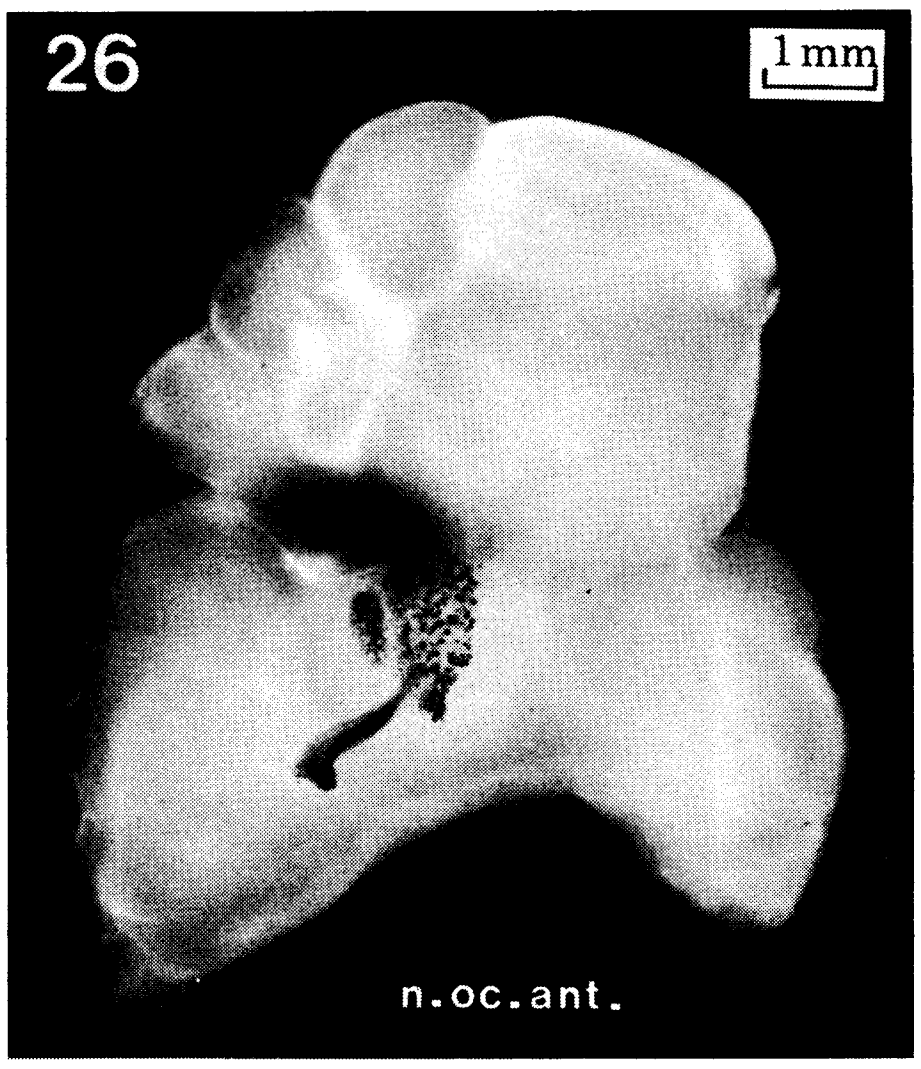

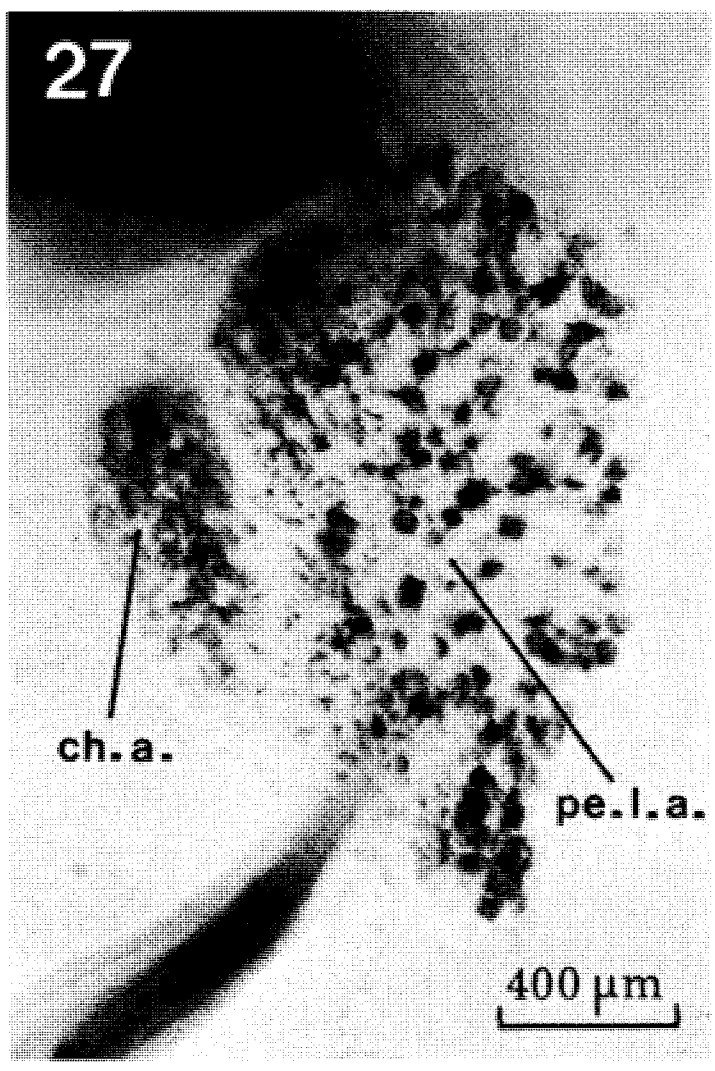

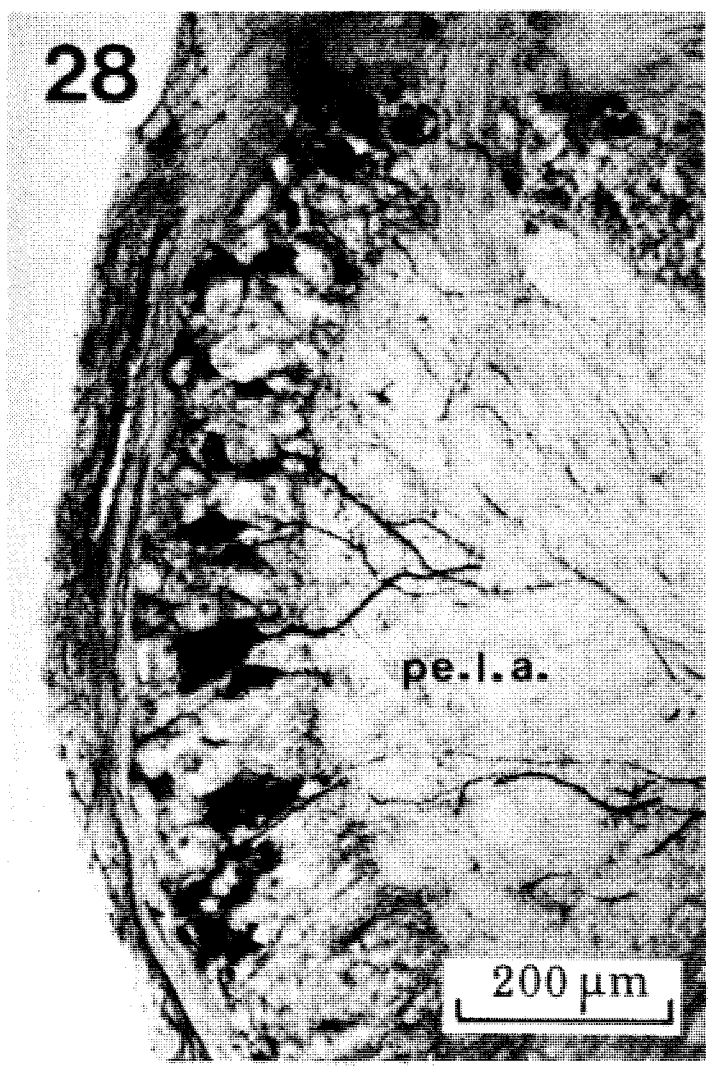

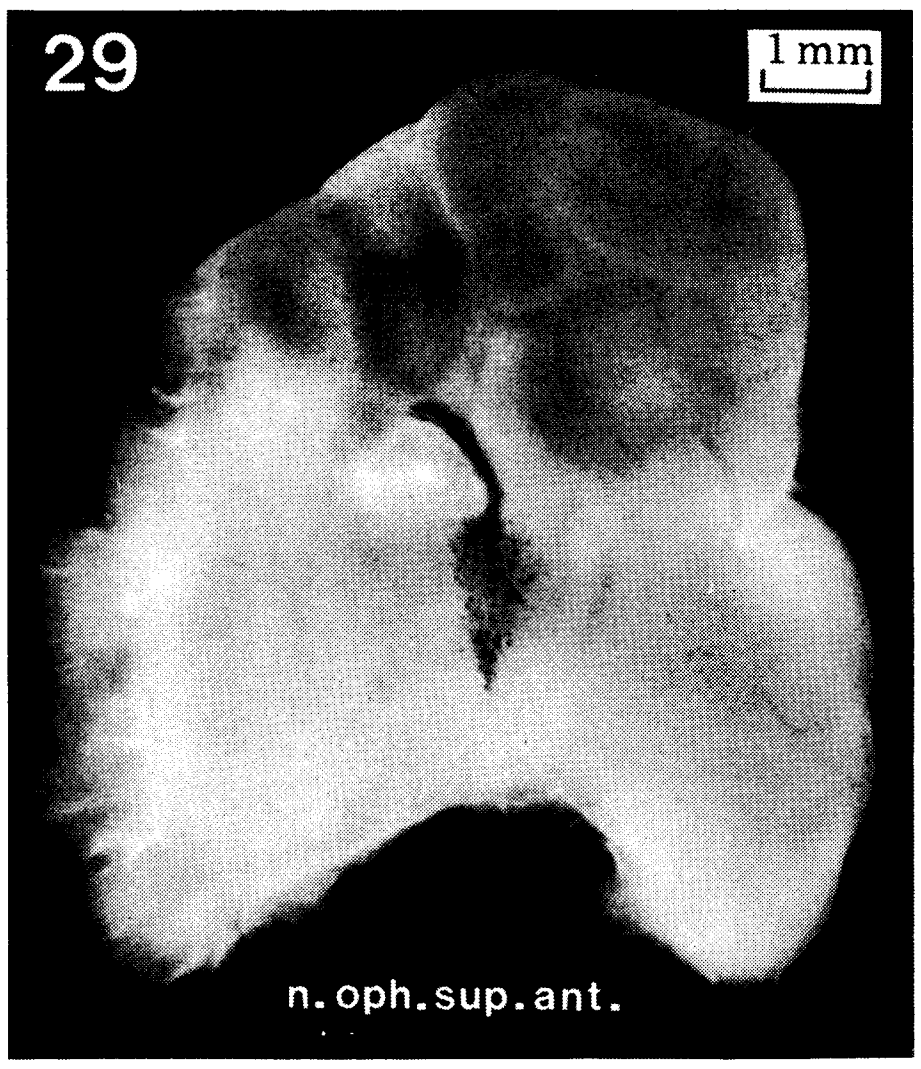

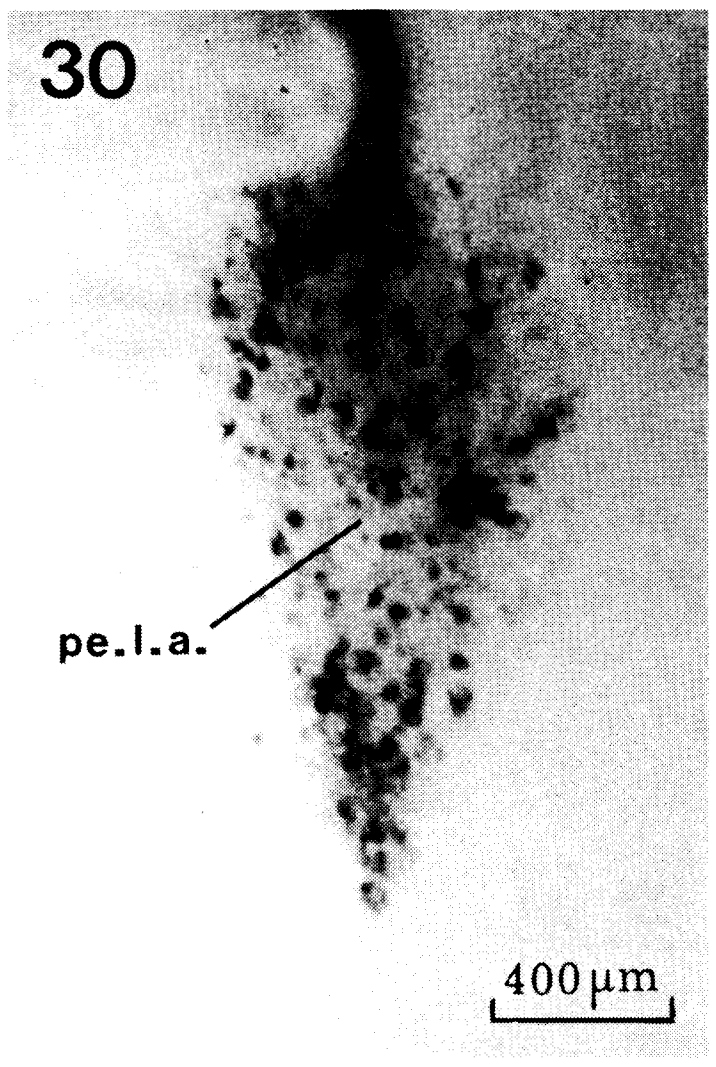

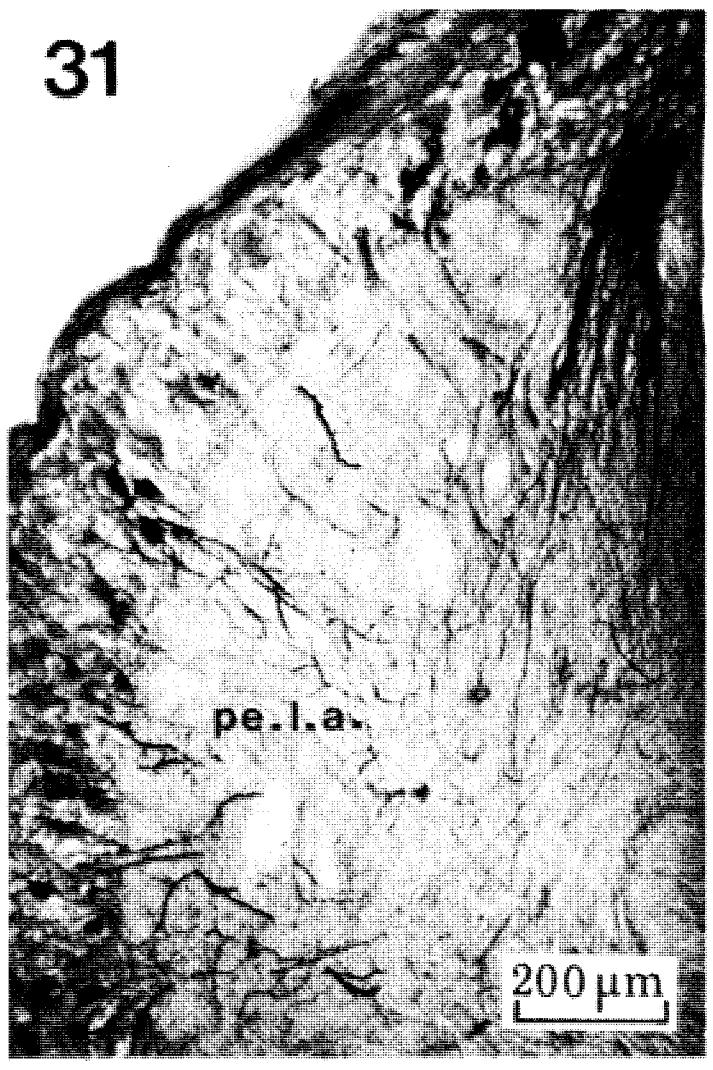

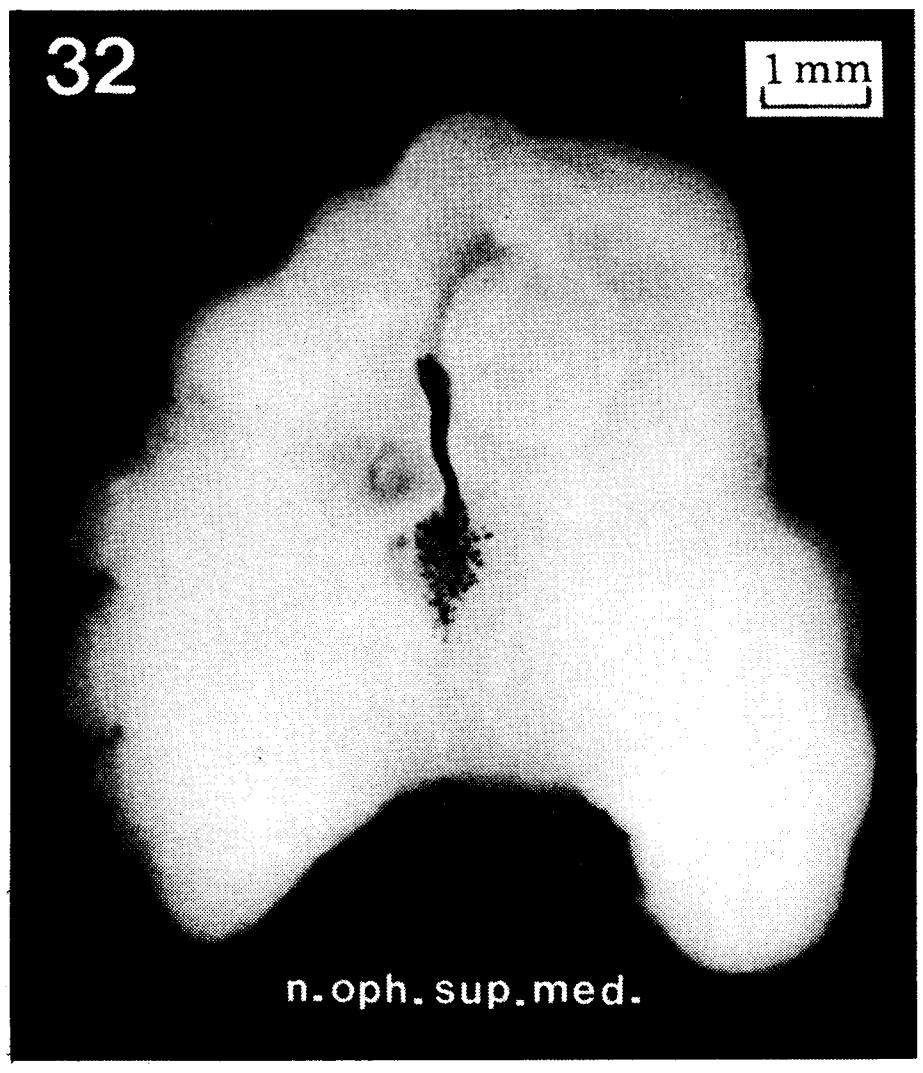

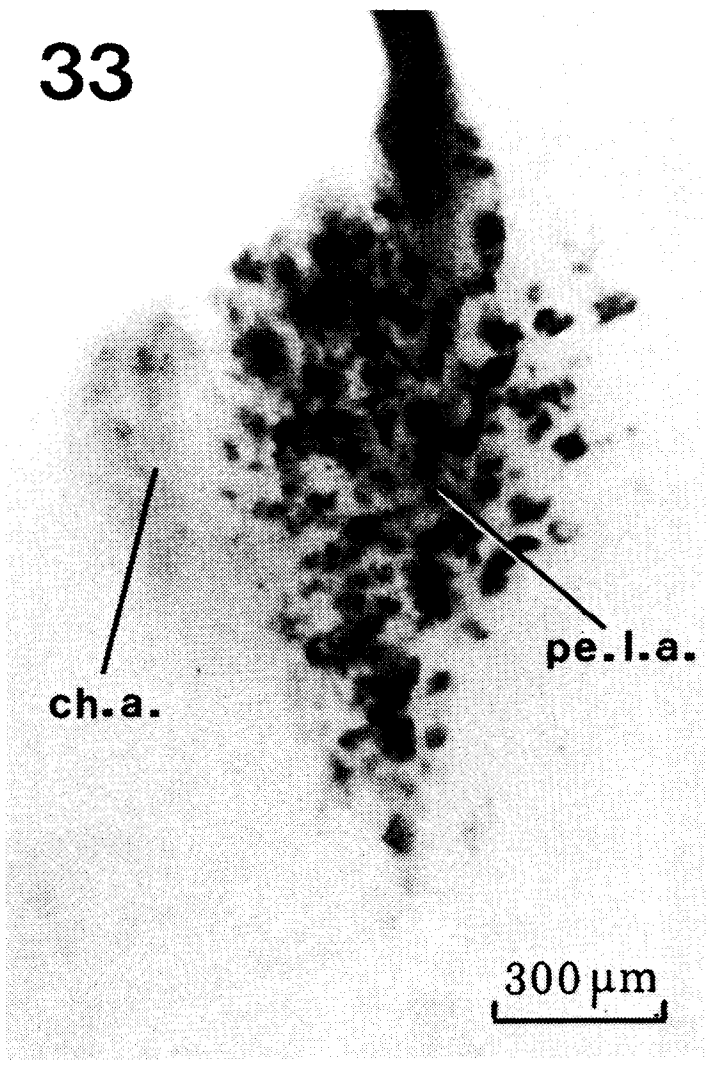

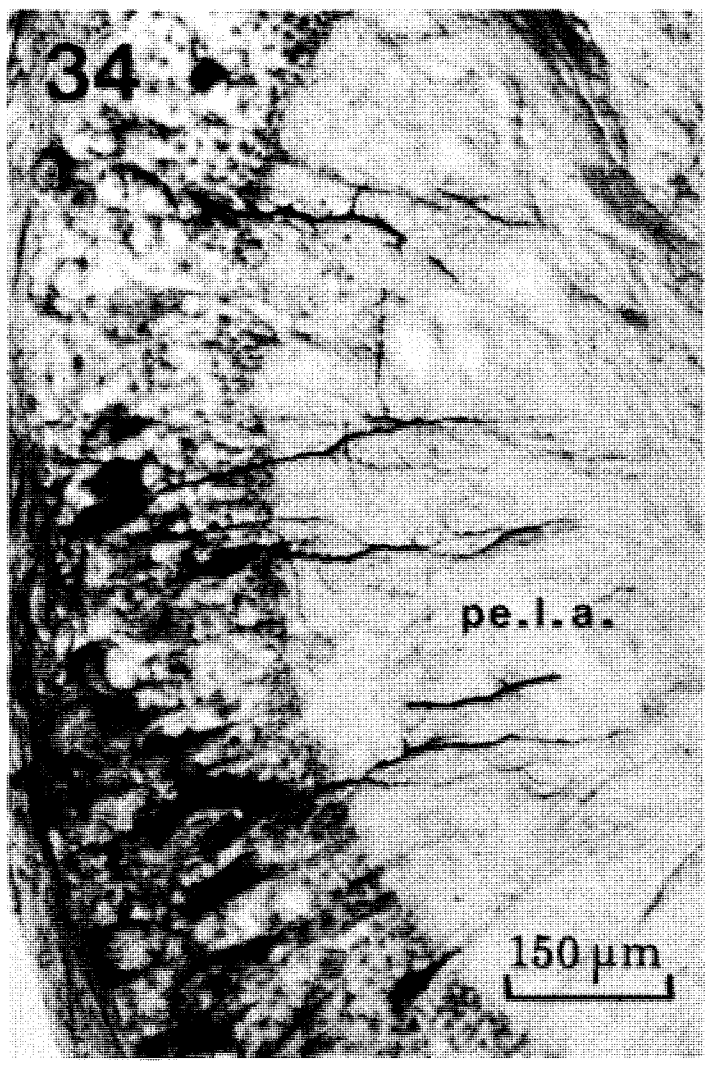

FIGURES 26–34. For description see p. 174.

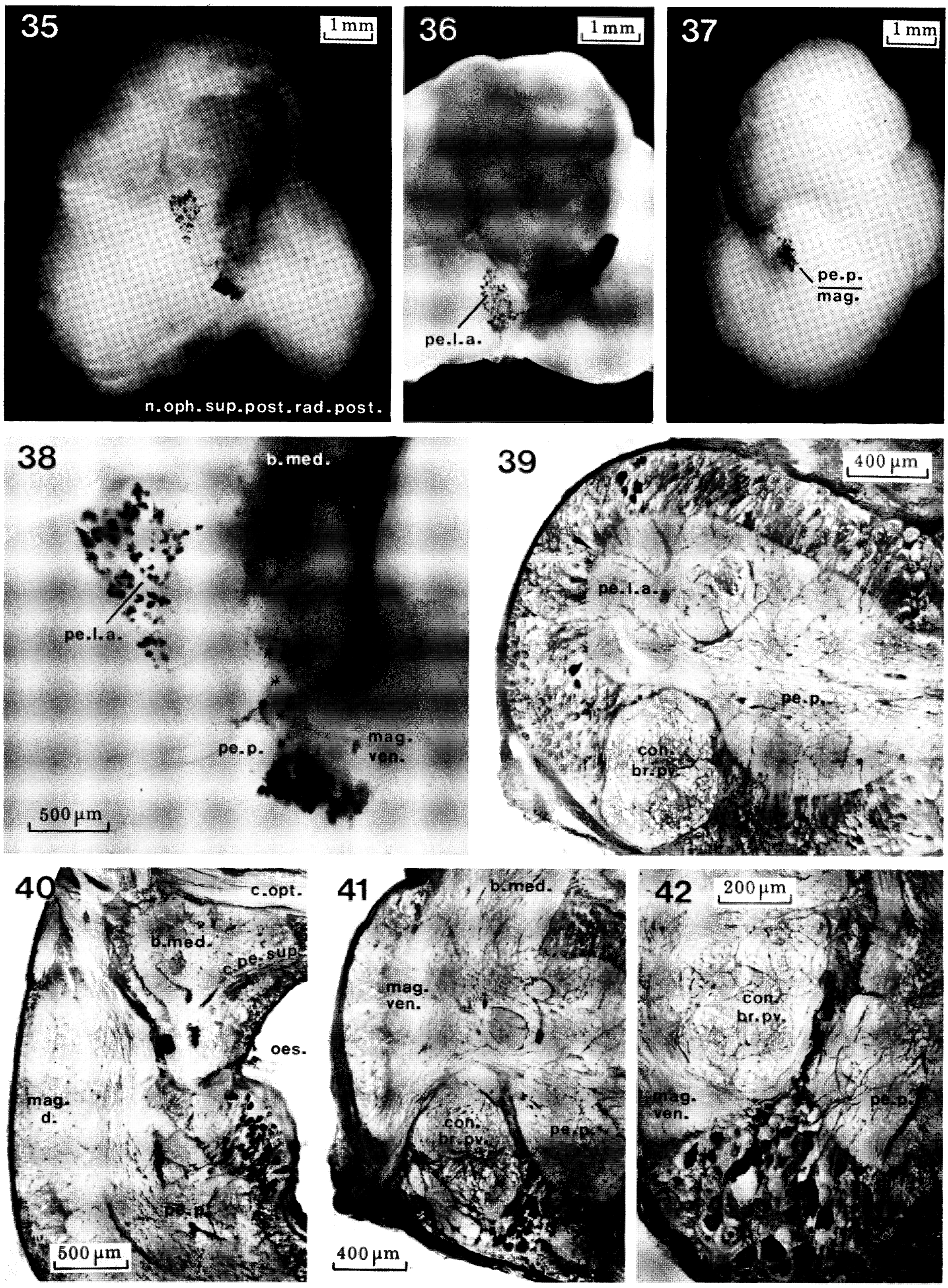

FIGURES 35–42. For description see p. 174.

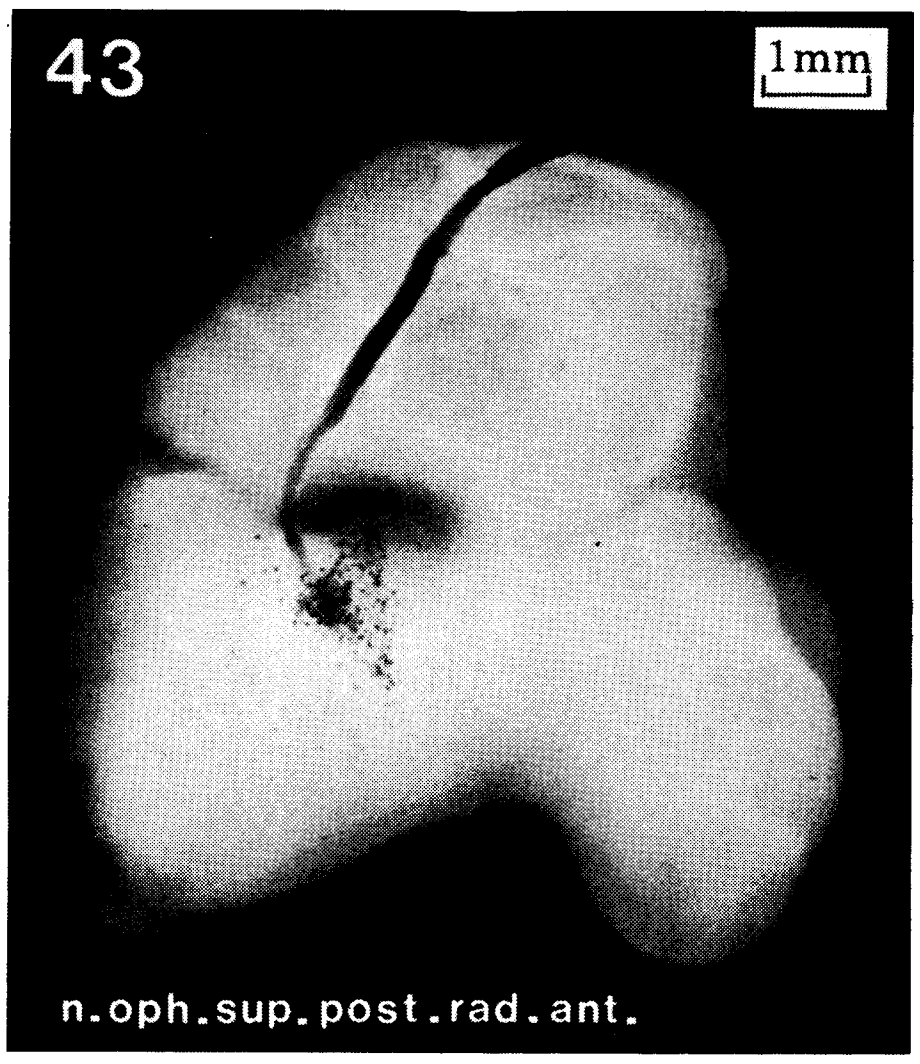

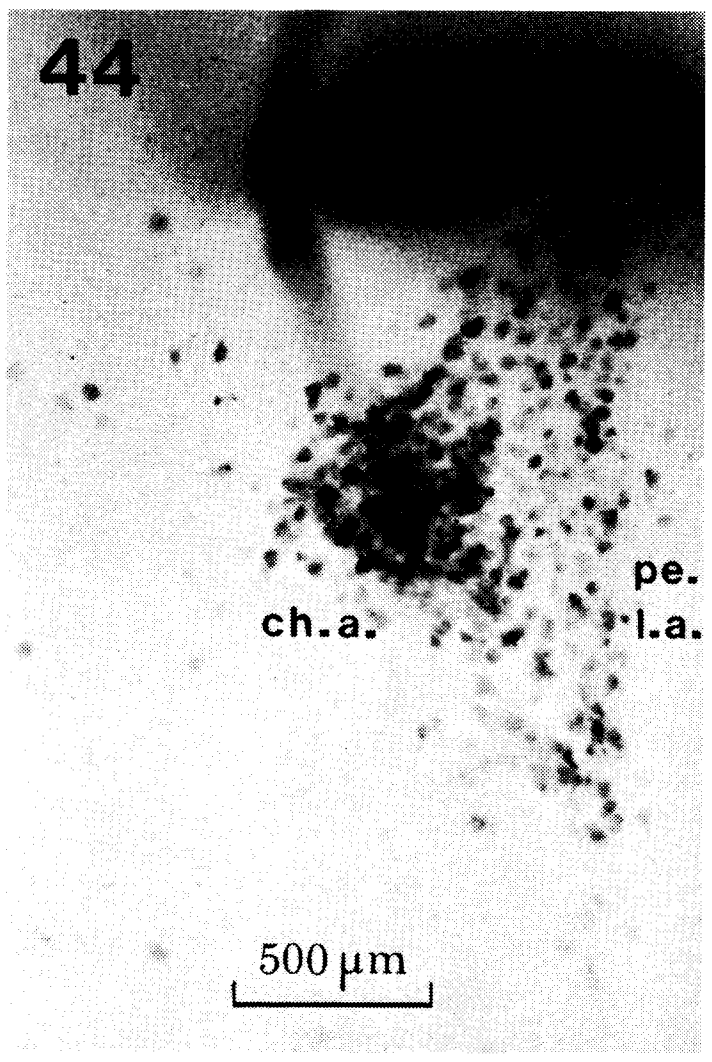

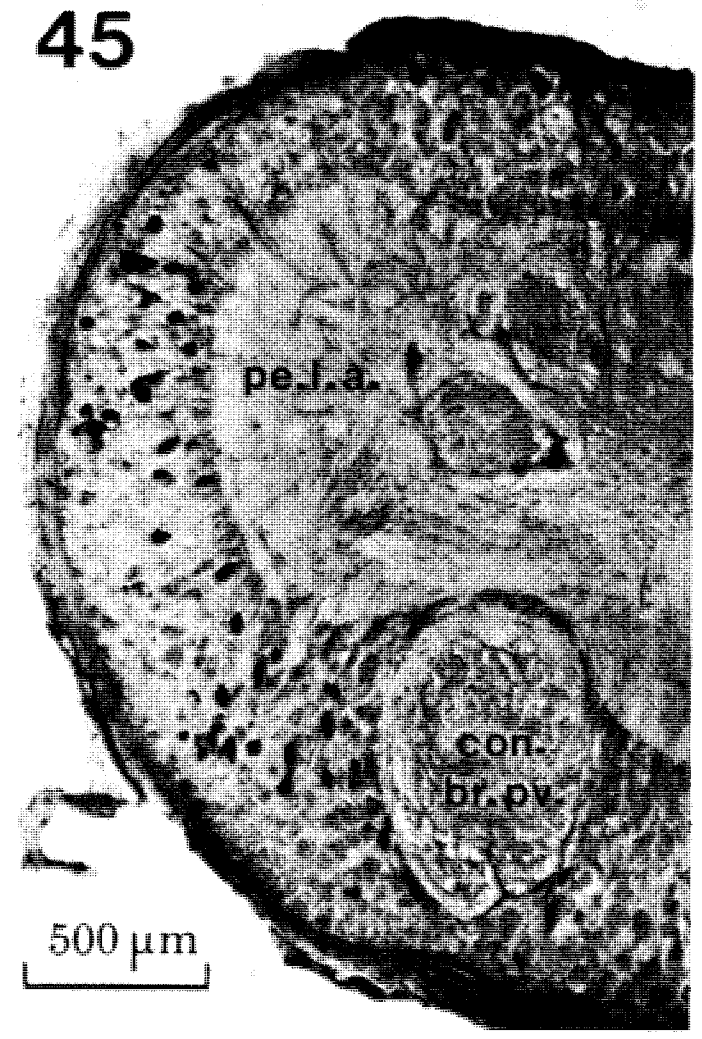

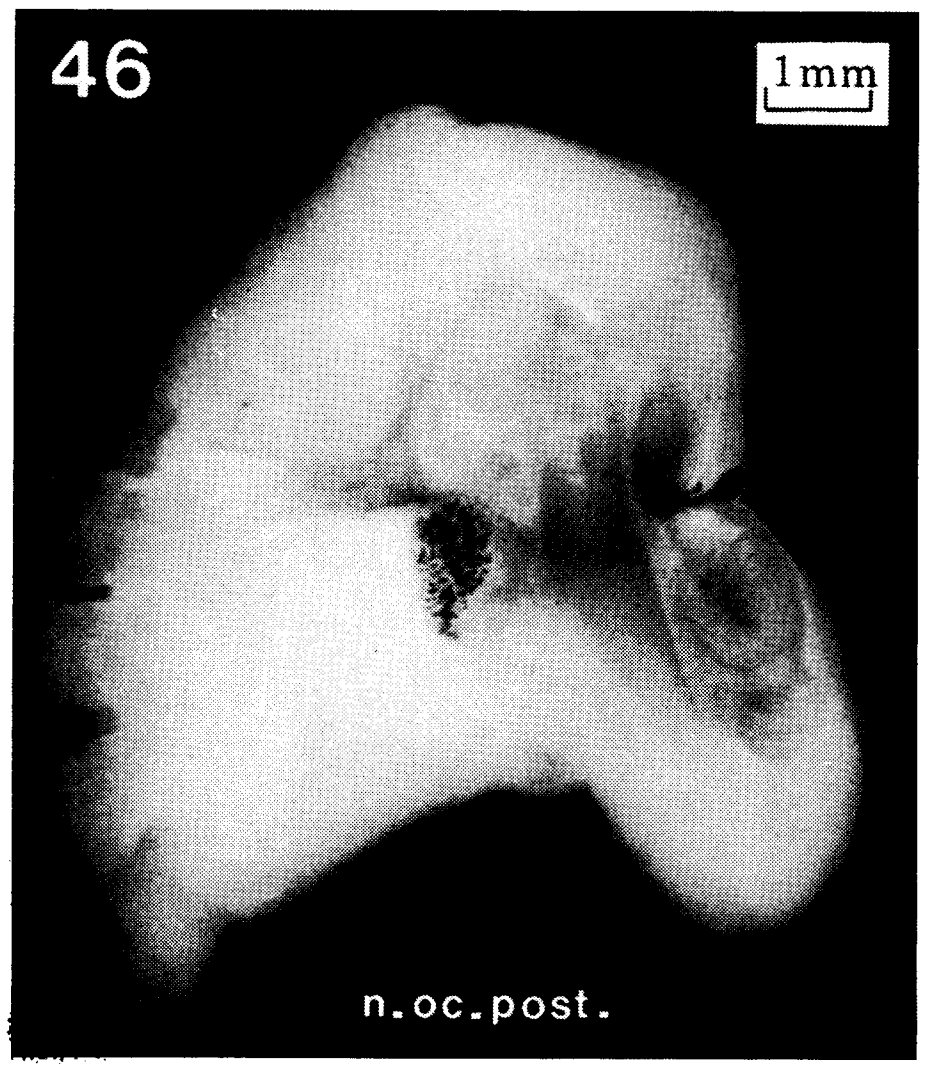

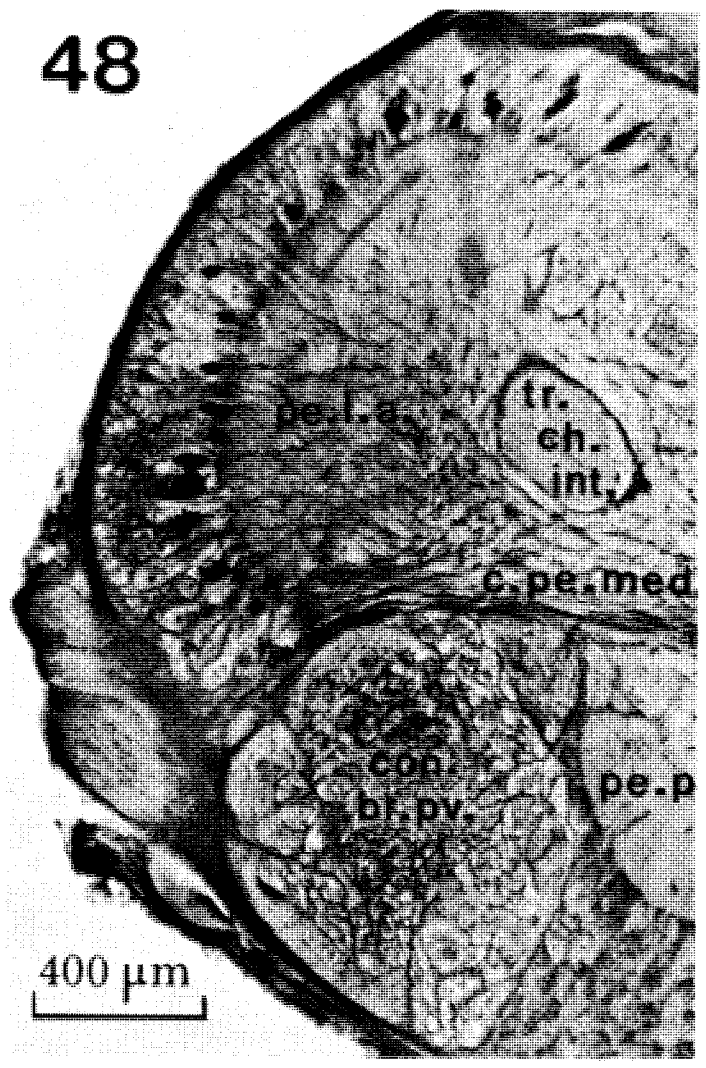

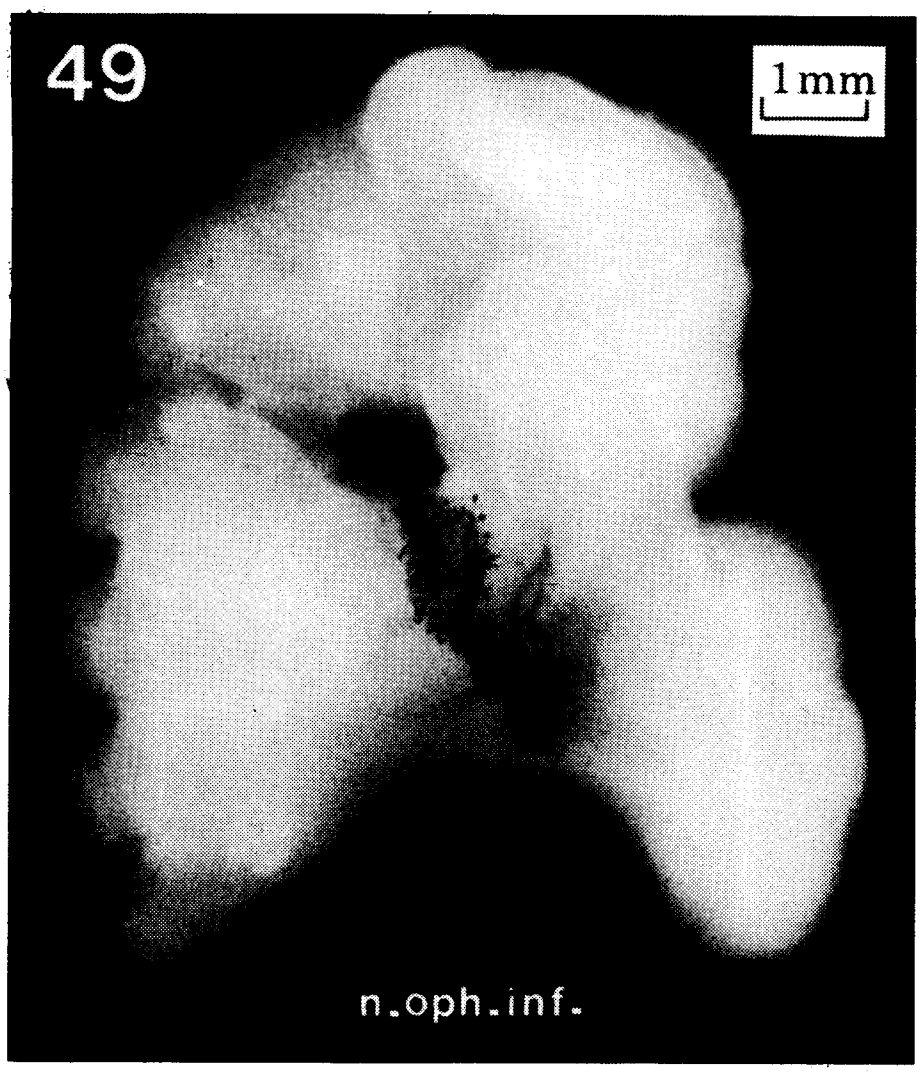

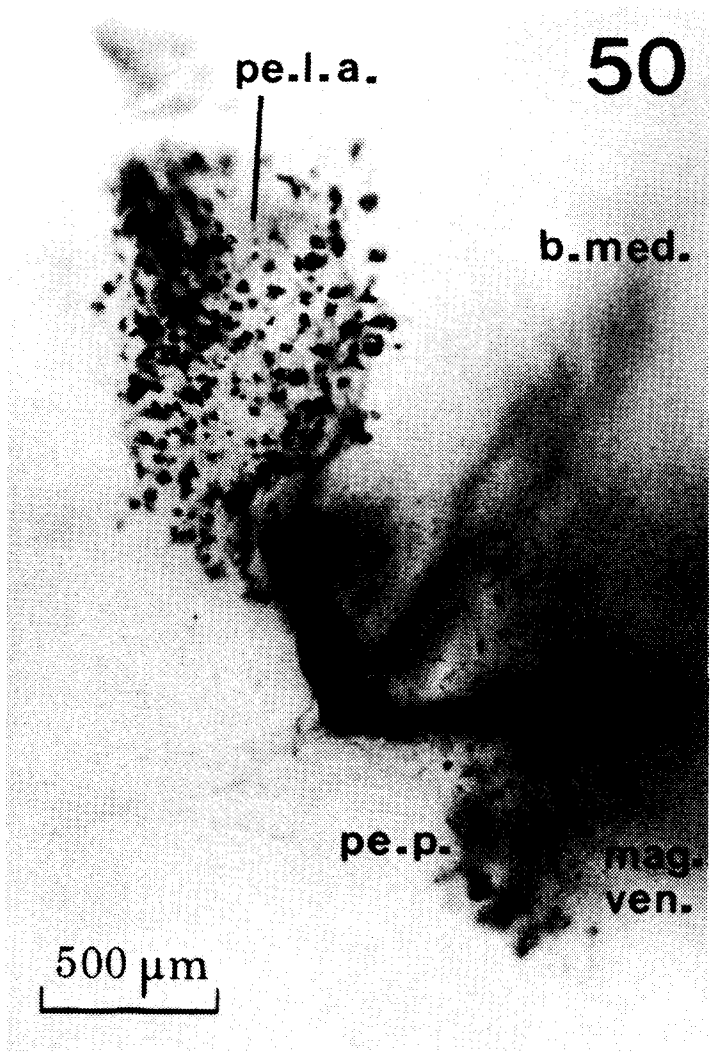

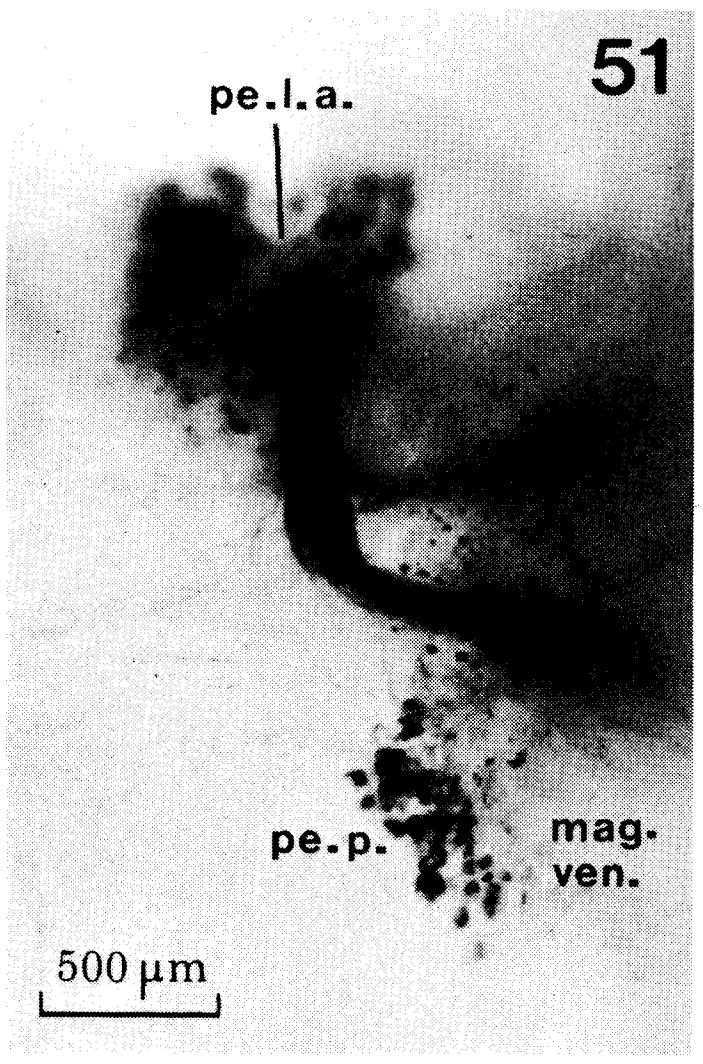

Figures 43–51. For description see p. 175.

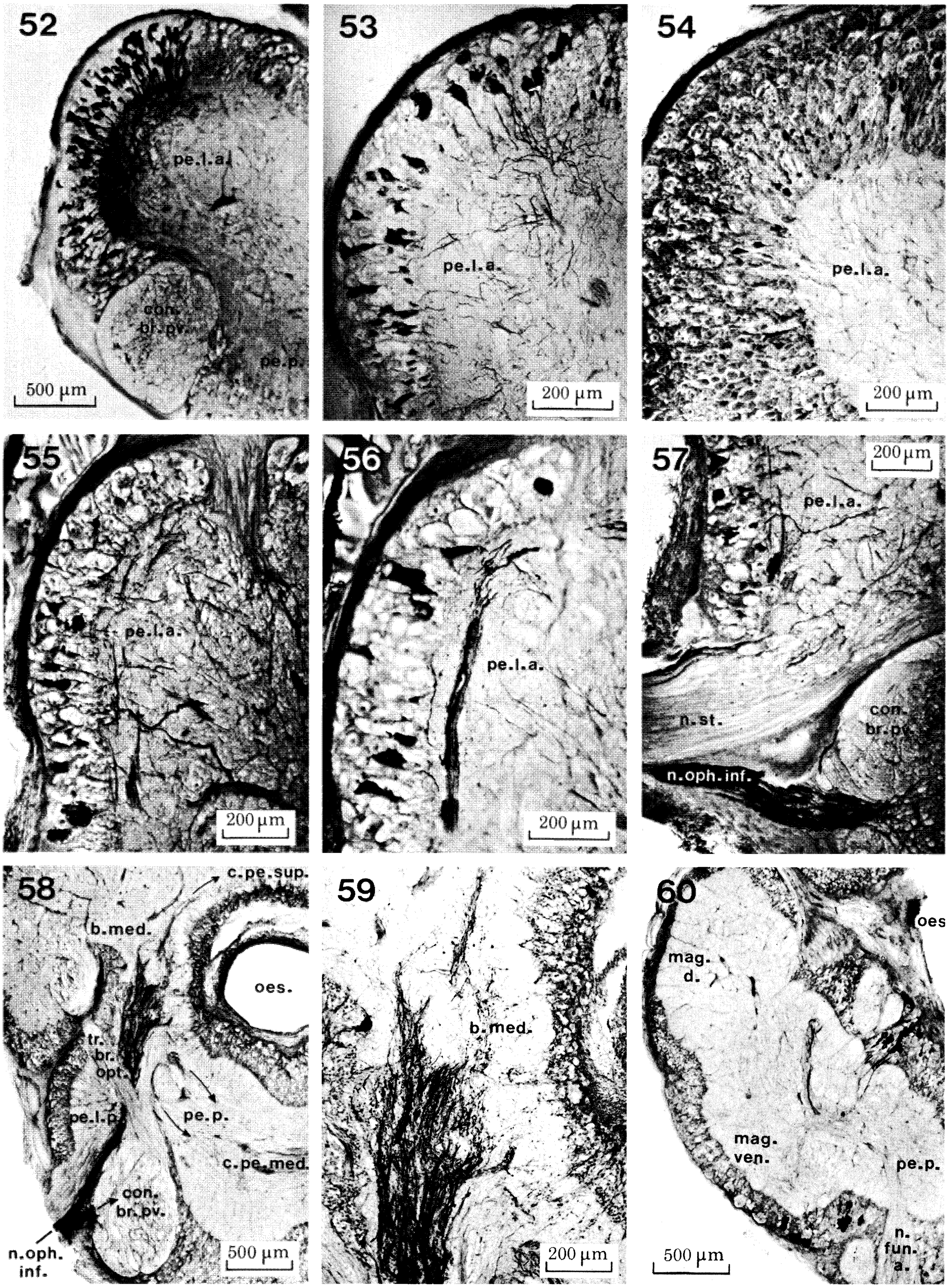

FIGURES 52–60. For description see p. 175.

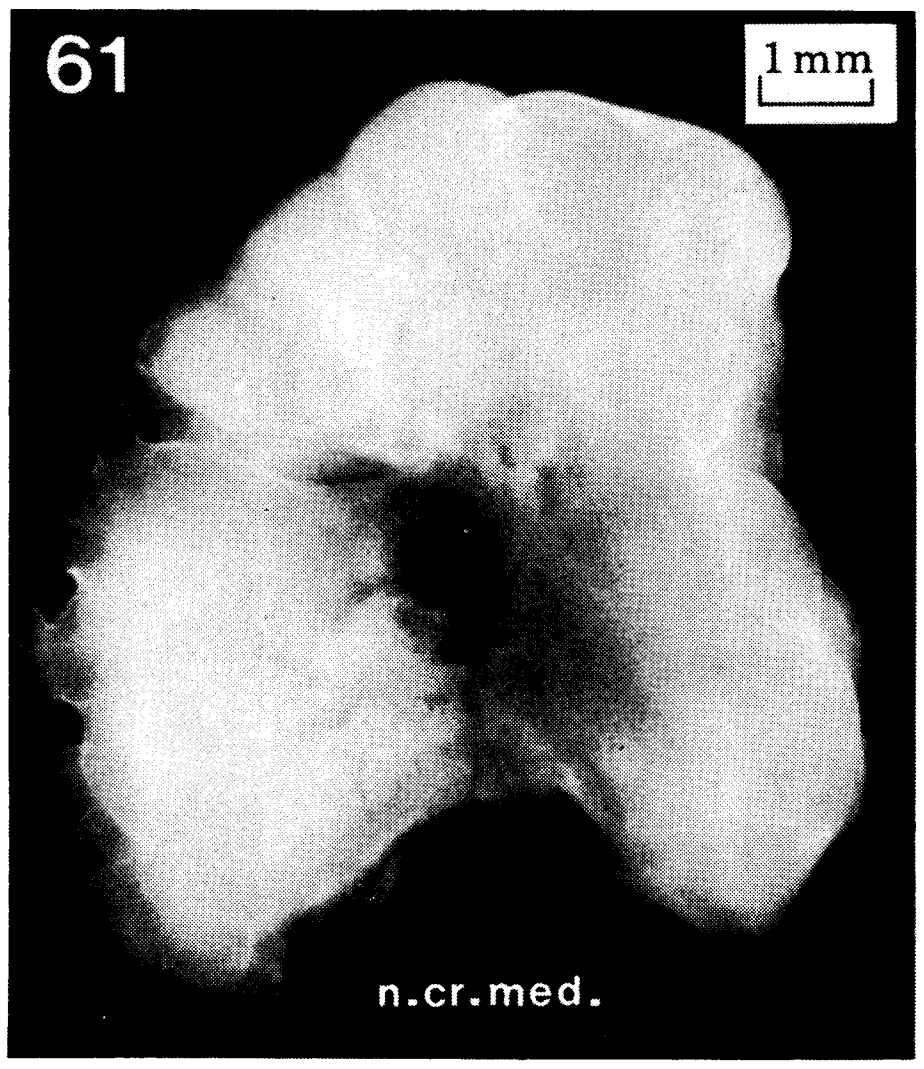

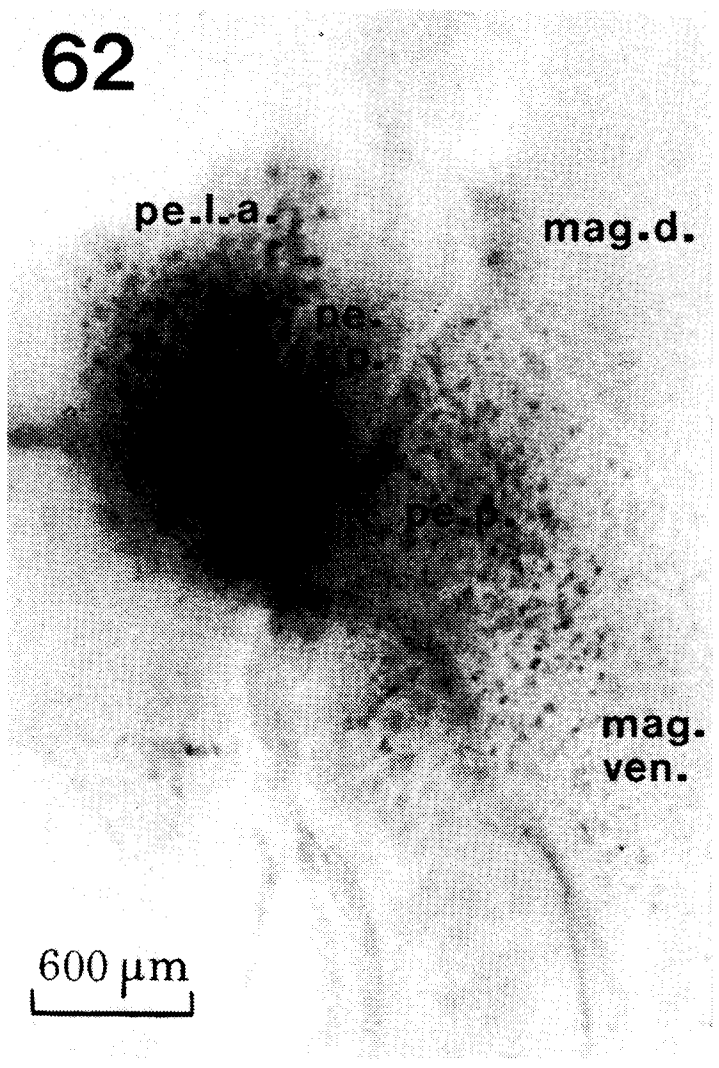

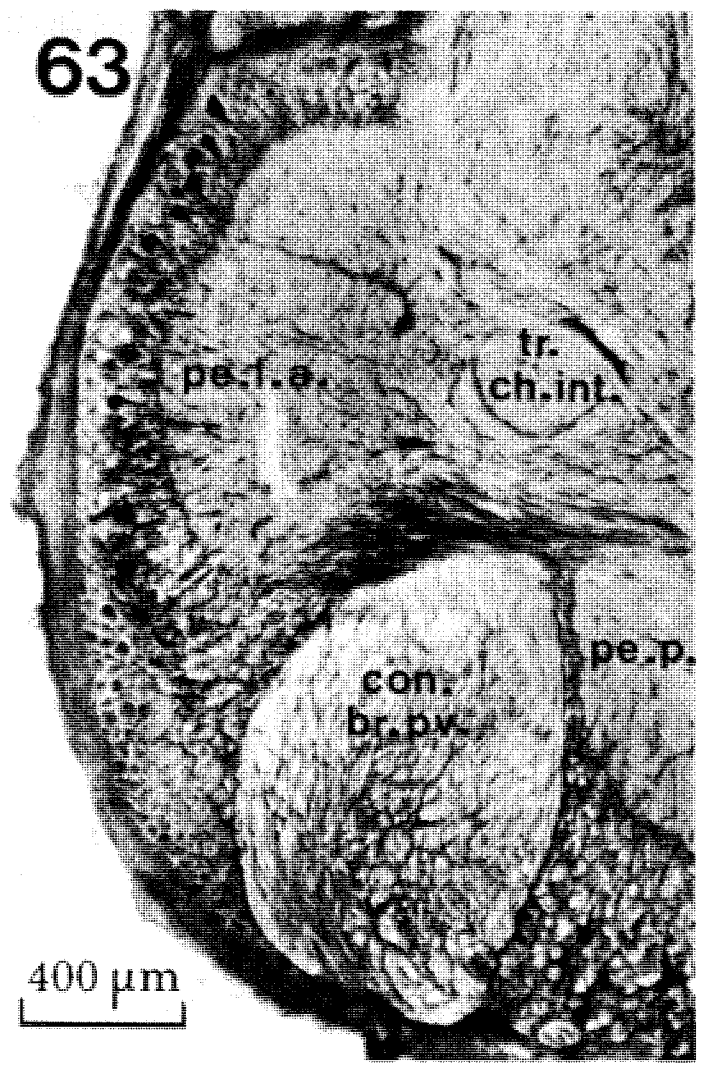

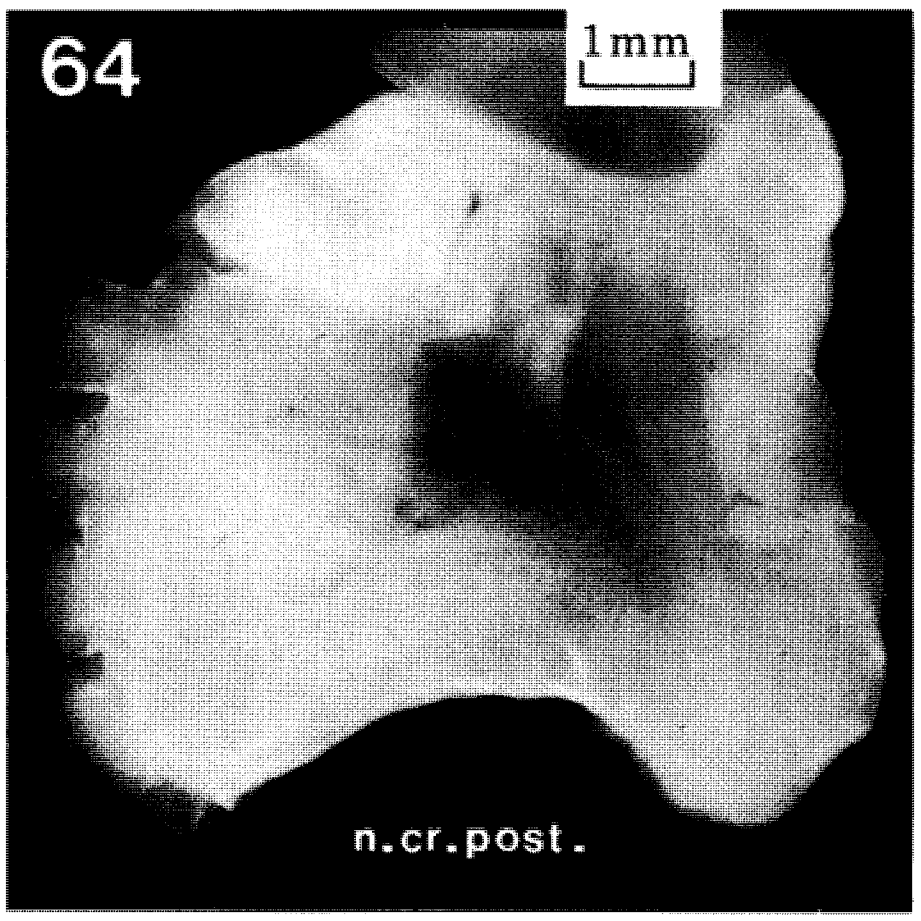

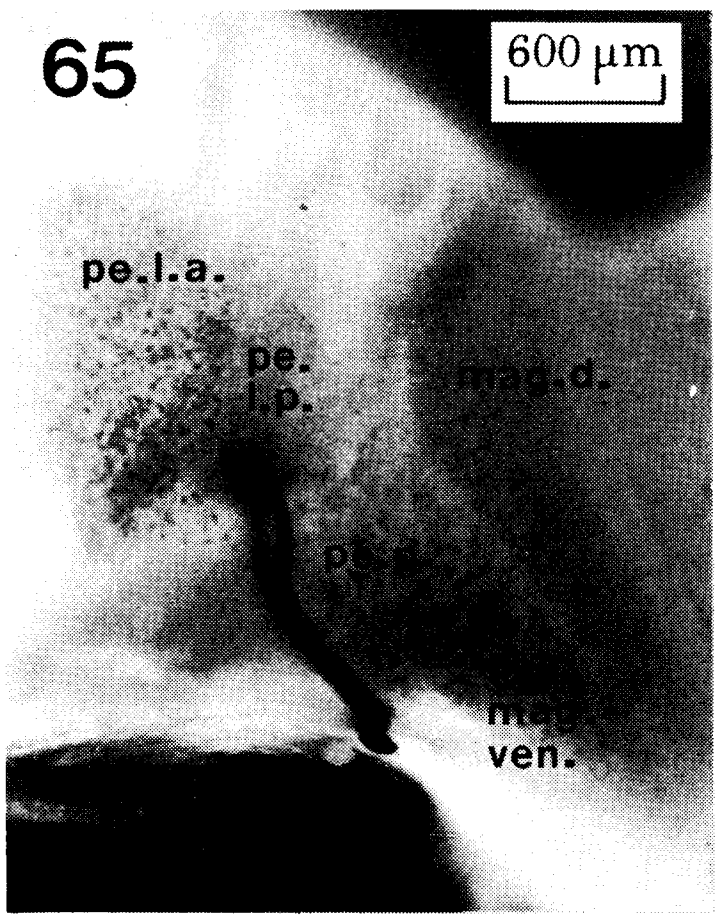

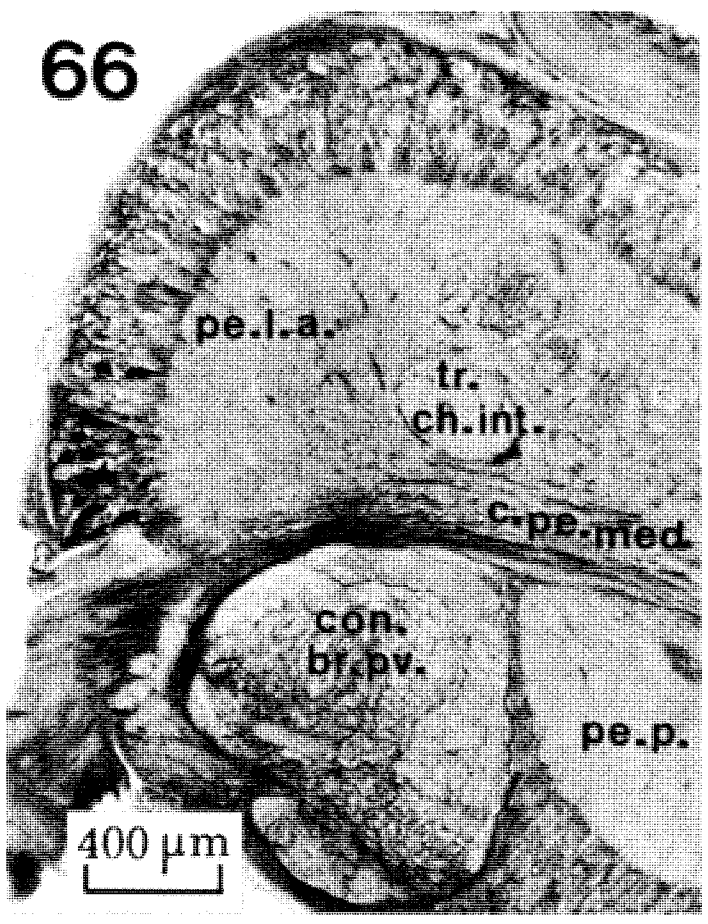

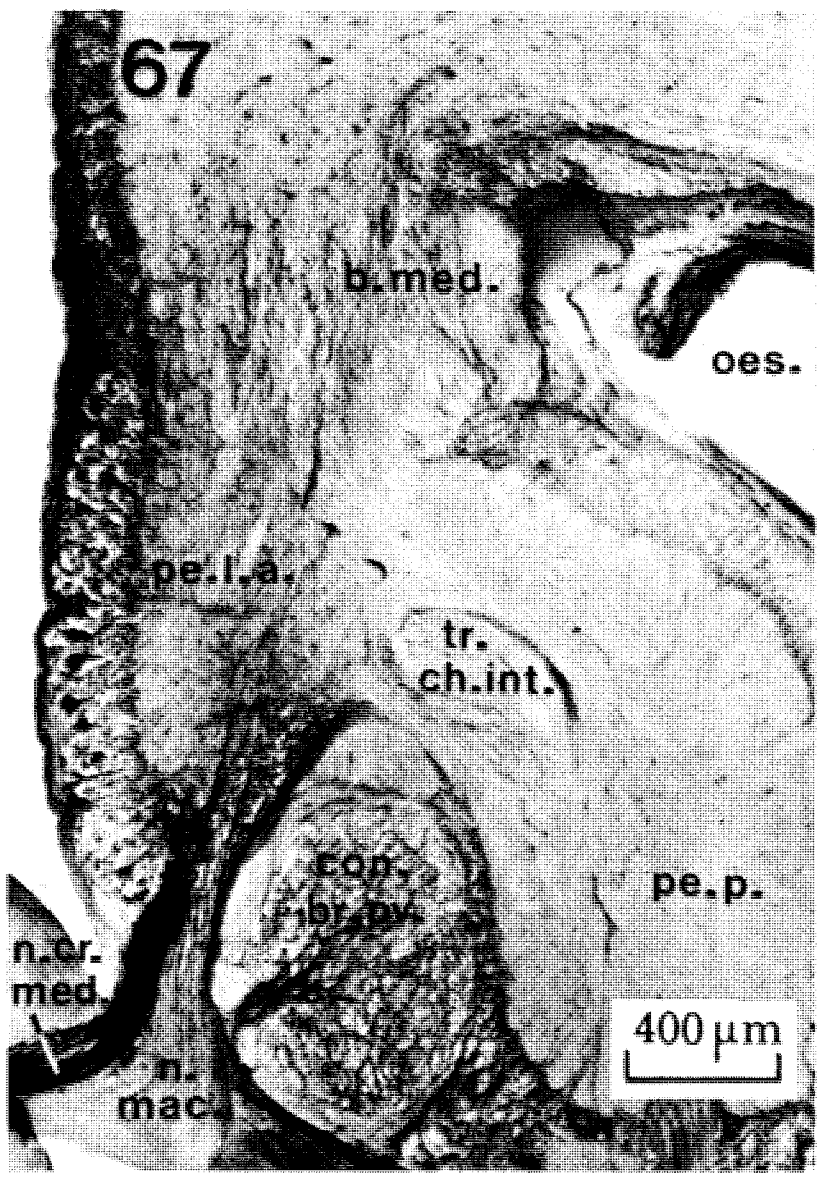

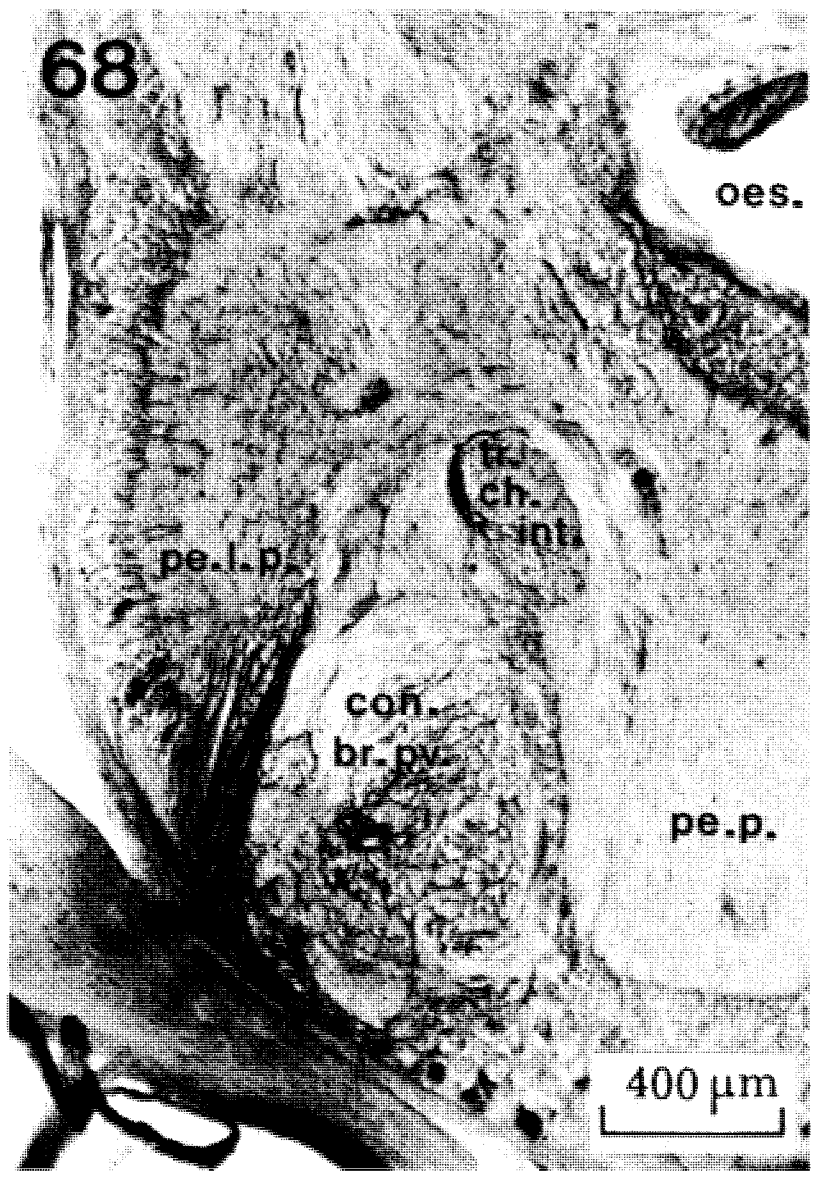

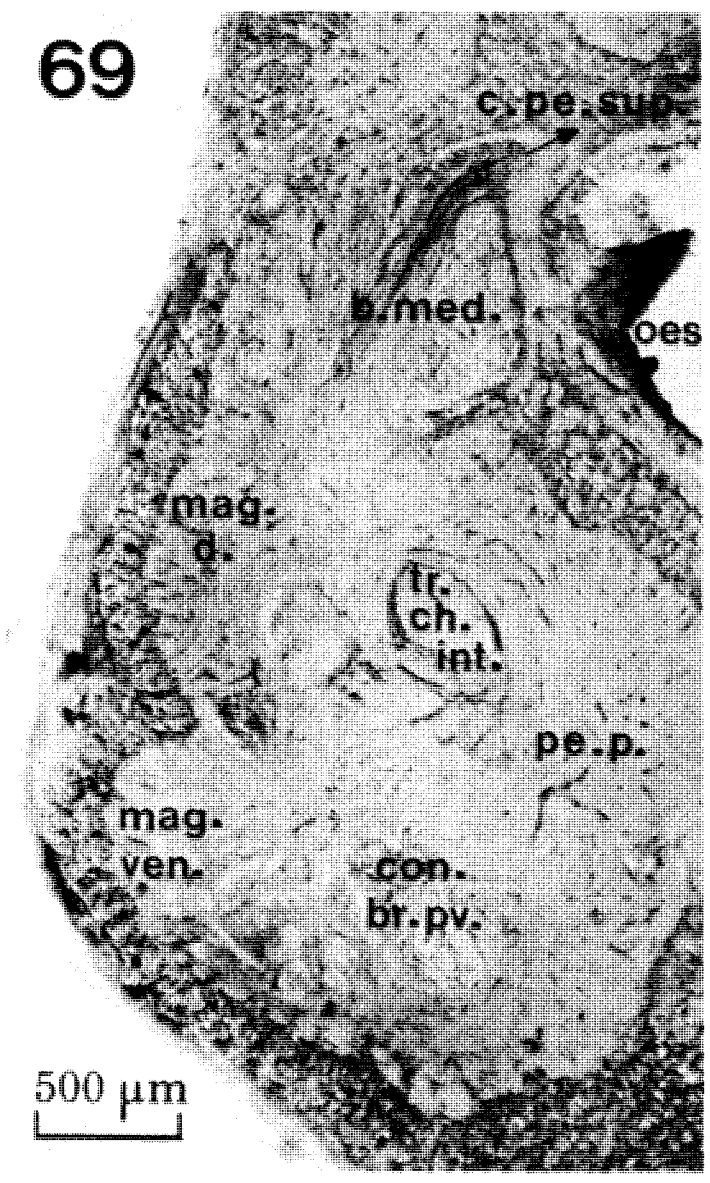

FIGURES 61–69. For description see p. 175.

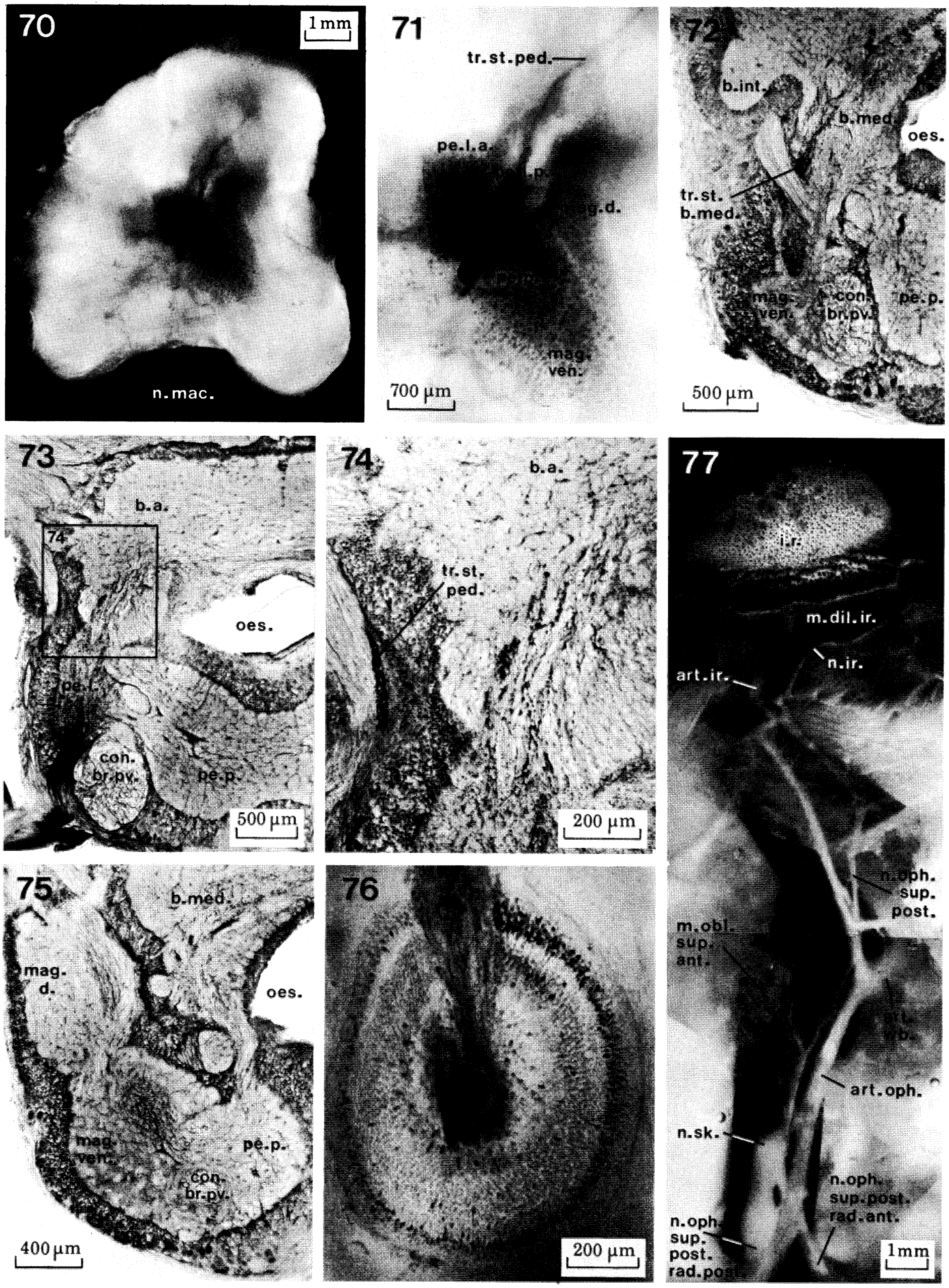

FIGURES 70–77. For description see p. 176.

DESCRIPTION OF PLATE 5

FIGURES 43–45. Centripetal cobalt filling of the anterior root of the posterior superior ophthalmic nerve showing somata mainly in the anterior chromatophore lobe, but some also in the front part of the anterior lateral pedal lobe, and a few scattered in the anterior suboesophageal mass of the brain. Lateral view of the brain (figures 43 and 44) and transverse section of the anterior lateral pedal lobe (figure 45) of the same preparation.

FIGURES 46–48. Centripetal cobalt filling of the posterior oculomotor nerve showing somata in the anterior lateral pedal lobe. Lateral view of the brain (figures 46 and 47) and transverse section of the anterior lateral pedal lobe (figure 48) of the same preparation.

FIGURES 49–51. Centripetal cobalt filling of the inferior ophthalmic nerve showing somata in the anterior lateral pedal lobe and in the region between the posterior pedal and magnocellular lobes (compare figures 35 and 38 of the posterior root of the posterior superior ophthalmic nerve). Fibres are also filled in the neuropil of these lobes and in the median basal lobe. Lateral (figures 49 and 50) and ventro-lateral view (figure 51) of the same brain.

DESCRIPTION OF PLATE 6

FIGURES 52 AND 53. Somata in the anterior lateral pedal lobe after centripetal cobalt filling of the inferior ophthalmic nerve. Transverse sections of the preparation of figure 49.

FIGURE 54. Small somata at the front end of the anterior lateral pedal lobe (close to the anterior chromatophore lobe) after centripetal cobalt filling of the inferior ophthalmic nerve. Transverse section of the preparation of figure 49.

FIGURES 55 AND 56. Somata in the anterior lateral pedal lobe and afferent fibres running parallel to its perikaryal layer after centripetal cobalt filling of the inferior ophthalmic nerve. Transverse sections of the preparation of figure 49.

FIGURE 57. Somata in the anterior lateral pedal lobe and afferent fibres running into the brachial to palliovisceral lobe connective after centripetal cobalt filling of the inferior ophthalmic nerve. Transverse section of the preparation of figure 49.

FIGURE 58. Afferent fibres passing to the median basal lobe after centripetal cobalt filling of the inferior ophthalmic nerve. Arrows indicate the course of the afferent fibres in the neighbouring sections. Transverse section, slightly oblique.

FIGURE 59. Afferent fibres in the median basal lobe. Detail of figure 58.

FIGURE 60. Somata in the region between the posterior pedal and magnocellular lobes after centripetal cobalt filling of the inferior ophthalmic nerve (compare figures 40–42 of the posterior root of the posterior superior ophthalmic nerve). Transverse section (slightly oblique) of the same preparation as that of figure 58.

DESCRIPTION OF PLATE 7

FIGURES 61 AND 62. Centripetal cobalt filling of the middle crista nerve showing somata in the anterior and posterior lateral pedal lobe, the posterior pedal lobe, and the dorsal and ventral magnocellular lobes. Lateral view of the brain, slightly from ventral.

FIGURE 63. Somata of efferent fibres in the anterior lateral pedal lobe and posterior pedal lobe after centripetal cobalt filling of the middle crista nerve. Afferent fibres are seen proceeding to the middle pedal commissure. Transverse section.

FIGURES 64 AND 65. Centripetal cobalt filling of the posterior crista nerve showing somata in the anterior and posterior lateral pedal lobe, the posterior pedal lobe, and the dorsal and ventral magnocellular lobes. Lateral view of the brain (figure 65), slightly from ventral (figure 64).

FIGURE 66. Somata of efferent fibres in the anterior lateral pedal lobe after centripetal cobalt filling of the posterior crista nerve. Afferent fibres are seen proceeding to the middle pedal commissure. Transverse section, slightly oblique.

FIGURES 67–69. Efferent somata and afferent fibres after centripetal cobalt filling of the middle (figures 67 and 68) and posterior (figure 69) crista nerves. Somata are seen in the anterior lateral pedal lobe (figure 67), posterior lateral pedal lobe and posterior pedal lobe (figure 68), and in the dorsal and ventral magnocellular lobes (figure 69). Afferent fibres are seen proceeding to the median basal lobe and suprapedal commissure (figures 67 and 69), to the posterior pedal lobe (figure 69), and into the brachial to palliovisceral lobe connective (figure 67). Transverse sections (figures 67 and 68), slightly oblique (figure 69).

over (figure 28); however, anteriorly in a narrow band, about 100 μm wide, only small somata occur (figure 27).

3.4.2. *N. oculomotorius posterior* (*figures 46–48*)

Somata of the efferent fibres of n.oc.post. were seen only in the anterior lateral pedal lobe. They are more numerous than for most of the other eye muscle nerves and are arranged, like those of n.oc.ant., in a triangular area as seen laterally (figure 46). Its border is almost straight anteriorly and curved outwards posteriorly. Large and medium somata were filled mostly in the posterior region, and none anteriorly (figures 47 and 48). Small somata were found scattered all over, but more frequently in the posterior bulge. They were numerous in a narrow band, about 120 μm wide, at the front where there were no medium and large somata (figure 47).

3.4.3. *N. ophthalmicus superior anterior* (*figures 29–31*)

Somata of the efferent fibres of n.oph.sup.ant. were stained only in the anterior lateral pedal lobe. Compared with the two oculomotor nerves, they are less numerous and their arrangement is in a somewhat smaller elongated triangular area which is almost straight anteriorly and curved towards posterior. Two experiments were made and in both the groups of filled cells tapered ventrally (figure 29). Small, medium and a few large somata were found distributed all over the lobe (figure 30). An obvious concentration of medium and some large somata occur around the point of entry of the nerve into the lobe (figure 31).

3.4.4. *N. ophthalmicus superior medialis* (*figures 32–34*)

Somata of the efferent fibres of n.oph.sup.med. were stained in two areas of the brain: the anterior chromatophore lobe and the anterior lateral pedal lobe (figure 32). In the anterior chromatophore lobe, the somata are arranged in a small band posteriorly, close to the anterior lateral pedal lobe. They are less in number than those of the n.oc.ant. Large and medium somata of the anterior lateral pedal lobe are arranged in a small almost triangular area as seen laterally, sharply tapered ventrally. They are scattered all over the lobe. In an anterior band, about 100 μm wide and close to the anterior chromatophore lobe, the somata are mostly small (figures 33 and 34).

DESCRIPTION OF PLATE 8

FIGURES 70 AND 71. Centripetal cobalt filling of the macula nerve showing somata in the anterior and posterior lateral pedal lobe, the posterior pedal lobe, and the dorsal and ventral magnocellular lobes, and afferent fibres in the statocyst to peduncle lobe tract. Lateral view of the brain, slightly from ventral.

FIGURES 72–75. Efferent somata and afferent fibres after centripetal cobalt filling of the macula nerve. Figures 73 and 74: Somata in the lateral pedal and posterior pedal lobes, afferent fibres in the statocyst to peduncle lobe tract, and afferent fibres passing to the anterior basal lobe. Figures 72 and 75: Somata in the dorsal and ventral magnocellular lobes and posterior pedal lobe, and afferent fibres proceeding to the median basal lobe. (Somata in the dorsal magnocellular lobe are small and do not show well because of absence of contrast.) Transverse but very oblique sections of one preparation, with the more dorsal part further forward than the ventral.

FIGURE 76. Somata in the macula of the statocyst after cobalt filling from the optic tract. This tract includes fibres of the statocyst to peduncle lobe tract. The dark area in the middle is a remnant of the statolith. Whole-mount of the left macula.

FIGURE 77. Dissection of the posterior superior ophthalmic nerve of the left eye showing its continuation beyond the extraocular eye muscles to innervate the iris. Branches to the anterior superior oblique muscle are also seen.

3.4.5. *N. ophthalmicus superior posterior radix anterior* (*figures 43–45*)

Somata of the efferent fibres of n.oph.sup.post.rad.ant. were stained in both the anterior chromatophore lobe and the anterior lateral pedal lobe (figure 43). In the latter, unlike the situation with all other eye muscle nerves, somata were stained only in its anterior half, sharply separated from the posterior half where there were none (figure 43).

The somata in the anterior chromatophore lobe are medium in size. They are distributed irregularly but with a clear concentration posteriorly in the middle of the lobe and only few somata dorsal and ventral. In addition a few single somata are scattered in the anterior suboesophageal mass of the brain (figure 44). In the anterior lateral pedal lobe the somata are small and medium and less in number than for any of the other eye muscle nerves and are regularly arranged in a small band, about 400 μm wide, anteriorly in the lobe, passing from dorsal to ventral (figure 45).

3.4.6. *N. ophthalmicus superior posterior radix posterior* (*plate 4, figures 35–42*)

N.oph.sup.post.rad.post. contains afferent and efferent fibres. The latter include motor fibres to the eye muscles and presumably fibres that synapse in the superior ophthalmic ganglion. The nerve divides into three branches within the brain. One runs immediately into the base of the median basal lobe. A second passes to the lateral pedal lobe, and a third continues vertically downwards to the posterior pedal and ventral magnocellular lobes (figures 35–38). The branch to the median basal lobe includes some fibres passing through the median basal commissure to the contralateral median basal lobe. Others pass through the suprapedal commissure (figure 40). This branch to the median basal lobe breaks up in the neuropil into many fine fibres, probably afferent. No somata were filled there. This area also receives fibres from n.oph.inf. (see §3.4.7.).

The somata of the efferent fibres of n.oph.sup.post.rad.post. were stained in two areas of the suboesophageal mass of the brain: in the anterior lateral pedal lobe and in an area between the ventral magnocellular and the posterior pedal lobes. In the anterior lateral pedal lobe large, medium and a few small somata are scattered uniformly throughout (figure 39). They are arranged in an almost triangular area, very much tapered ventrally with the anterior border straight (figures 35, 36 and 38). The other set of somata lies in a region between the ventral magnocellular and the posterior pedal lobes (figures 35 and 37). They are mostly very large with a diameter of up to 90 μm. They are concentrated ventrally at the extreme medial front end of the ventral magnocellular lobe, close to the medial side of the brachial to palliovisceral lobe connective (figures 41 and 42). A further concentration occurs more dorsally and more posteriorly, close to the oesophagus (figures 37 and 40).

The ventral branch of n.oph.sup.post.rad.post. also contains afferent fibres. They divide within the posterior pedal and magnocellular lobes and some cross in the posterior magnocellular commissure.

3.4.7. *N. ophthalmicus inferior* (*figures 49–60*)

N.oph.inf. contains both afferent and efferent fibres. The latter include oculomotor fibres and presumably fibres that synapse in the inferior ophthalmic ganglion. After cobalt filling fibres have been traced to five areas.

(i) A large branch runs to the anterior lateral pedal lobe. Many somata were stained at the front and back of the lobe, with fewer between (figures 49 and 50). Large, medium and small somata were filled throughout the perikaryal layers, but never the smallest somata close to the neuropil (figures 52 and 53, plate 6). There was a concentration of many somata filled anteriorly in the dorsal part of the lobe, in a region close to the anterior chromatophore lobe (figure 54). This nerve also contains afferent fibres to the anterior lateral pedal lobe. They appear as bundles of fine fibres running tangentially to the perikaryal layer (figures 55 and 56).

(ii) A second area of filled somata occurred at the border between the ventral magnocellular and the posterior pedal lobes (figures 49 and 51), where somata were also filled from n.oph.sup.post.rad.post. The somata were concentrated in two regions, one ventrally and medially close to the medial side of the brachial to palliovisceral lobe connective, and the other far dorsally and more posteriorly close to the oesophagus (figure 60). The two groups consist mainly of medium to very large somata (up to 90 μm). They are connected by a narrow band of medium-sized somata. The neuropil into which the axons enter cannot be defined as belonging to either of the two lobes (figure 60).

(iii) Many fibres of the nerve enter the posterior pedal lobe where they spread out and are probably afferents (figure 58), some reach to the neuropil of the magnocellular lobe and perhaps the palliovisceral lobe.

(iv) A large bundle of fibres joins the brachial to palliovisceral lobe connective, a few running forwards, more backwards (figure 57). Their destination is not known.

(v) Another large set of fibres runs up to the base of the median basal lobe (figures 58 and 59) and spreads out in the area that also receives fibres from n.oph.sup.post.rad.post. These are probably afferent fibres and no somata have been seen filled in this area. Some of these fibres cross to the contralateral median basal lobe, running through both the median basal and the suprapedal commissures (figure 58).

3.5. *Projections of the statocyst nerves in the central nervous system*

All statocyst nerves contain both afferent and efferent fibres. The afferent fibres could be traced to various parts of the supra- and suboesophageal masses of the brain, on both the same and the opposite sides. Somata of the efferent fibres were found ipsilaterally in the lateral and posterior pedal lobes, and in the magnocellular lobe.

3.5.1. *N. maculae* (*figures 70–75*)

The course and distribution of the afferent and efferent fibres of this nerve have already been described in detail by Colmers (1982). His results for the most part were confirmed and added to in this study.

After centripetal cobalt filling presumed afferent fibres were seen spreading in the ipsi- and contralateral median basal lobes (figure 72, plate 8), the anterior basal lobe (figures 73 and 74), the anterior and posterior lateral pedal lobes (figure 73), the posterior pedal lobe (figures 72 and 73), and the ventral magnocellular lobe (figure 75), but none were seen in the dorsal magnocellular lobe. Some fibres may reach to the palliovisceral lobe. The statocyst to peduncle lobe tract was also well filled (figures 73 and 74), but we have not been able to follow the fibres into the peduncle lobe.

Afferent fibres in the middle pedal commissure could clearly be traced to the contralateral side, and end probably in the anterior lateral pedal lobe. Afferent fibres were also followed in the macula to contralateral median basal lobe tract (Colmers 1982). In one series, sectioned obliquely, filled macular fibres were clearly seen reaching the anterior basal lobe (figures 73 and 74). Such fibres were not seen by Colmers (1982).

A few medium and small somata of efferent fibres were filled in the anterior lateral pedal lobe (figures 70 and 71). Many small somata and some medium ones were filled in the posterior lateral pedal lobe (figures 71–73). In the ventral magnocellular lobe many small and medium and a few large somata were filled throughout all perikaryal layers (figures 71 and 75). Some of these somata lie between the magnocellular and posterior pedal lobes and some are within the latter. This is approximately the region where somata are also filled from n.oph.sup.post. rad.post. and n.oph.inf. In the dorsal magnocellular lobe numerous medium and small filled somata occur, but only in its more anterior part (figures 70 and 71).

3.5.2. *N. crista medialis and n. crista posterior (figures 61–69)*

After centripetal cobalt filling, the course and distribution of the presumed afferent fibres and the locations of the somata of the efferent fibres were identical in n.cr.med. and n.cr.post., and will be described together.

Afferent fibres of the crista nerves reach both parts of the lateral pedal lobe, and a large bundle runs up to the median basal lobe (figures 67–69, plate 7). There some fibres spread out, and a bundle of fibres crosses through the suprapedal commissure to the median basal lobe of the contralateral side (figure 69). Another set of afferent fibres joins the brachial to palliovisceral lobe connective, with more fibres running forwards and fewer backwards (figures 67 and 68). Their destinations could not be identified. Afferent fibres could also be traced through the middle pedal commissure to the contralateral lateral pedal lobe (figures 63 and 66), and some of these fibres probably belong to the efferent somata filled in that lobe on the contralateral side. Another bundle of afferent fibres runs beside the brachial to optic lobe tract and presumably ends in the peduncle lobe.

Many medium and a few small efferent somata were filled throughout the perikaryal layers of the anterior lateral pedal lobe in the region of origin of the efferent motor fibres to the eye muscles (figures 61–67). In the posterior lateral pedal lobe medium somata were filled especially ventrally close to the brachial to palliovisceral lobe connective (figure 68). Medial to the connective some large somata are filled in the posterior pedal lobe (figures 63 and 68). Many medium and small somata were filled in the ventral magnocellular lobe (figure 69) and small ones in the dorsal magnocellular lobe, but only in its more anterior part (figures 62, 65 and 69).

In addition to the ipsilateral projections a very few small efferent somata were stained contralaterally in the posterior pedal and posterior lateral pedal lobes in the innermost perikaryal layers. In the posterior pedal lobe they lie close to the medial side of the brachial to palliovisceral lobe connective.

In the preparations of the crista nerves, some stained fibres were seen in the anterior oculomotor and anterior funnel nerves. However, it is possible that these fillings were artefacts (see §2.7.).

3.6. *Origin of statocyst afferent fibres to the peduncle lobe*

One of the most important destinations of the afferent fibres from the statocyst is to the peduncle lobe and basal lobes, which are higher motor centres with some characteristics of a cerebellum. These afferents might come from the macula or the crista or from both. To settle this question we have filled the central end of the optic tract, thus filling the cell bodies of the afferents that proceed from the statocyst to the peduncle lobe.

Some afferent fibres of the statocyst nerves ascend directly to the optic tract and presumably end in the peduncle lobe (Messenger 1971; Colmers 1982; Aldred *et al.* 1983; §3.5.). Their origin in the receptor epithelia could be either in the primary sensory cells or the first-order afferent neurons of the crista or in the various types of first-order afferent neurons of the macula, which has no primary sensory cells (Colmers 1981; Budelmann *et al.* 1984). Cobalt filling from the optic tract was undertaken to trace the origin of these afferent fibres.

In the ipsilateral macula some somata of both the perimacular and intramacular first-order afferent neurons were filled (figure 76). In the ring of perimacular neurons the number of stained somata increased passing round circumferentially in a medial direction, with the greatest number of somata filled medio-dorsally close to the macula nerve (figure 76). No somata were stained in the contralateral macula.

Within the crista system the filling was less intense. However, a few faintly stained somata of primary sensory cells and first-order afferent neurons were seen in the first crista sections, close to the macula.

4. DISCUSSION

4.1. *Extraocular eye muscles*

The eyes of *Octopus* have a horizontal organization, with a horizontal slit pupil and a central strip of longer rhabdomeres oriented horizontally (Young 1960, 1963*b*). Movements of the eyes are linear forwards or backwards, and rotatory to maintain the pupil in an earth-horizontal orientation (Budelmann 1970, 1976). The animal's compensatory eye movements during active and passive head movements serve to avoid retinal image motion and are essential for its visual discrimination and learning (Young 1961). The muscles that produce the eye movements have only been briefly described (Isgrove 1909; Glockauer 1915).

In the present investigation seven eye muscles, one with a major and minor part, have been identified (figure 4, table 1). They include four strong muscles, three of which are 'recti', pulling forwards–upwards, forwards–downwards and backwards (figures 4 and 5). The fourth strong muscle, called m.obl.inf.post., is remarkable. Instead of spreading fanwise it consists of two sets of fibres crossing each other and pulling in different directions (figures 4 and 9–12). In addition there are several thin sheets of muscle fibres running more than half way round the eyeball. They are 'oblique' and produce rotations (figures 4 and 5).

Compared with vertebrates (Simpson & Graf 1981), the arrangement of the extraocular eye muscles in cephalopods is more variable and complex, ranging from seven in octopods to 14 in decapods (Glockauer 1915; Tompsett 1939). In *Octopus* a visually guided attack is nearly always made with one eye leading. On the other hand in decapods the two eyes are used together for binocular fixation of the prey. Correspondingly in decapods the anterior muscles for converging the eyes are more highly developed (Glockauer 1915; Tompsett 1939).

4.2. *Eye muscle innervation*

The seven extraocular eye muscles are innervated by seven nerves, counting the two roots (anterior and posterior) of n.oph.sup.post. as separate nerves. Most of these nerves innervate more than one muscle (table 2) and some contain fibres with other functions (table 3). The reason for the large number of nerves with overlapping innervation is not clear. It is even more strange that in decapods the 14 extraocular eye muscles are innervated by only two to six eye muscle nerves (Hillig 1912; Thore 1939; Tompsett 1939; Young 1976*b*). Presumably the differences depend on the use of the eyes for attack. They contrast with the constancy of the arrangement in vertebrates in spite of the varying use of the eyes (Simpson & Graf 1981).

In *Octopus*, all the eye muscle nerves contain fibres arising from cells in the anterior lateral pedal lobe, which is thus clearly established as the oculomotor centre.

The parts of these seven nerves that innervate the extraocular eye muscles have already been identified by their content of fibres of diameters greater than 2 μm (Young 1965). In that study n.oph.sup.post.rad.ant. was considered to be a purely chromatophore nerve. Stimulation now shows that it contains oculomotor fibres (see §3.3.). The nerve contains a few fibres of 6–10 μm (Young 1965), which may well be those responsible for the eye movements observed. Two of the eye muscle nerves (n.oph.sup.ant., n.oc.post.) contain few fibres smaller than 2 μm and their fibres are all presumed to be efferents, with the implication that there are no proprioceptors from the eye muscles (see §4.7.).

There are altogether only about 3300 nerve fibres in the bundles presumed to contain the motoneurons to the extraocular eye muscles (Young 1965). Yet there are 80000 cells in the anterior lateral pedal lobe (Young 1963*a*). There must be a very large number of efferents to the statocyst (see §4.5.) or of cells with axons intrinsic to the lobe or passing to other cerebral centres.

4.3. *Eye movements*

Electrical stimulation of the oculomotor and ophthalmic nerves consistently produced linear or rotatory eye movements, or both, in various directions (table 3). The eye movements obtained were always in accordance with and could be explained by the morphological arrangement and the points of insertion of the eye muscles that are innervated by the stimulated nerves (figures 4 and 5).

Stimulations of one particular nerve with different positions of the electrode did not always produce both kinds of eye movements together (table 3). In those nerves that innervate several muscles of predictably different functions (for example, n.oc.ant., n.oph.sup.med.) eye movements could occur in one or another direction. This was also true where one muscle has fibres oriented in different directions (for example, n.oc.post., n.oph.inf.). These varying results can be explained by stimulation of different fibre populations of one and the same nerve.

The three oblique muscles with fibres running almost half-way around the eyeball (m.obl.sup.ant., m.obl.sup.post., m.obl.inf.ant.) evidently produce the compensatory counter-rolling of the eyes that can be observed during active and passive pitching movements of the animal around transverse body axes (Budelmann 1970, 1976). The compensatory counter-rolling can be as much as 80° in either direction. Such movements must certainly cause strong pull upon the recti and antagonistic oblique eye muscles and other tissue around the eye, and it remains to be discovered whether or not there is any proprioceptive feedback to allow relaxation of these muscles (see §4.7.).

4.4. *Distribution and structure of oculomotor neurons in the anterior lateral pedal lobe*

In all seven eye muscle nerves centripetal cobalt filling showed that efferent oculomotor fibres arise from somata in the ipsilateral lateral pedal lobe of the middle suboesophageal mass of the brain. This lobe has been subdivided into an anterior and posterior part (Young 1971). The oculomotor neurons all arise in the former. The posterior lateral pedal lobe contains large neurons that control movements of the whole animal, probably including those of attack (Young 1971).

The oculomotor neurons are unipolar cells whose single main process gives rise to several collateral dendrites running parallel to the perikaryal layer (figure 34). Even finer branches of these collaterals are sometimes filled by the whole-nerve cobalt filling used in this study.

Input fibres to the lateral pedal lobe have been identified from the nerves from the statocyst (see §3.5.) but the detailed synaptic relations are not known. Other inputs come from the peduncle and basal lobes (Young 1971). Cobalt filling of the eye muscle nerves has not usually shown afferent fibres to the lateral pedal lobe. They were clear only in fillings of n.oph.inf. (see §3.4.7.). The origin and function of these fibres is not known, they may arise in the skin and might serve to monitor the position of the eye.

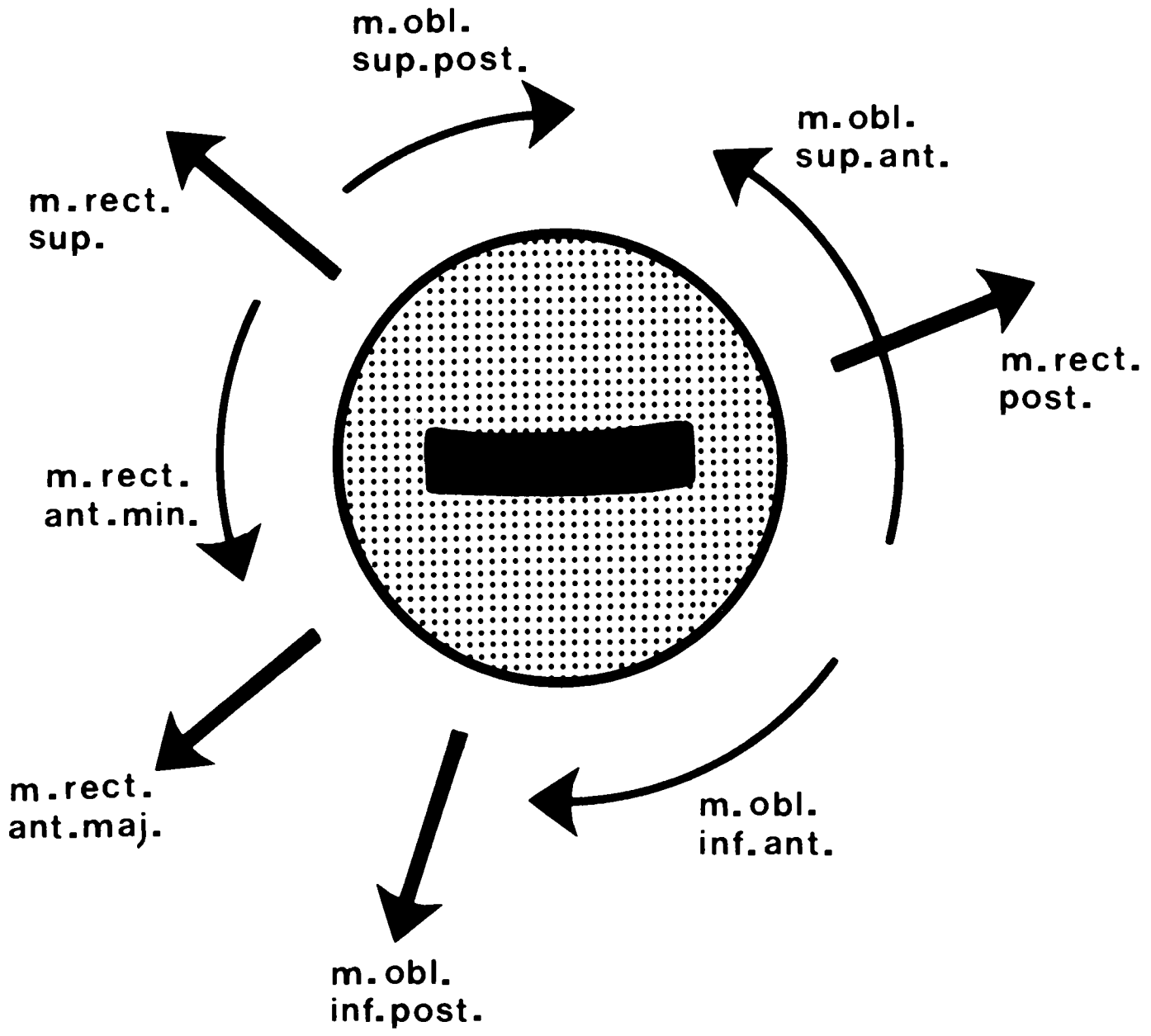

FIGURE 5. Diagram to show the eye movements of the left eye produced by the various extraocular eye muscles of *Octopus vulgaris*.

The distribution of somata of various sizes differs slightly for the various nerves. As seen from the lateral side, they are always arranged in an almost triangular area, tapered ventrally. Some can also be seen far medio-dorsally in the lobe (figure 36), close to the oesophagus. In n.oph.sup.post.rad.ant., which has only few oculomotor fibres, somata occur only in the anterior half of the anterior lateral pedal lobe. This is evidence that the cells of origin of the nerves are not distributed uniformly, but there are not enough data to discuss in detail the pattern of arrangement of the neurons of the various nerves.

More somata were filled for those nerves that innervate the stronger muscles, being most numerous in n.oc.ant., n.oc.post. and n.oph.inf. The smallest number of motoneurons was found for n.oph.sup.post.rad.ant. which has previously been considered to be a pure chromatophore nerve (Young 1965). For three nerves (n.oc.ant., n.oc.post., n.oph.inf.) there is an obvious narrow band, about 100–120 μm wide, anteriorly in the lobe, where only small somata occur. The significance of this arrangement is not clear.

The diameter of the somata varies from 10–60 μm. Medium and large somata occur mostly in the middle and outer perikaryal layers, whereas small somata were found mainly in the inner one. There, close to the neuropil, many small somata (less than 10 μm) have been described (Young 1971); these, however, have never been stained by filling any of the eye muscle nerves and therefore cannot be regarded as oculomotor neurons. They may include efferents to the statocyst nerves or be interneurons, or both (Young 1971).

4.5. *Afferent and efferent fibres of the statocyst nerves*

In the macula and crista nerves centripetal cobalt filling has demonstrated afferent as well as efferent fibre projections to various parts of the brain, both ipsilaterally and contralaterally. By using the method of degeneration, fibre projections have already been outlined for the macula and crista nerves together, mainly considered as a unity, without individual identification (Young 1971). For the macula nerve, projections have already been described in detail (Colmers 1982) and the results have been confirmed in this study for the most part, and extended. In this present account only two of the three crista nerves (n.cr.med., n.cr.post.) could be traced individually, but there is no reason to believe that the third (n.cr.ant.) differs from the other two crista nerves.

The afferent projections seen after filling of the macula and crista nerves were not identical. Macula afferent fibres appeared in the anterior and posterior lateral pedal lobes, the posterior pedal lobe, the magnocellular lobe, and the palliovisceral lobe (see §3.5.1.). All these parts are motor centres which control those muscular organs that are involved in spatial orientation and locomotion (Young 1971). Macula afferents also project to the anterior and median basal lobes and the peduncle lobe (figures 72–74) which are higher motor centres (Messenger 1967*b*; Young 1971). Macula afferents additionally project to the contralateral side into the lateral pedal and median basal lobes. Some fibres have also been seen to pass through the magnocellular commissure (Colmers 1982). For a more detailed description of the functional aspects of the various lobes see Young (1971) and Colmers (1982).

The crista afferent fibres, on the contrary, project only to the anterior and posterior lateral pedal lobes, the median basal lobe, and the peduncle lobe (see §3.5.2.). No afferent fibres could be traced to the posterior pedal, magnocellular or palliovisceral lobes which are involved in the control of rapid linear acceleration movements such as attack and escape (Young 1971). Whether these differences are correlated with the different functions of the relevant receptor systems as linear and angular accelerometers, or are due to incomplete cobalt staining, remains to be discovered.

The origin and course of the efferent fibres are the same for the macula and crista nerves. Somata of fibres reaching the statocyst were found in the anterior and posterior lateral pedal lobes, the posterior pedal lobe, and in the dorsal and ventral magnocellular lobes (see §3.5.). Additionally, a very few small somata were filled contralaterally in the posterior lateral pedal and posterior pedal lobes.

The number of efferent fibres in each of the statocyst nerves is as much as 70% of all fibres in the nerve (Budelmann & Wolff 1976; Colmers 1977; Budelmann *et al.* 1984). This is very high compared with the vertebrate vestibular system where it is only a small percentage. They innervate all the various cell types in the macula and crista (Budelmann 1977; Colmers 1977, 1981; Budelmann *et al.* 1984). The function of the efferent innervation is not yet satisfactorily understood.

4.6. *Statocyst–oculomotor system*

The present account shows that in *Octopus* there is a very well developed system for the control of eye movements (figure 6). This system is based on an oculomotor centre in the anterior lateral pedal lobe, with motoneurons that send their efferent information through seven nerves to the eye muscles. This oculomotor centre receives direct afferent input about movement in space from the gravity and angular acceleration receptor systems of the statocysts, and additionally from the eyes. The visual input, however, does not come directly from the optic lobes but through four parts of the brain: the peduncle lobe, the anterior and median basal lobes, and the magnocellular lobe (Young 1971; Saidel 1982). These lobes in turn send direct return pathways to the optic lobe (Young 1971; Saidel 1982), and some are interconnected with each other (figure 6).

On the other hand, the peduncle, anterior and median basal, and magnocellular lobes all receive direct input from the equilibrium receptor systems of the statocysts and could thus be centres of direct integration of visual and statocyst information (figure 6). They all together may

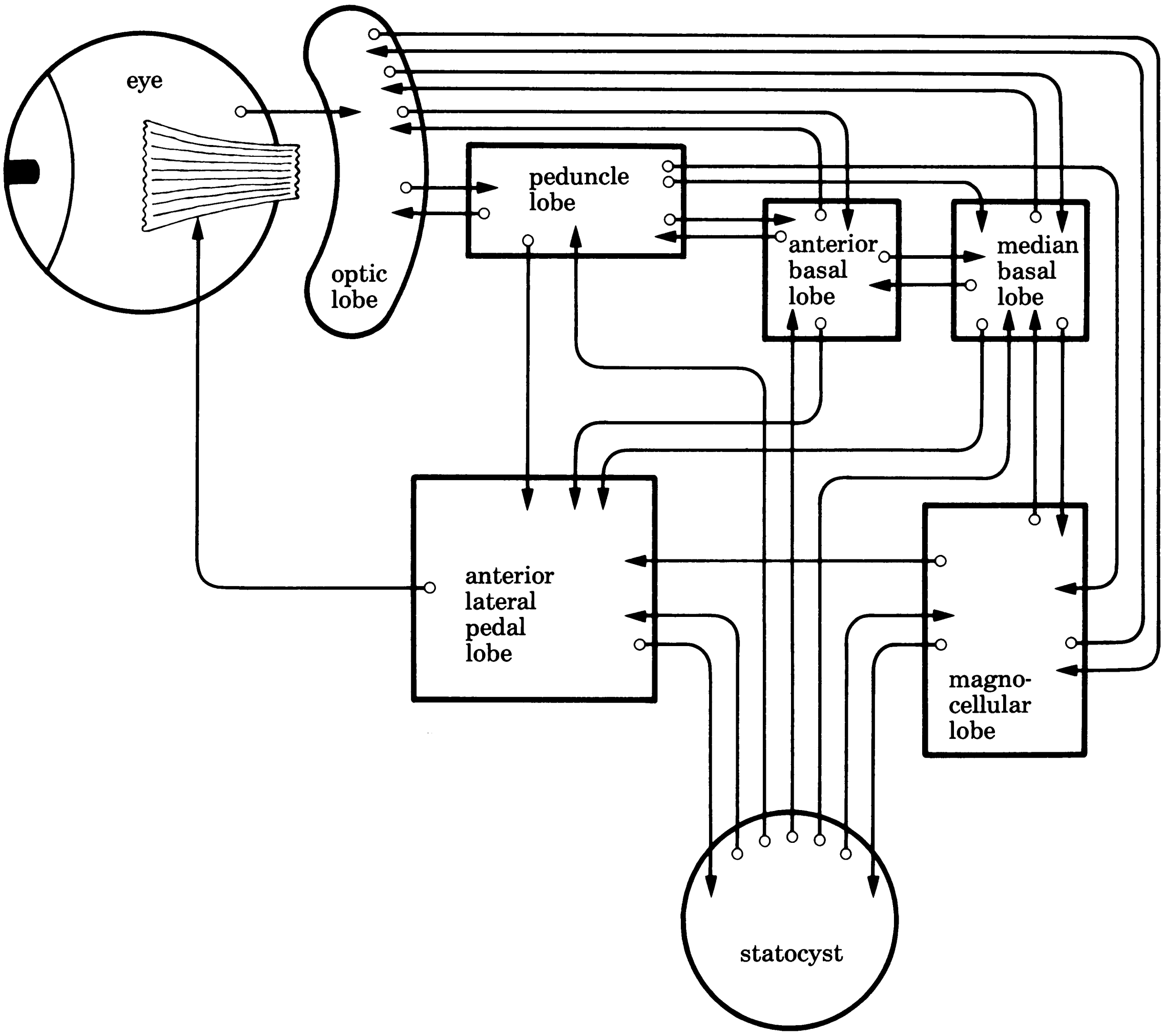

FIGURE 6. Schematic presentation of the statocyst-oculomotor system and the associated pathways in the central nervous system of *Octopus vulgaris*. Open circles indicate the origin of the pathways and arrowheads their termination. A number of pathways are taken from Young (1971) and Saidel (1982).

play a role similar to the various parts of the vertebrate cerebellum (see Palay & Chan-Palay 1982). They include systems of very fine parallel fibres (Messenger 1967*a*, 1971; Hobbs & Young 1973; Young 1976*b*; Woodhams 1977). Various motor defects are seen after extirpation of them (Messenger 1967*a*). For comparison with the *Loligo* statocyst–oculomotor system see Young (1976*a*) and Messenger (1979).

In *Octopus*, the oculomotor neurons of the anterior lateral pedal lobe thus get their statocyst input via two pathways (figure 7): directly by fibres of the statocyst nerves and indirectly via

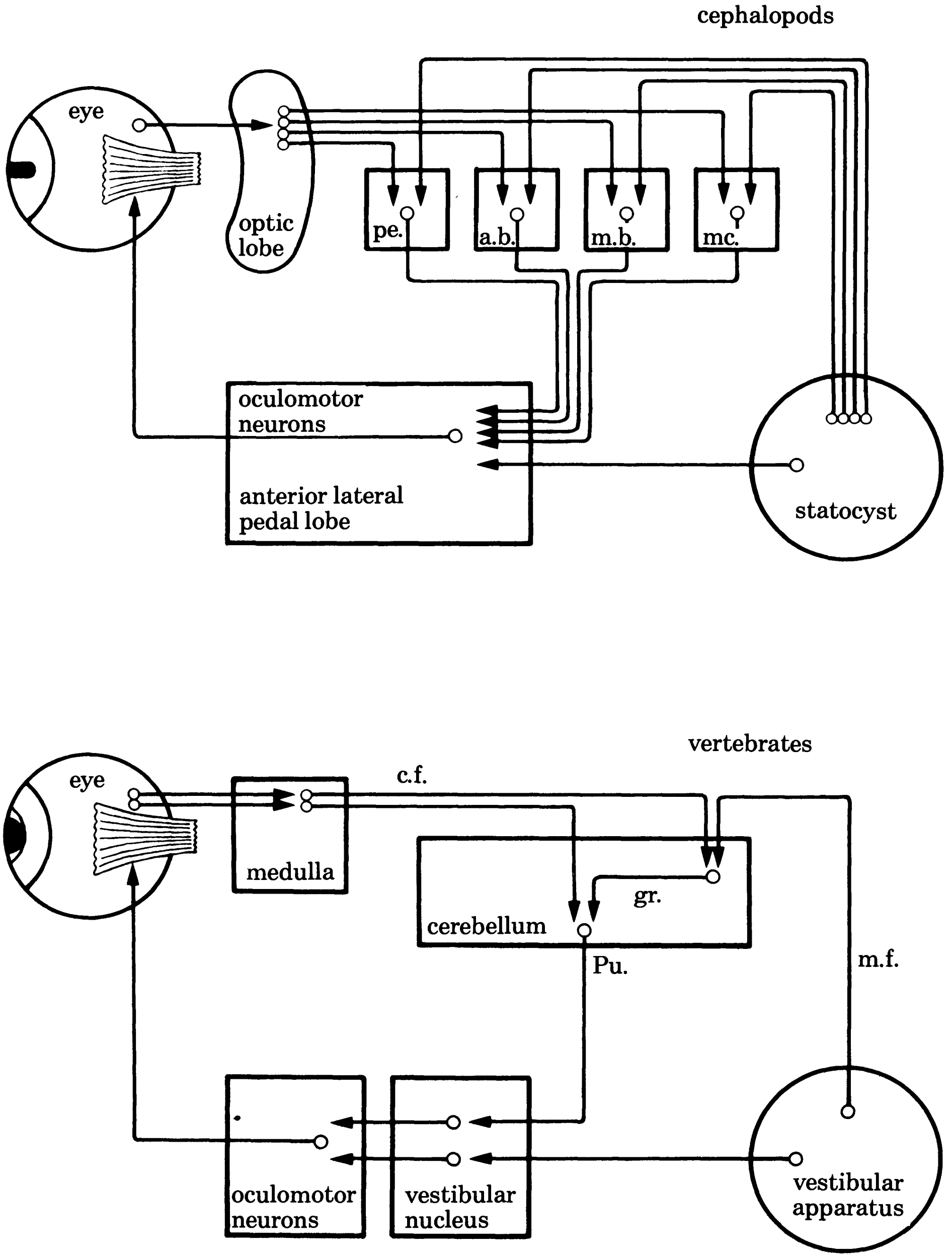

FIGURE 7. Similarities in brain pathways of the oculomotor control system in cephalopods and vertebrates. Simplified diagram to show the direct and indirect pathways from the equilibrium receptor organs to the motoneurons of the eyes in the statocyst-oculomotor system of cephalopods (*Octopus vulgaris*) and the vestibulo-ocular system of vertebrates. a.b., anterior basal lobe; c.f., climbing fibres; gr., granule cells; m.b., median basal lobe; mc., magnocellular lobe; m.f., mossy fibres; pe., pedal lobe; Pu., Purkinje cells.

higher integration centres where visual information about movement (and perhaps about position of the eyes) is integrated with that coming from the statocysts. The statocyst receptors in turn, are controlled by information from the oculomotor centre and the magnocellular lobe. Thus, the statocyst–oculomotor system of *Octopus* shows a high degree of convergence with the vestibulo-ocular system of vertebrates (figure 7; compare Precht 1978; Cohen 1981; Palay & Chan-Palay 1982).

4.7. *Afferent fibres in the eye muscle nerves*

Bundles of fibres presumed to be afferent were seen by light microscopy in four nerves (Young 1965). Two of these (n.oph.sup.post.rad.post. and n.oph.inf.) are ganglionated and have branches to the skin around the eyes. They were shown by cobalt filling to have afferent fibres ending in the ventral part of the median basal lobe. These fibres degenerate in the brain after section peripherally and are afferents from the skin of the post-ocular papilla (Young 1971). Some of the afferent fibres in n.op.inf. appear to end in the anterior lateral pedal lobe (§3.4.7.). Those fibres presumed to be afferent in n.oph.sup.med. and n.oc.ant. (Young 1965) could not be identified by cobalt filling. No signs of filling of afferent fibres were seen in any of the other eye muscle nerves.

Contrary to Young (1965), at the level of electron microscopy fibres smaller than 2 μm were found in all eye muscle nerves, but in n.oph.sup.ant. and n.oc.post. only 150 and 380 fibres respectively; (T. Plän & B. U. Budelmann, unpublished observations). It is still not certain that the small fibres of those nerves in which cobalt fillings did not show afferent fibres, are all efferent. Some of them may be afferent, but have not been filled with Co^{2+} ions because of the limits of the technique applied (see §2.7.). However the small number of fibres in n.oph.sup.ant. and n.oc.post., and their mostly large size, suggest that these two nerves are purely efferent. It is possible that some of the small fibres in other nerves passing to the skin provide 'proprioceptive' information about the position of the eye. No proprioceptors have been seen in the eye muscles themselves.

4.8. *Chromatophore fibres in the oculomotor and ophthalmic nerves*

Cobalt filling showed fibres with somata in the anterior chromatophore lobe in three nerves. Stimulation of two of these produced expansion of the chromatophores of the iris (n.oph.sup.med. and n.oph.sup.post.rad.ant.; table 3). Froesch (1973) noted pallor of the iris after sectioning the first of these but not the second (though he confirmed that this nerve innervates the skin of the back of the head). Froesch (1973) also showed that n.oc.ant. innervates chromatophores in the skin below the eyes and cobalt filling of this nerve showed somata in the anterior chromatophore lobe (figures 26 and 27). He did not mention any area of pallor following the section of n.oph.inf., which has been supposed to contain chromatophore fibres (Young 1965), and we found neither expansion of chromatophores on the iris on stimulating this nerve (table 3) nor filling of cells in the anterior chromatophore lobe.

4.9. *Control of pupil diameter*

Stimulation of three of the nerves produced changes in the pupil, two causing constriction, one dilation (table 3). The nerves containing constrictor fibres (n.oph.sup.post.rad.post. and n.oph.inf.) both carry ganglia. The axons of the cells of these ganglia probably include the fibres that control the diameter of the pupil. Filling of these nerves with cobalt peripheral to the ganglia and towards the muscles produced staining of branches that proceed to the muscles attached to the iris (figures 23 and 77). These branches were not stained in four preparations where the nerves had been filled central to the ganglia.

Cobalt filling of these ganglionated nerves central to the ganglia and towards the brain showed that they contain fibres arising from large somata in a region between the posterior pedal and ventral magnocellular lobes (figures 35, 37, 38, 40–42, 49–51 and 60). This is therefore presumably an area involved in control of the pupil. It receives many fibres direct from the optic lobes (Young 1971; Saidel 1982).

Previous work on the control of the pupil has produced conflicting results. Hensen (1865) and Alexandrowicz (1927) have described two rings of sphincter muscles in the iris. Magnus (1902) showed that there are nerve fibres that produce dilation but his identification of the nerves must be questioned (see also Weel & Thore 1936). Pupilloconstrictor fibres have been considered to pass in the optic tract (Weel & Thore 1936). The present experiments show the existence of fibres that produce dilation in n.oph.sup.med. (table 3). Filling of this nerve centripetally showed somata only in the anterior lateral pedal and anterior chromatophore lobes (figures 32 and 33). There was no evidence of any connection with the presumed pupil control centre between the posterior pedal and ventral magnocellular lobes. The nature of the dilator system of the pupil thus remains doubtful. It may lie in the anterior lateral pedal lobe or possibly depend on an inhibition of the constrictor fibres.

This work was supported by grants of the Deutsche Forschungsgemeinschaft (Bu 404/2 and SFB 4). The authors would like to thank the Director and staff of the Zoological Station in Naples, Italy, for their hospitality and continuous help, T. Plän for many helpful discussions, and M. Staudigl for excellent technical assistance.

REFERENCES

Alexandrowicz, J. S. 1927 Contribution a l'étude des muscles, des nerfs et du méchanisme de l'accommodation de l'œil des céphalopodes. *Archs. Zool. exp. gén.* **66**, 71–134.

Aldred, R. G., Nixon, M. & Young, J. Z. 1983 *Cirrothauma murrayi* Chun, a finned octopod. *Phil. Trans. R. Soc. Lond.* B **301**, 1–54.

Budelmann, B. U. 1970 Die Arbeitsweise der Statolithenorgane von *Octopus vulgaris*. *Z. vergl. Physiol.* **70**, 278–312.

Budelmann, B. U. 1975 Gravity receptor function in cephalopods with particular reference to *Sepia officinalis*. *Fortschr. Zool.* **23**, 84–96.

Budelmann, B. U. 1976 Equilibrium receptor systems in molluscs. In *Structure and function of proprioceptors in the invertebrates* (ed. P. J. Mill), pp. 529–566. London: Chapman & Hall.

Budelmann, B. U. 1977 Structure and function of the angular acceleration receptor systems in the statocysts of cephalopods. *Symp. zool. Soc. Lond.* **38**, 309–324.

Budelmann, B. U. & Bonn, U. 1982 Histochemical evidence for catecholamines as neurotransmitters in the statocyst of *Octopus vulgaris*. *Cell Tissue Res.* **227**, 475–483.

Budelmann, B. U. & Thies, G. 1977 Secondary sensory cells in the gravity receptor system of the statocyst of *Octopus vulgaris*. *Cell Tissue Res.* **185**, 491–503.

Budelmann, B. U. & Wolff, H. G. 1973 Gravity response from angular acceleration receptors in *Octopus vulgaris*. *J. comp. Physiol.* **85**, 283–290.

Budelmann, B. U. & Wolff, H. G. 1976 Mapping of neurons in the gravity receptor system of the *Octopus* statocyst by iontophoretic cobalt staining. *Cell Tissue Res.* **171**, 403–406.

Budelmann, B. U., Sachse, M. & Staudigl, M. 1984 The angular acceleration receptor system of *Octopus vulgaris*: morphometry, ultrastructure, and neuronal and synaptic organization. (In preparation.)

Cohen, B. (ed.) 1981 *Vestibular and oculomotor physiology: international meeting of the Bárány Society.* (*Ann. N.Y. Acad. Sci.* **374**). New York: The New York Academy of Sciences.

Collewijn, H. 1970 Oculomotor reactions in the cuttlefish *Sepia officinalis*. *J. exp. Biol.* **52**, 369–384.

Colmers, W. F. 1977 Neuronal and synaptic organization in the gravity receptor system of the statocyst of *Octopus vulgaris*. *Cell Tissue Res.* **185**, 491–503.

Colmers, W. F. 1981 Afferent synaptic connections between hair cells and the somata of intramacular neurons in the gravity receptor system of the statocyst of *Octopus vulgaris J. comp. Neurol.* **197**, 385–394.

Colmers, W. F. 1982 The central afferent and efferent organization of the gravity receptor system of the statocyst of *Octopus vulgaris. Neuroscience* **7** (2), 461–476.

Dijkgraaf, S. 1961 The statocyst of *Octopus vulgaris* as a rotation receptor. *Pubbl. Staz. zool. Napoli* **32**, 64–87.

Froesch, D. 1973 Projection of chromatophore nerves on the body surface of *Octopus vulgaris. Marine Biol.* **19**, 153–155.

Glockauer, A. 1915 Zur Anatomie und Histologie des Cephalopodenauges. *Z. wiss. Zool.* **113**, 325–360.

Hartline, P. H., Hurley, A. C. & Lange, G. D. 1979 Eye stabilization by statocyst mediated oculomotor reflex in *Nautilus. J. comp. Physiol.* **132**, 117–126.

Hensen, V. 1865 Über das Auge einiger Cephalopoden. *Z. wiss. Zool.* **15**, 155–242.

Hillig, R. 1912 Das Nervensystem von *Sepia officinalis. Z. wiss. Zool.* **101**, 736–806.

Hobbs, M. J. & Young, J. Z. 1973 A cephalopod cerebellum. *Brain Res.* **55**, 424–430.

Isgrove, A. 1909 *Eledone. L.M.B.C. Mem. typ. Br. mar. Pl. Anim.* **18**, 1–106.

Magnus, R. 1902 Die Pupillarreaction der Octopoden. *Pflüg. Arch. ges. Physiol.* **92**, 623–643.

Messenger, J. B. 1967*a* The peduncle lobe: a visuo-motor centre in *Octopus. Proc. R. Soc. Lond.* B **167**, 225–251.

Messenger, J. B. 1967*b* The effects on locomotion of lesions to the visuo-motor system in *Octopus. Proc. R. Soc. Lond.* B **167**, 252–281.

Messenger, J. B. 1970 Optomotor responses and nystagmus in intact, blinded and statocystless cuttlefish (*Sepia officinalis*). *J. exp. Biol.* **53**, 789–796.

Messenger, J. B. 1971 The optic tract lobes. In *The anatomy of the nervous system of Octopus vulgaris* (ed. J. Z. Young), pp. 481–506. Oxford: Clarendon Press.

Messenger, J. B. 1977 Evidence that *Octopus* is colour blind. *J. exp. Biol.* **70**, 49–55.

Messenger, J. B. 1979 The nervous system of *Loligo*. IV. The peduncle and olfactory lobes. *Phil. Trans. R. Soc. Lond.* B **285**, 275–309.

Palay, S. L. & Chan-Palay, V. (eds). 1982 *The cerebellum: new vistas.* (*Exp. Brain Res.* Suppl. 6). Berlin, Heidelberg, New York: Springer.

Pfefferkorn, A. 1915 Das Nervensystem der Octopoden. *Z. wiss. Zool.* **114**, 425–453.

Precht, W. 1978 *Neuronal operations in the vestibular system.* Berlin, Heidelberg, New York: Springer.

Saidel, W. M. 1982 Connections of the *Octopus* optic lobe: an HRP study. *J. comp. Neurol.* **206**, 346–358.

Simpson, J. I. & Graf, W. 1981 Eye-muscle geometry and compensatory eye movements in lateral-eyed and frontal-eyed animals. *Ann. N.Y. Acad. Sci.* **374**, 20–30.

Strausfeld, N. J. & Obermayer, M. 1976 Resolution of intraneuronal and transynaptic migration of cobalt in the insect visual and central nervous systems. *J. comp. Physiol.* **110**, 1–12.

Thore, S. 1939 Beiträge zur Kenntnis der vergleichenden Anatomie des zentralen Nervensystems der dibranchiaten Cephalopoden. *Pubbl. Staz. zool. Napoli* **17**, 313–506.

Tompsett, D. H. 1939 *Sepia. L.M.B.C. Mem. typ. Br. mar. Pl. Anim.* **32**, 1–184.

Tyrer, N. M. & Bell, E. M. 1974 The intensification of cobalt-filled neurone profiles using a modification of Timm's sulphide-silver method. *Brain Res.* **73**, 151–155.

Weel, P. B. van & Thore, S. 1936 Über die Pupillarreaktion von *Octopus vulgaris. Z. vergl. Physiol.* **23**, 26–33.

Wells, M. J. 1960 Proprioception and visual discrimination of orientation in *Octopus. J. exp. Biol.* **37**, 489–499.

Woodhams, P. L. 1977 The ultrastructure of a cerebellar analogue in *Octopus. J. comp. Neurol.* **174**, 329–346.

Young, J. Z. 1960 The visual system of *Octopus*. I. Regularities in the retina and optic lobes of *Octopus* in relation to form discrimination. *Nature, Lond.* **186**, 836–839.

Young, J. Z. 1961 Learning and discrimination in the octopus. *Biol. Rev.* **36**, 32–96.

Young, J. Z. 1963*a* The number and sizes of nerve cells in *Octopus. Proc. zool. Soc. Lond.* **140**, 229–254.

Young, J. Z. 1963*b* Light and dark adaptation in the eyes of some cephalopods. *Proc. zool. Soc. Lond.* **140**, 255–270.

Young, J. Z. 1965 The diameters of the fibres of the peripheral nerves of *Octopus. Proc. R. Soc. Lond.* B **162**, 47–79.

Young, J. Z. 1971 *The anatomy of the nervous system of Octopus vulgaris.* Oxford: Clarendon Press.

Young, J. Z. 1976*a* The nervous system of *Loligo*. II. Suboesophageal centres. *Phil. Trans. R. Soc. Lond.* B **274**, 101–167.

Young, J. Z. 1976*b* The 'cerebellum' and the control of eye movements in cephalopods. *Nature, Lond.* **264**, 572–574.

ABBREVIATIONS

art.ir.	artery of the iris
art.oph.	ophthalmic artery
art.wb.	artery of the white body
b.a.	anterior basal lobe
b.int.	interbasal lobe
b.med.	median basal lobe
c.opt.	optic commissure
c.pe.med.	middle pedal commissure
c.pe.sup.	suprapedal commissure
ch.a.	anterior chromatophore lobe
con.br.pv.	brachial to palliovisceral lobe connective
ir.	iris
mag.	magnocellular lobe
mag.d.	dorsal magnocellular lobe
mag.ven.	ventral magnocellular lobe
m.dil.ir.	dilator muscle of the iris
m.obl.inf.ant.	anterior inferior oblique muscle
m.obl.inf.post.	posterior inferior oblique muscle
m.obl.sup.ant.	anterior superior oblique muscle
m.obl.sup.post.	posterior superior oblique muscle
m.rect.ant.	anterior rectus muscle
m.rect.ant.maj.	major anterior rectus muscle
m.rect.ant.min.	minor anterior rectus muscle
m.rect.post.	posterior rectus muscle
m.rect.sup.	superior rectus muscle
n.cr.med.	middle crista nerve
n.cr.post.	posterior crista nerve
n.fun.a.	anterior funnel nerve
n.ir.	iris nerve
n.mac.	macula nerve
n.oc.ant.	anterior oculomotor nerve
n.oc.post.	posterior oculomotor nerve
n.oph.inf.	inferior ophthalmic nerve
n.oph.sup.ant.	anterior superior ophthalmic nerve
n.oph.sup.med.	medial superior ophthalmic nerve
n.oph.sup.post.	posterior superior ophthalmic nerve
n.oph.sup.post.rad.ant.	anterior root of the posterior superior ophthalmic nerve
n.oph.sup.post.rad.post.	posterior root of the posterior superior ophthalmic nerve
n.sk.	skin nerve
n.st.	statocyst nerve
oes.	oesophagus
pe.l.	lateral pedal lobe
pe.l.a.	anterior lateral pedal lobe
pe.l.p.	posterior lateral pedal lobe
pe.p.	posterior pedal lobe
tr.br.opt.	brachial to optic lobe tract
tr.ch.int.	interchromatophore lobe tract
tr.opt.	optic tract
tr.st.b.med.	statocyst to median basal lobe tract
tr.st.ped.	statocyst to peduncle lobe tract

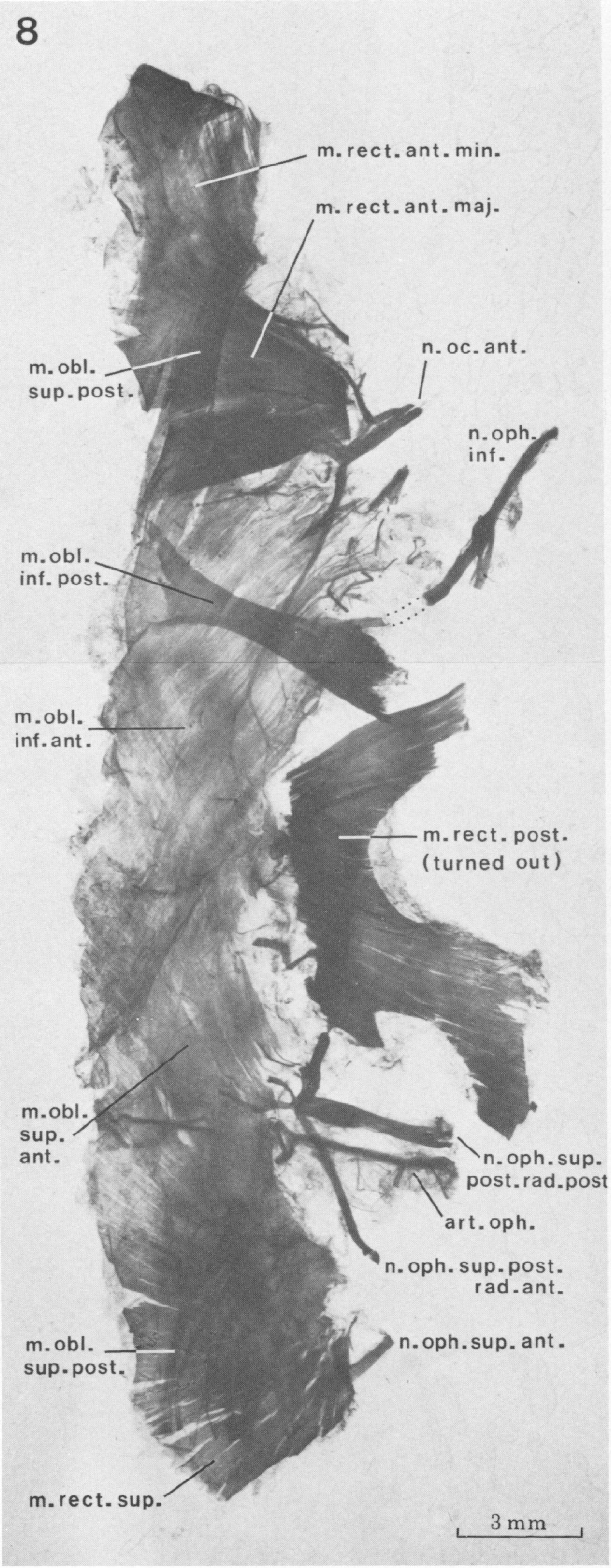

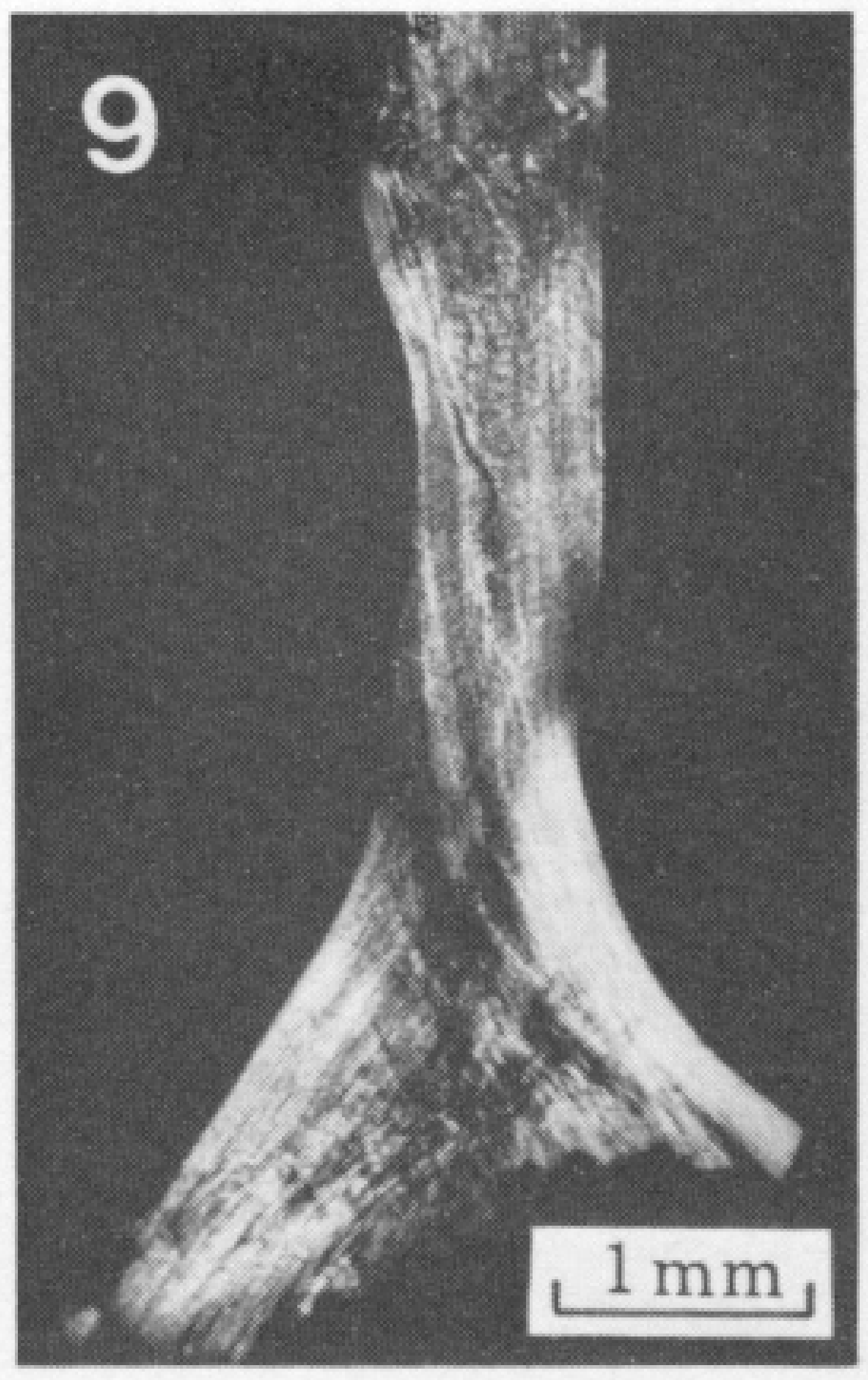

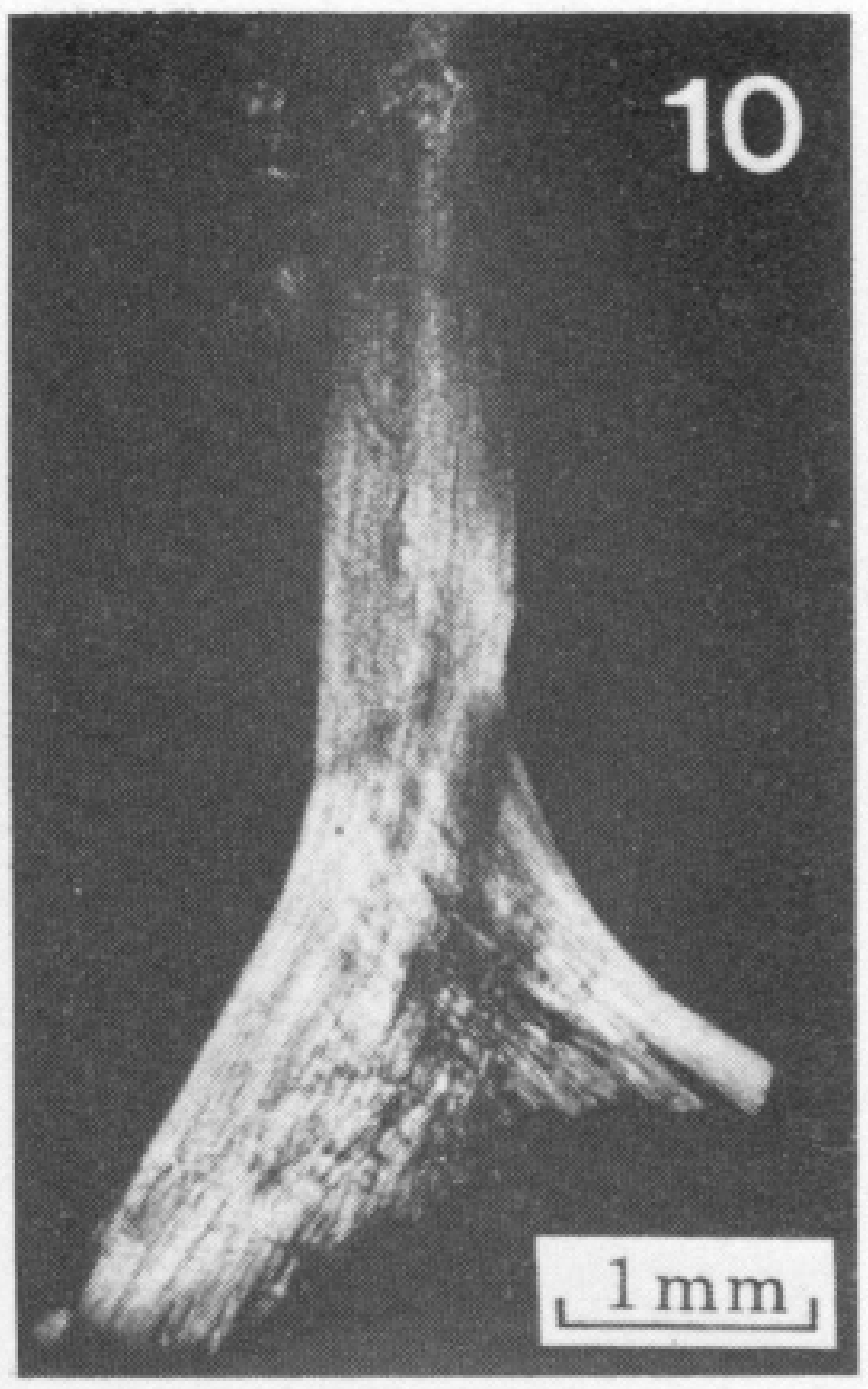

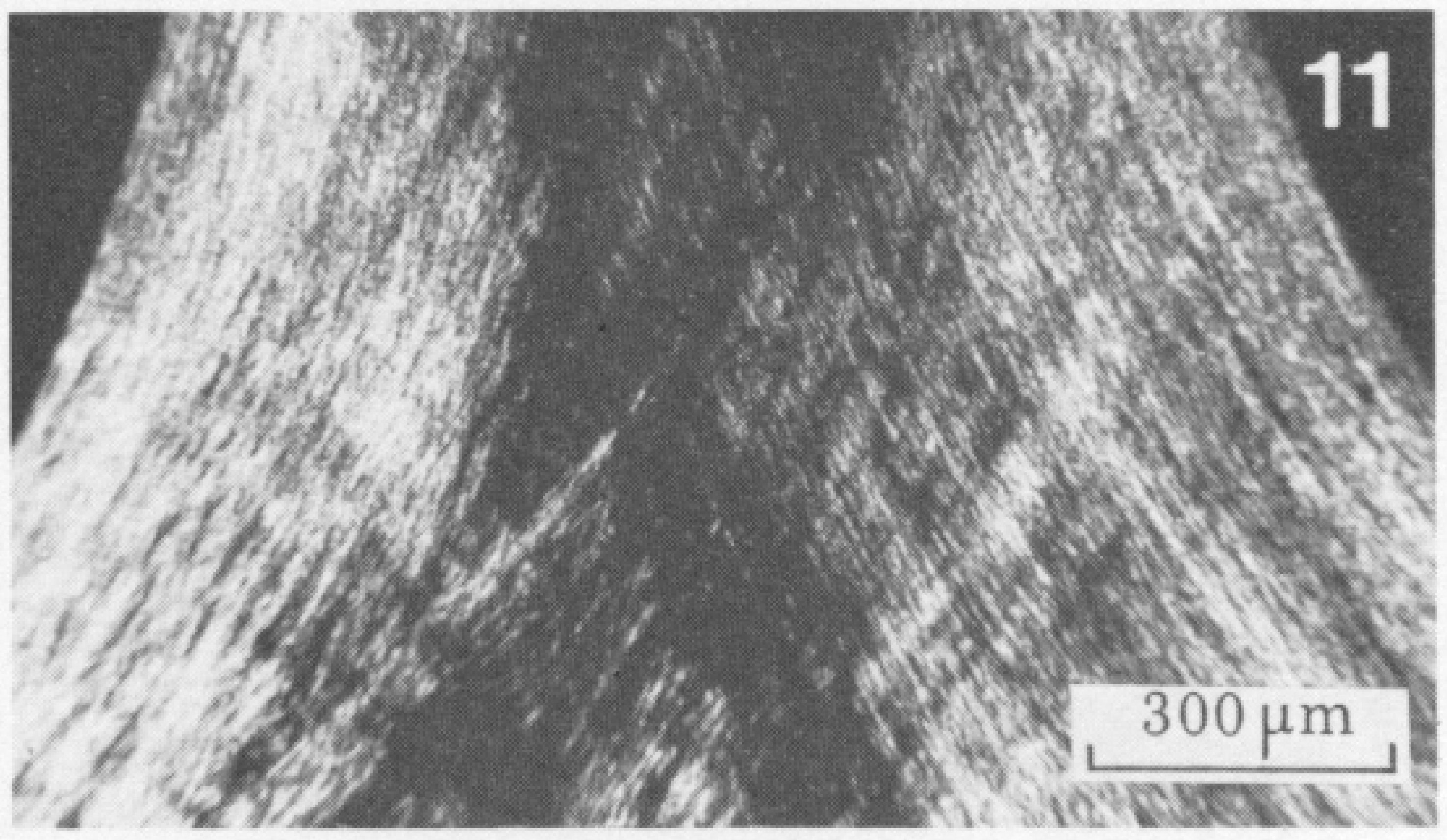

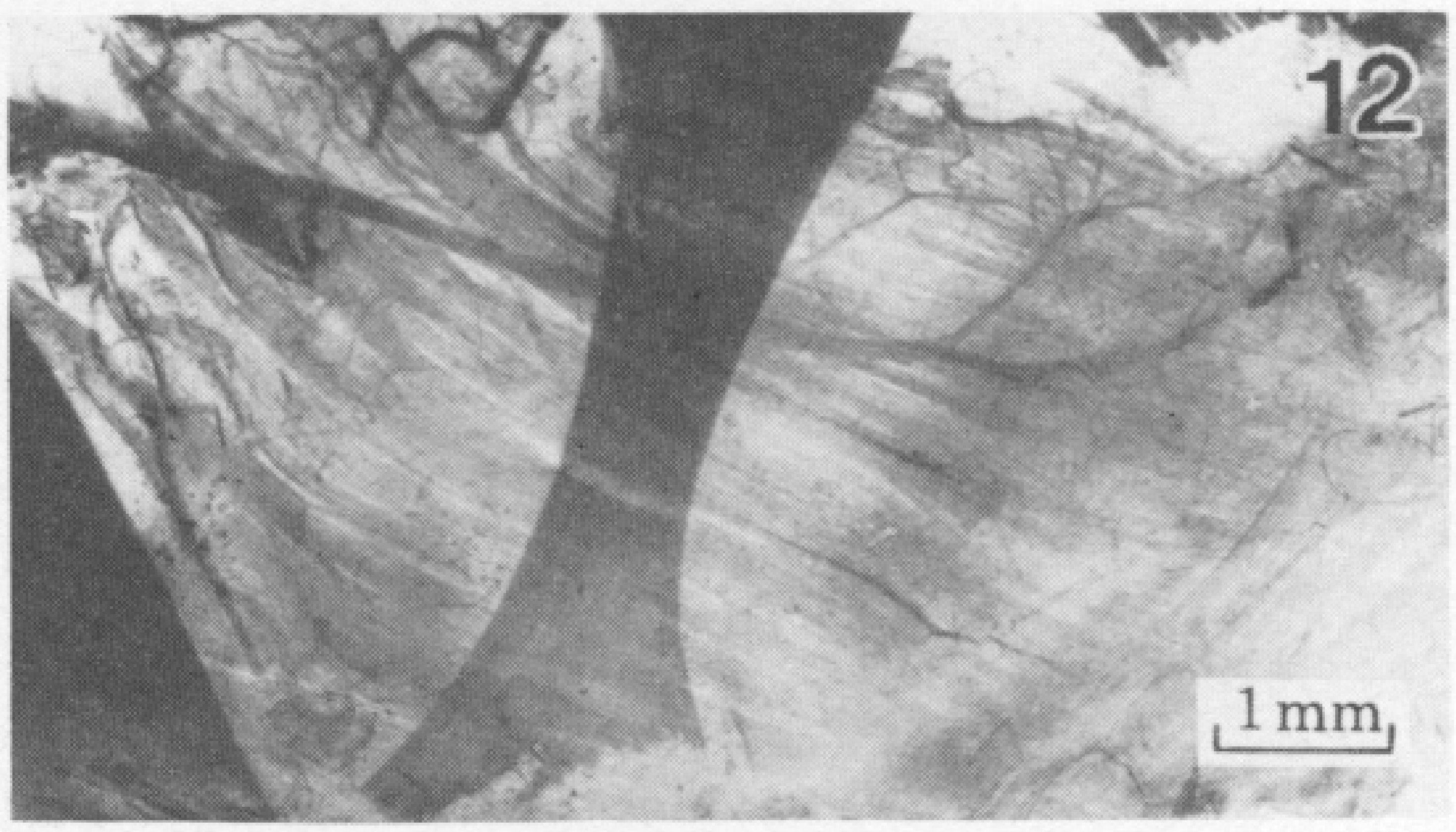

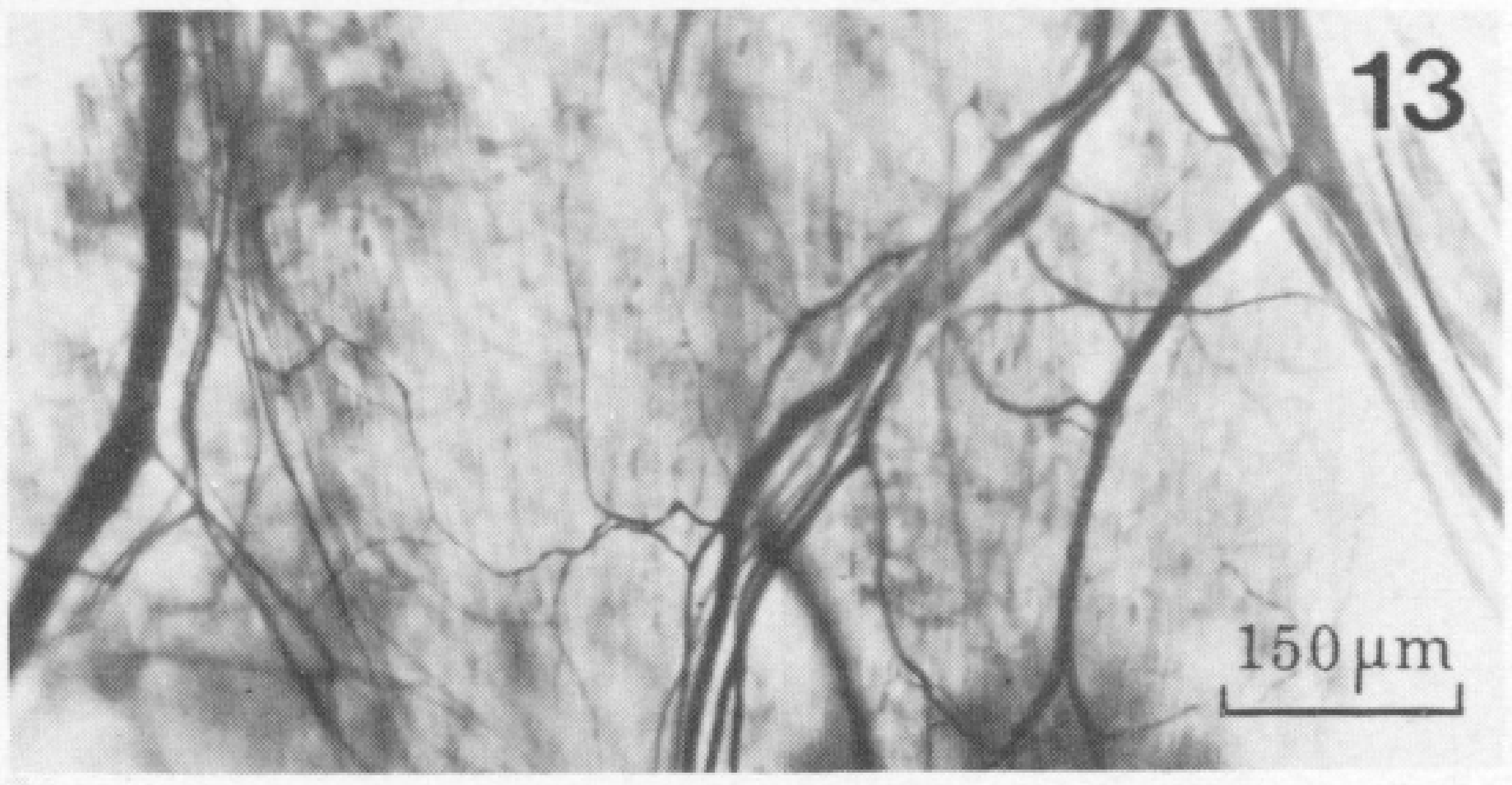

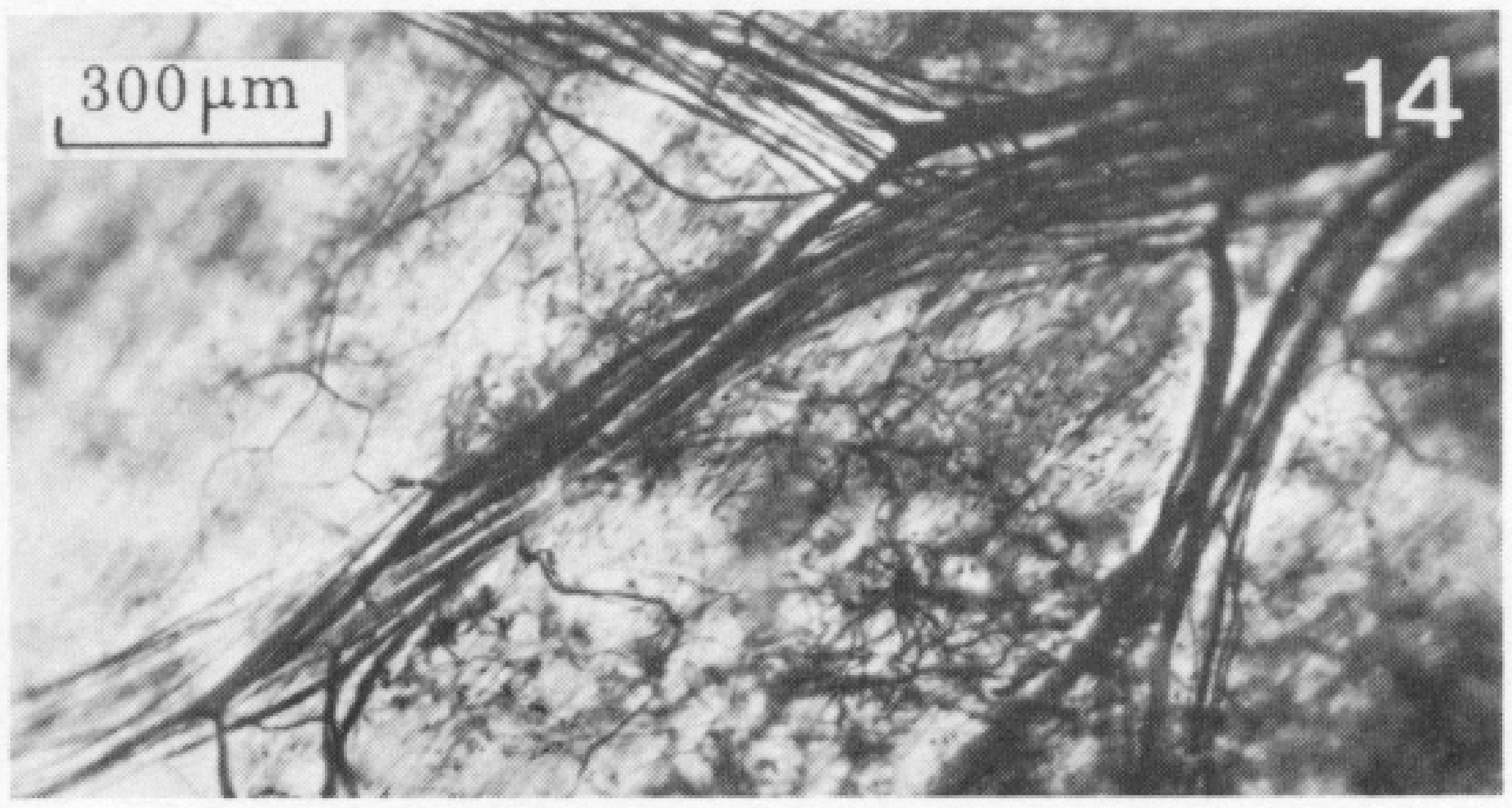

FIGURES 8–14. For description see opposite.

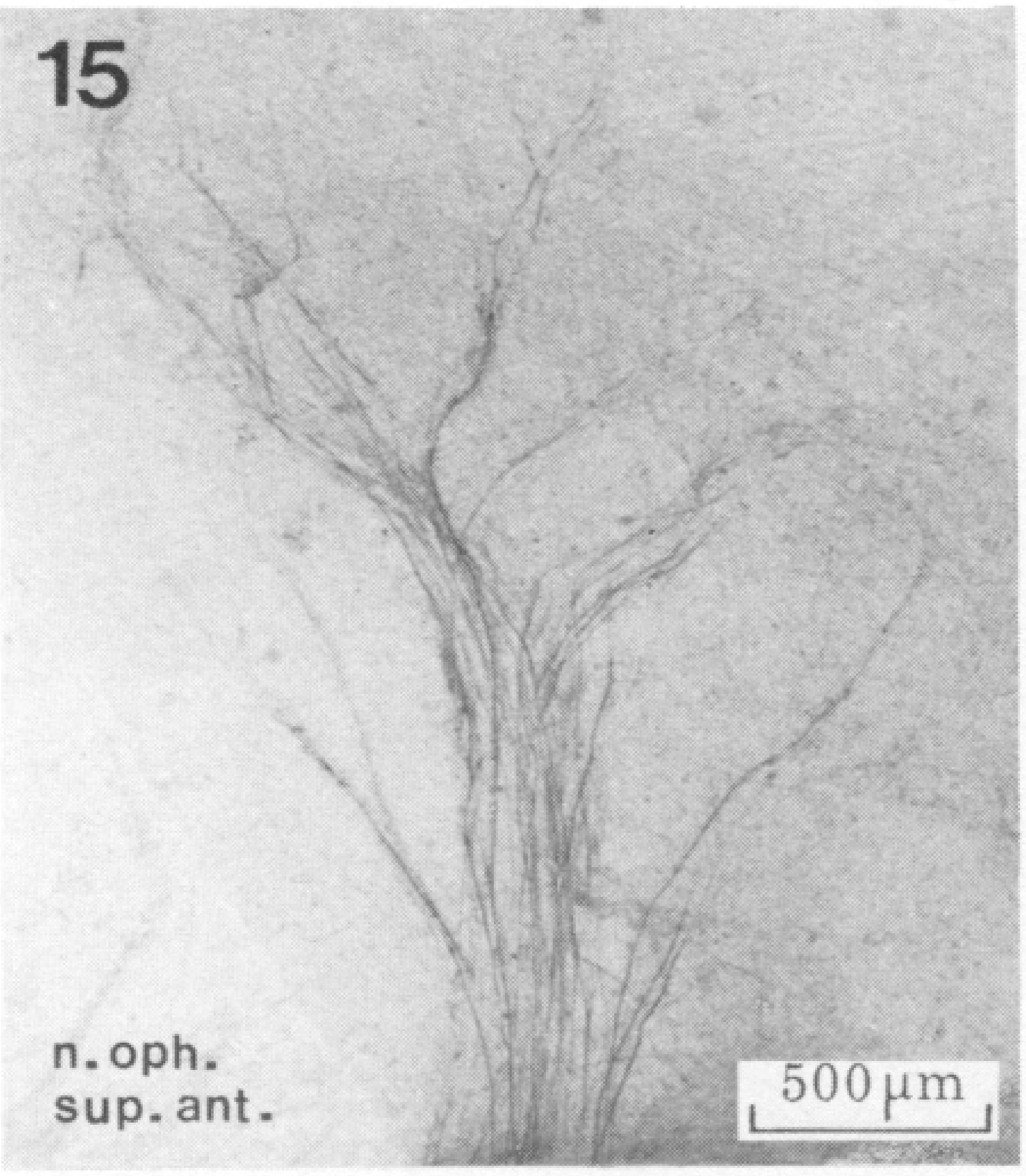

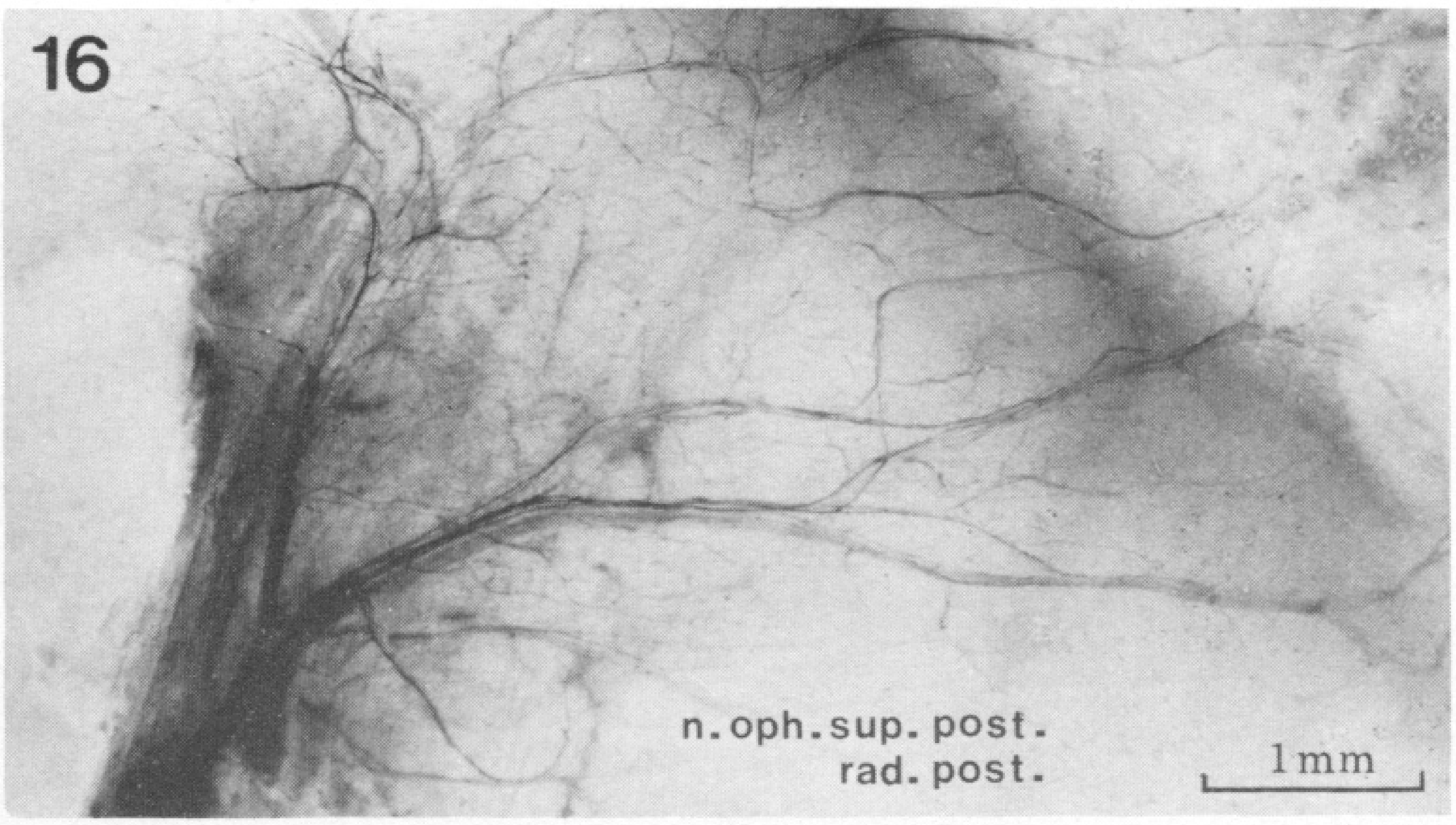

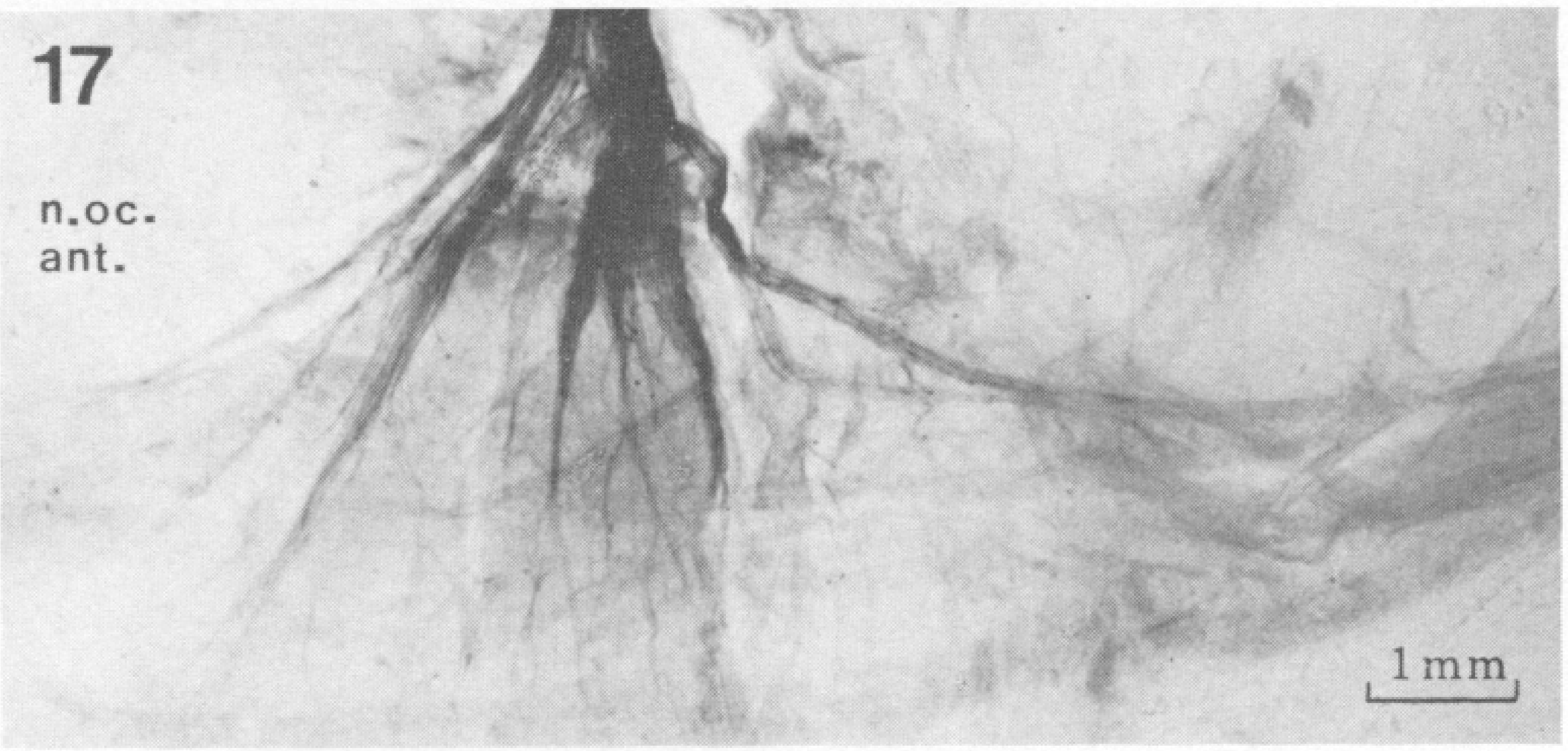

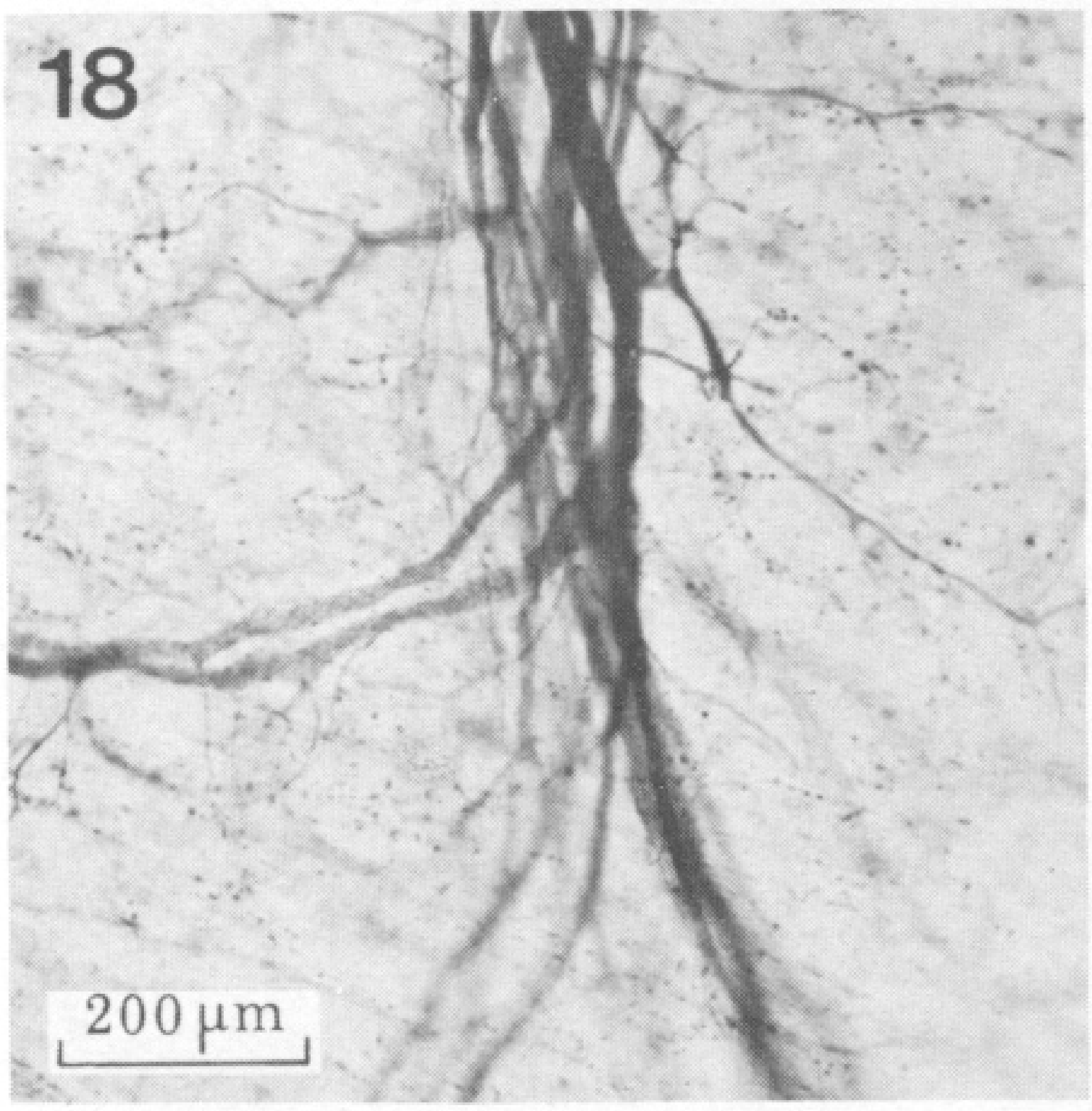

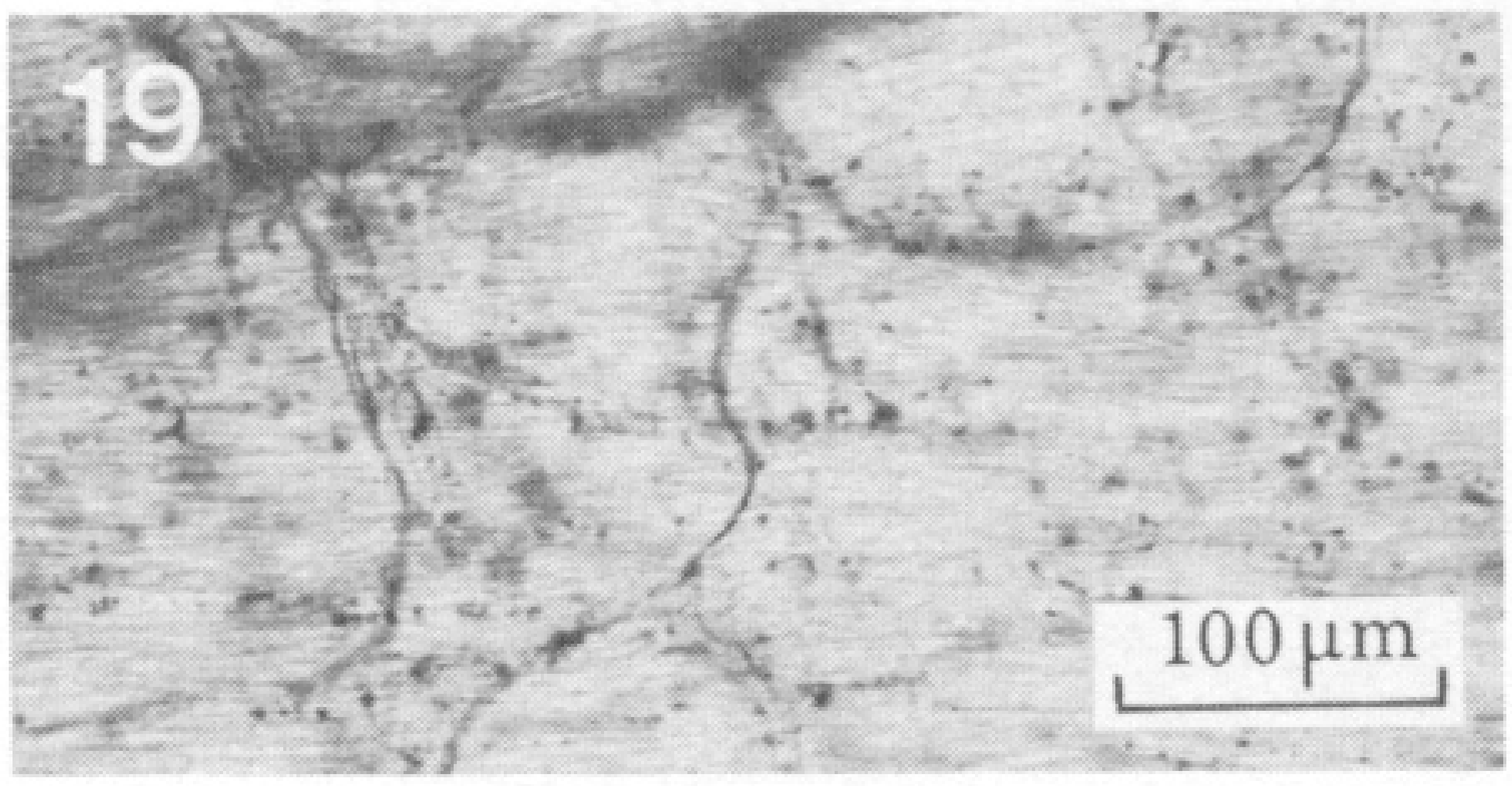

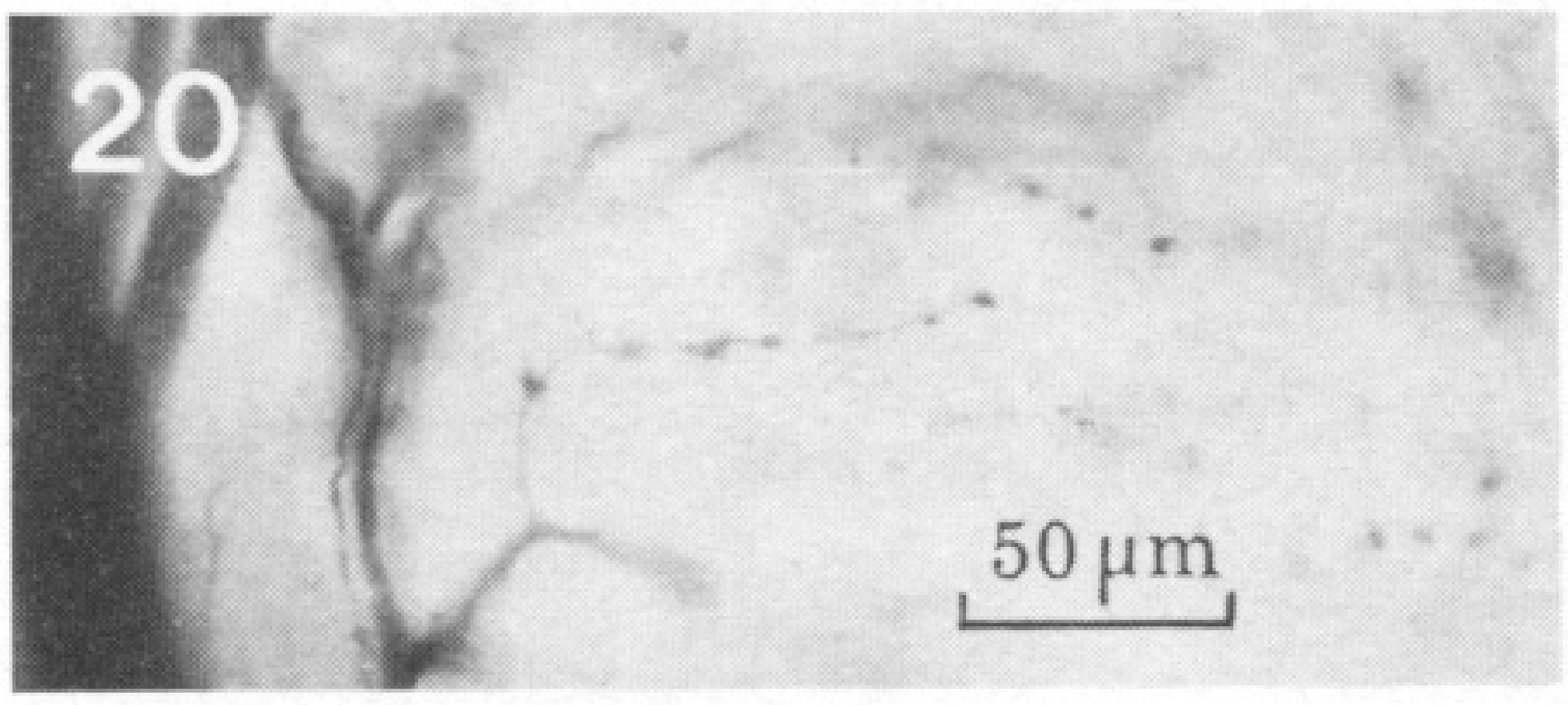

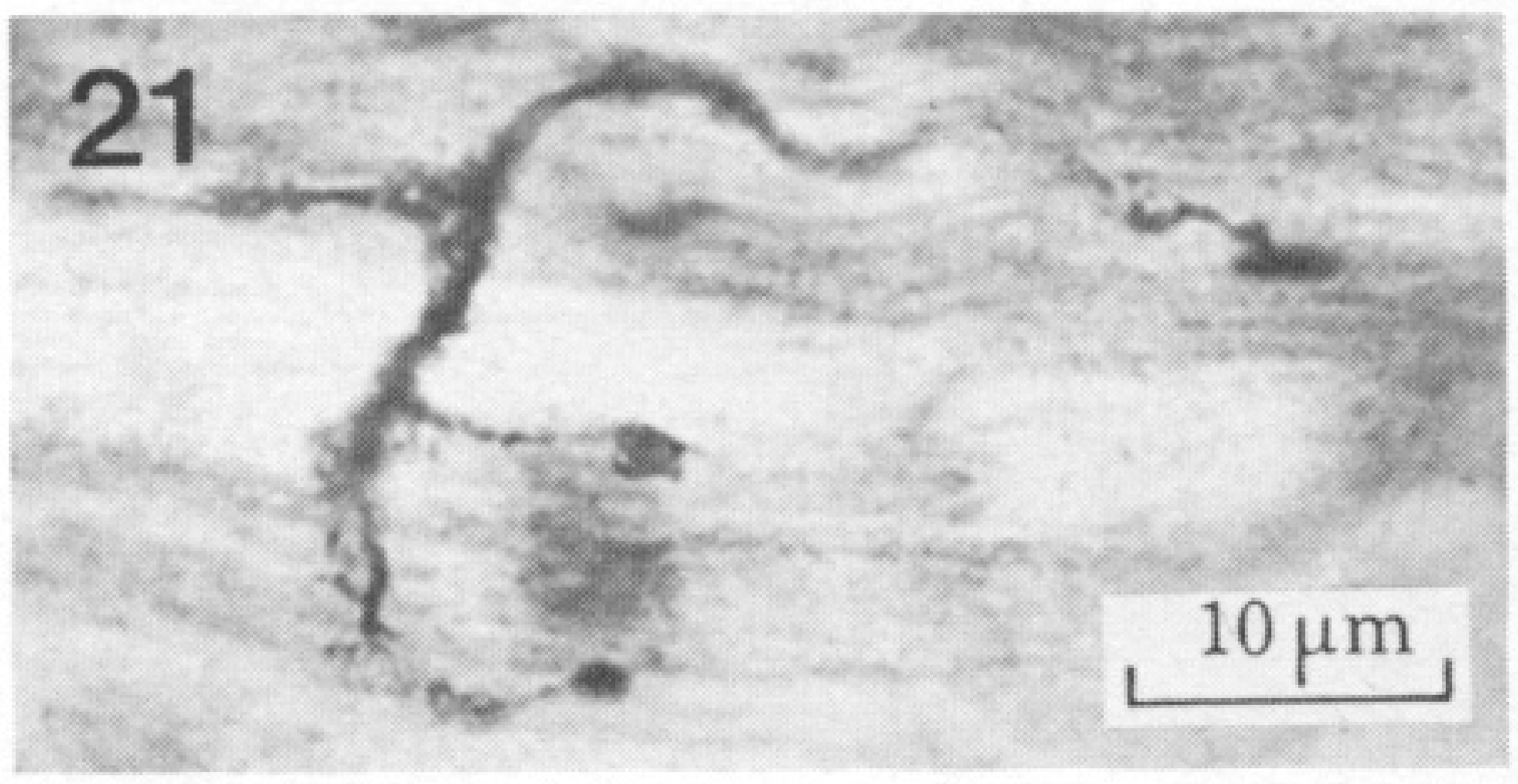

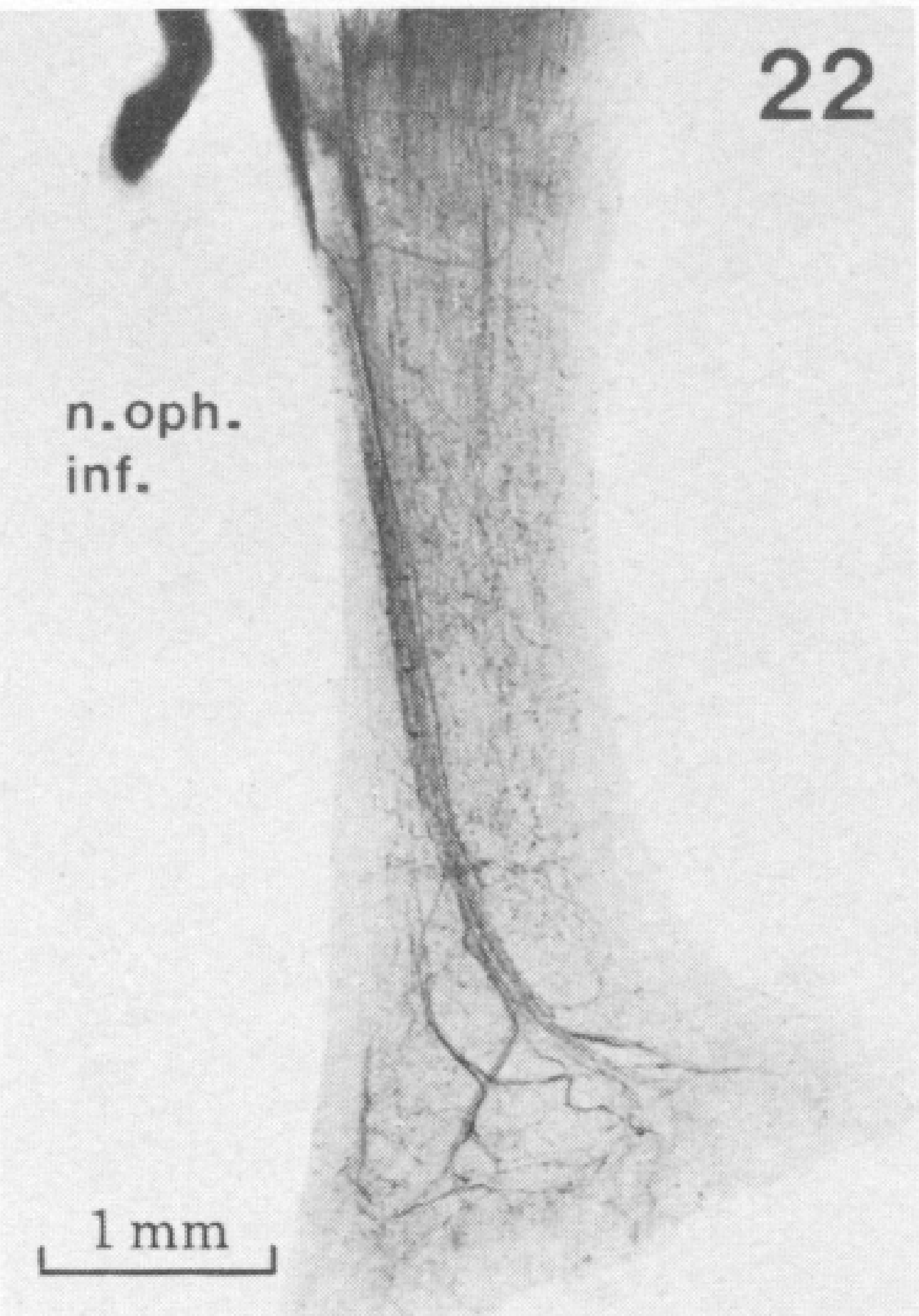

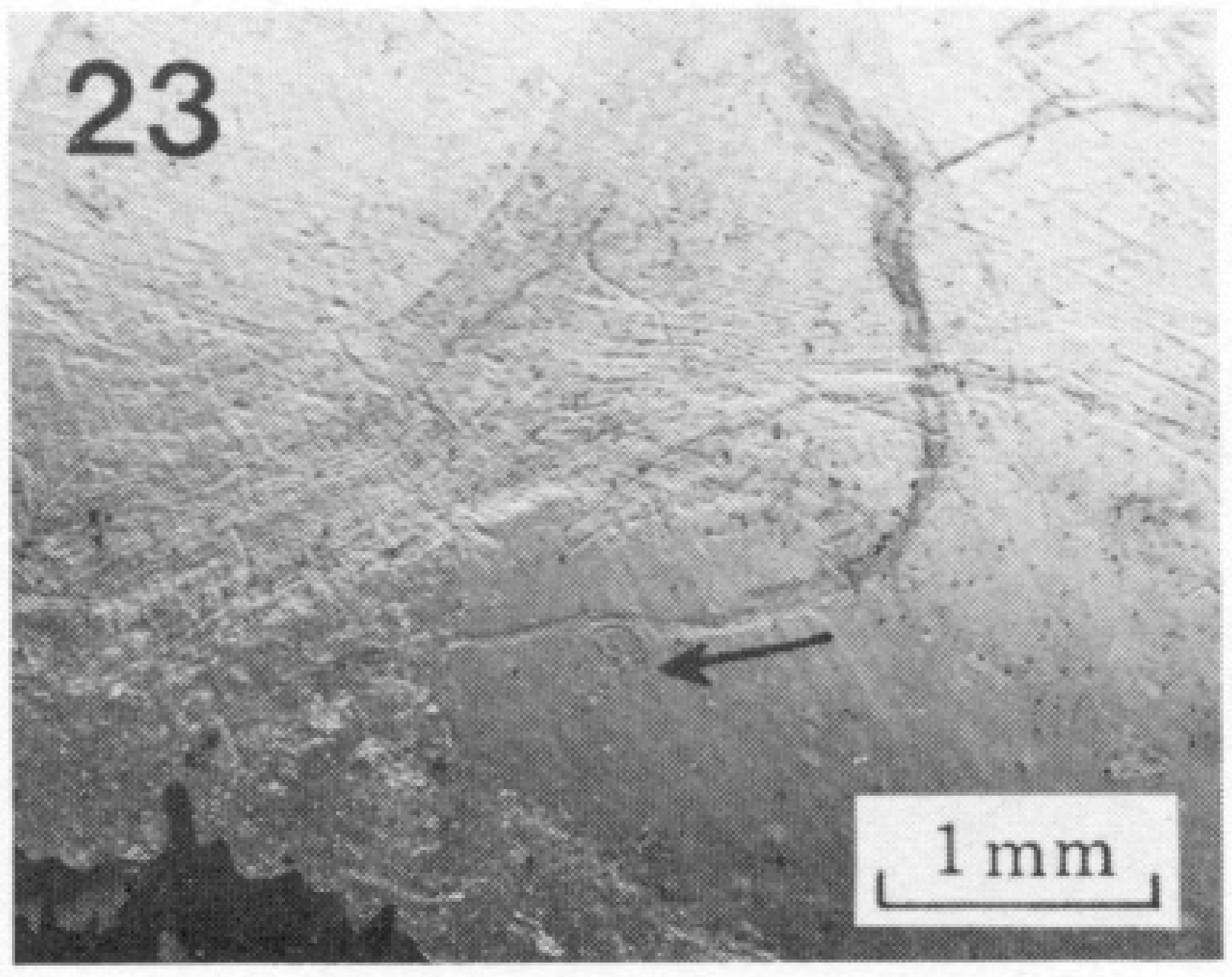

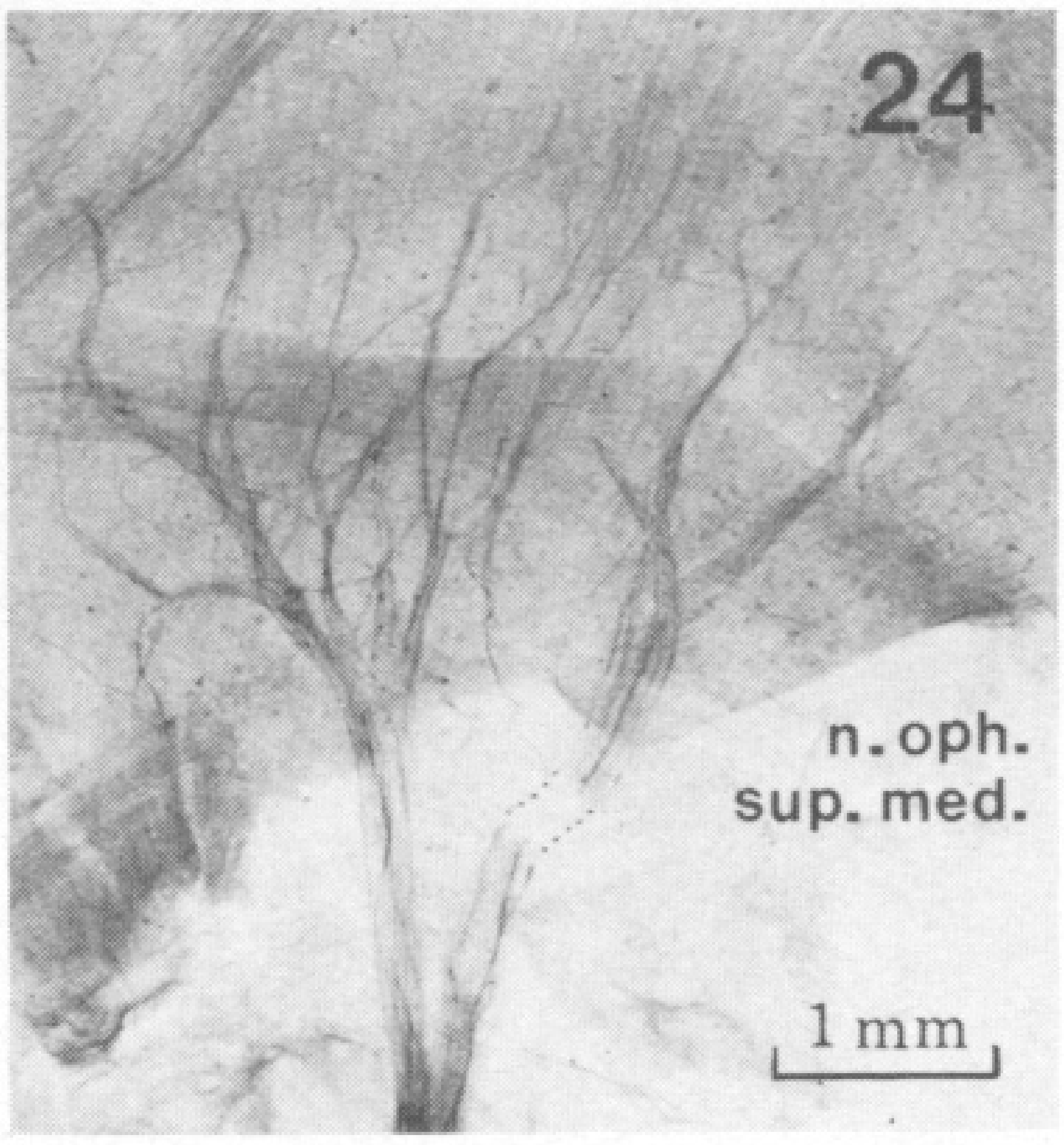

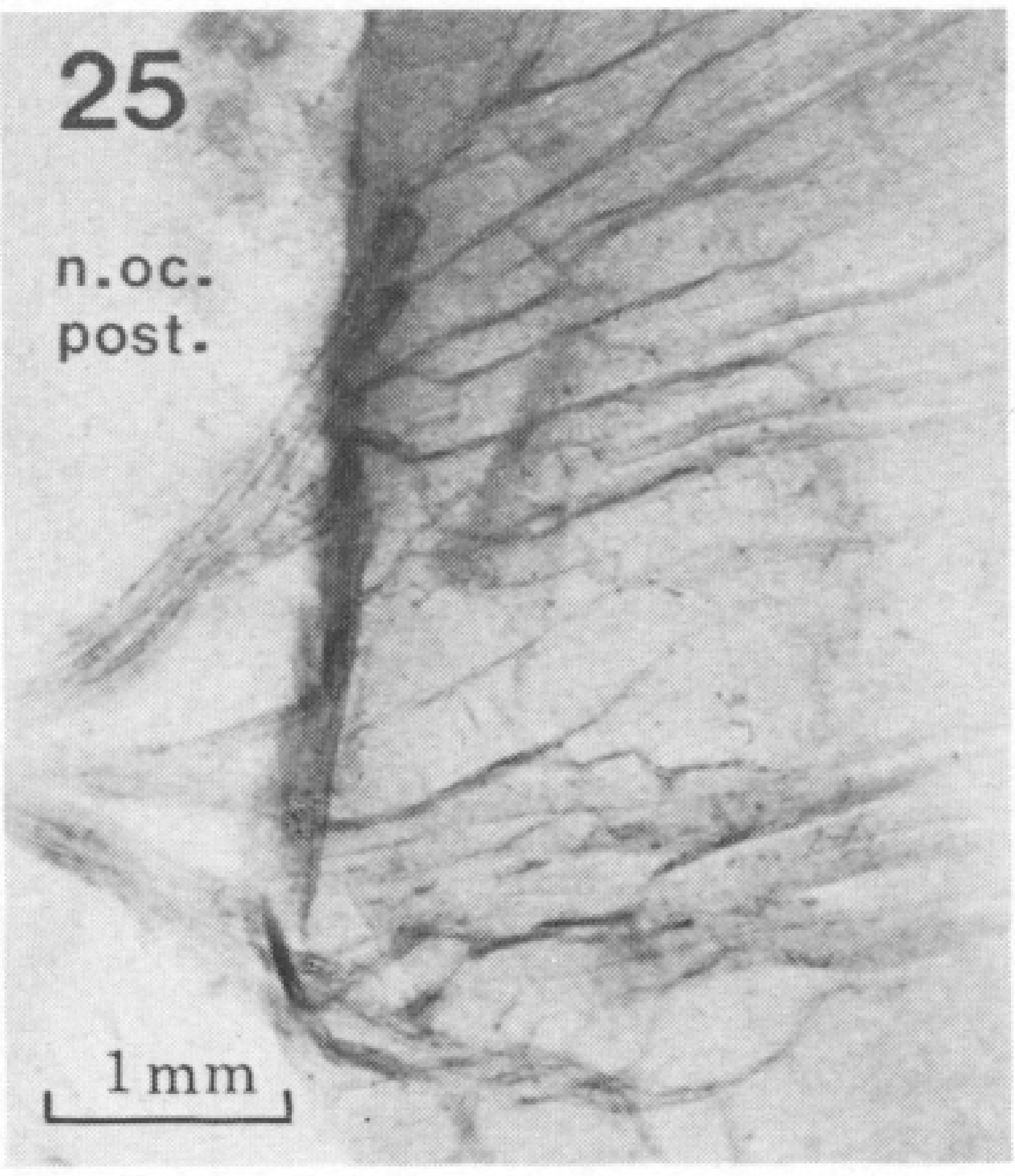

Figures 15–25. For description see p. 174.

26

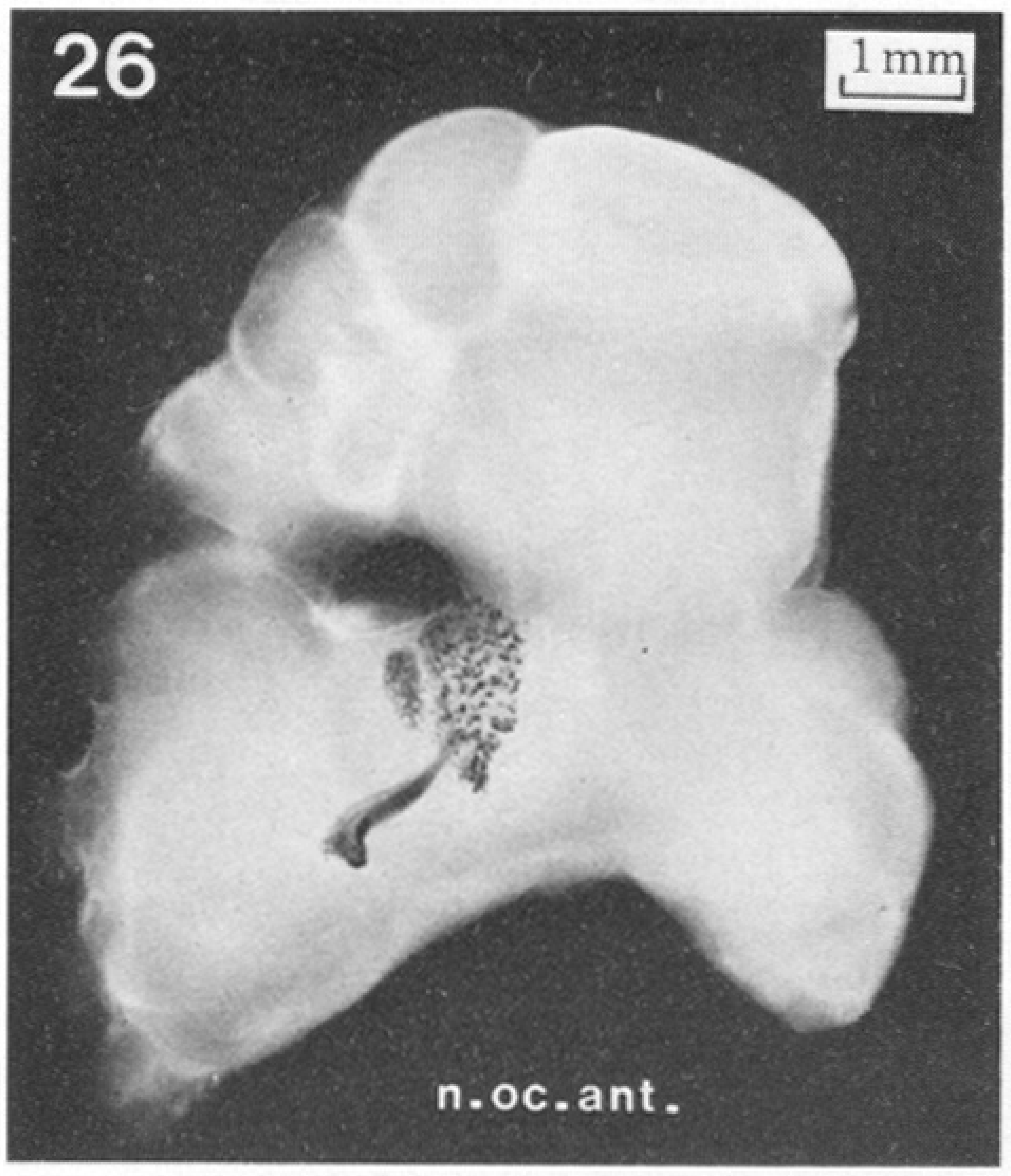

27

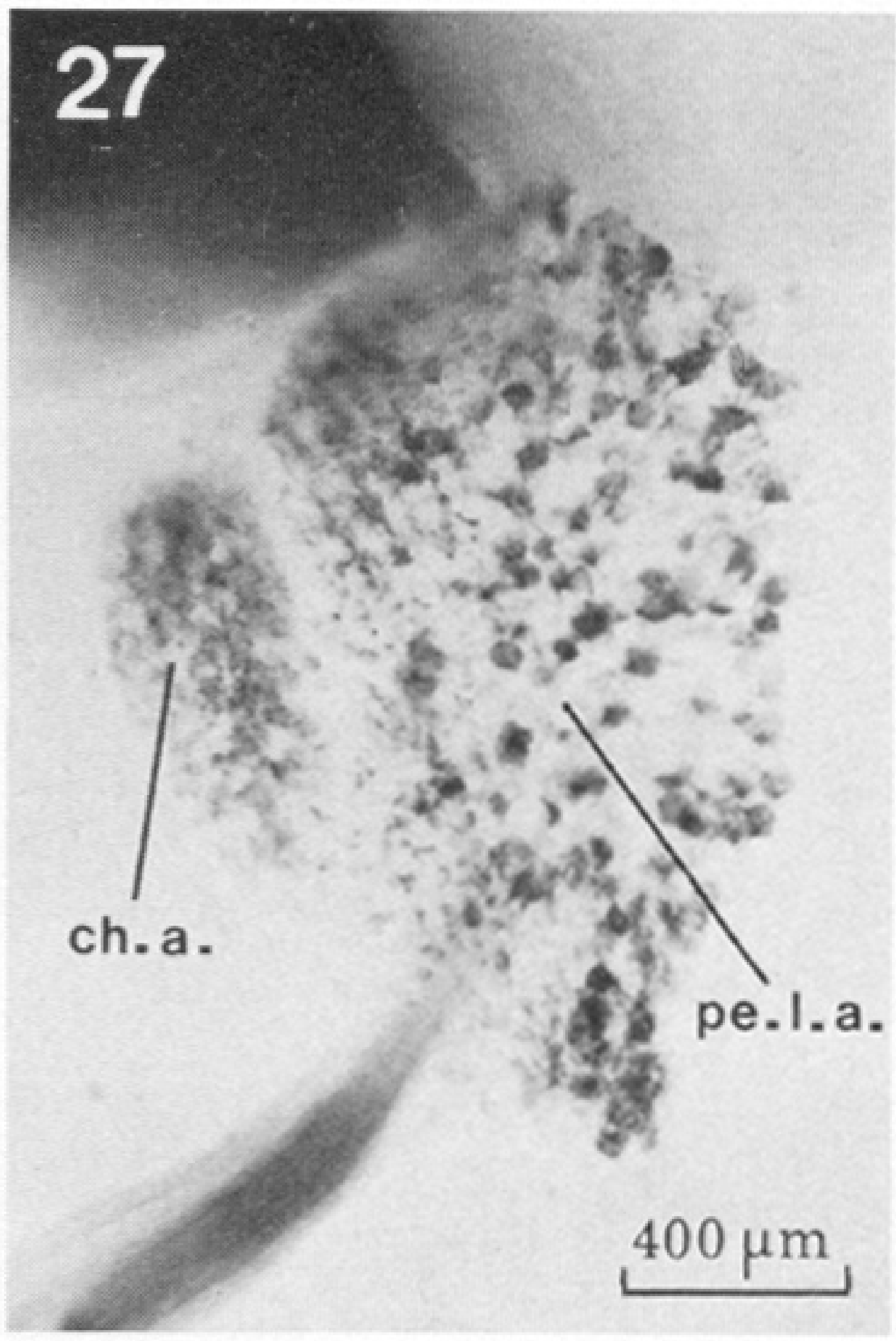

28

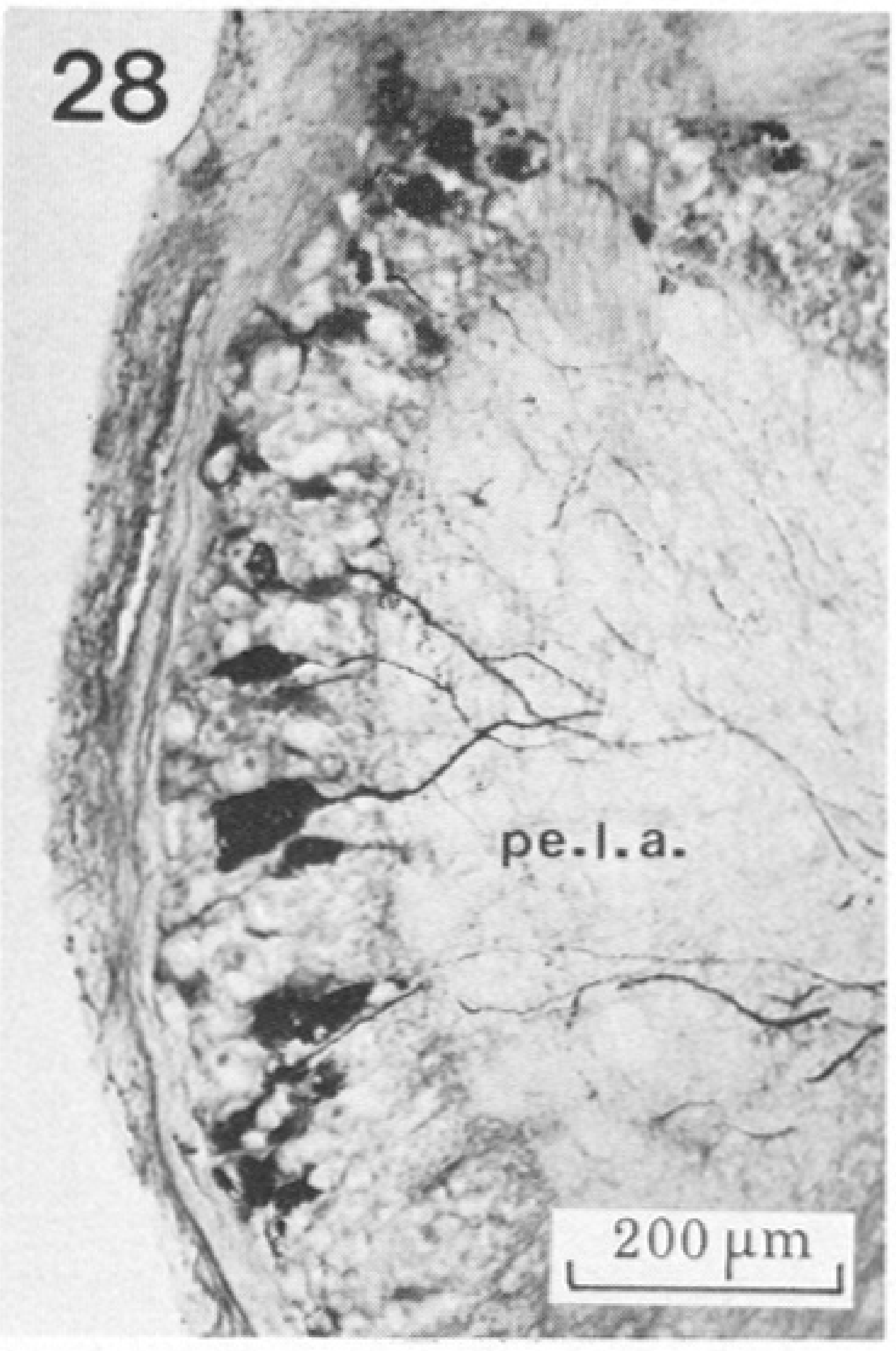

29

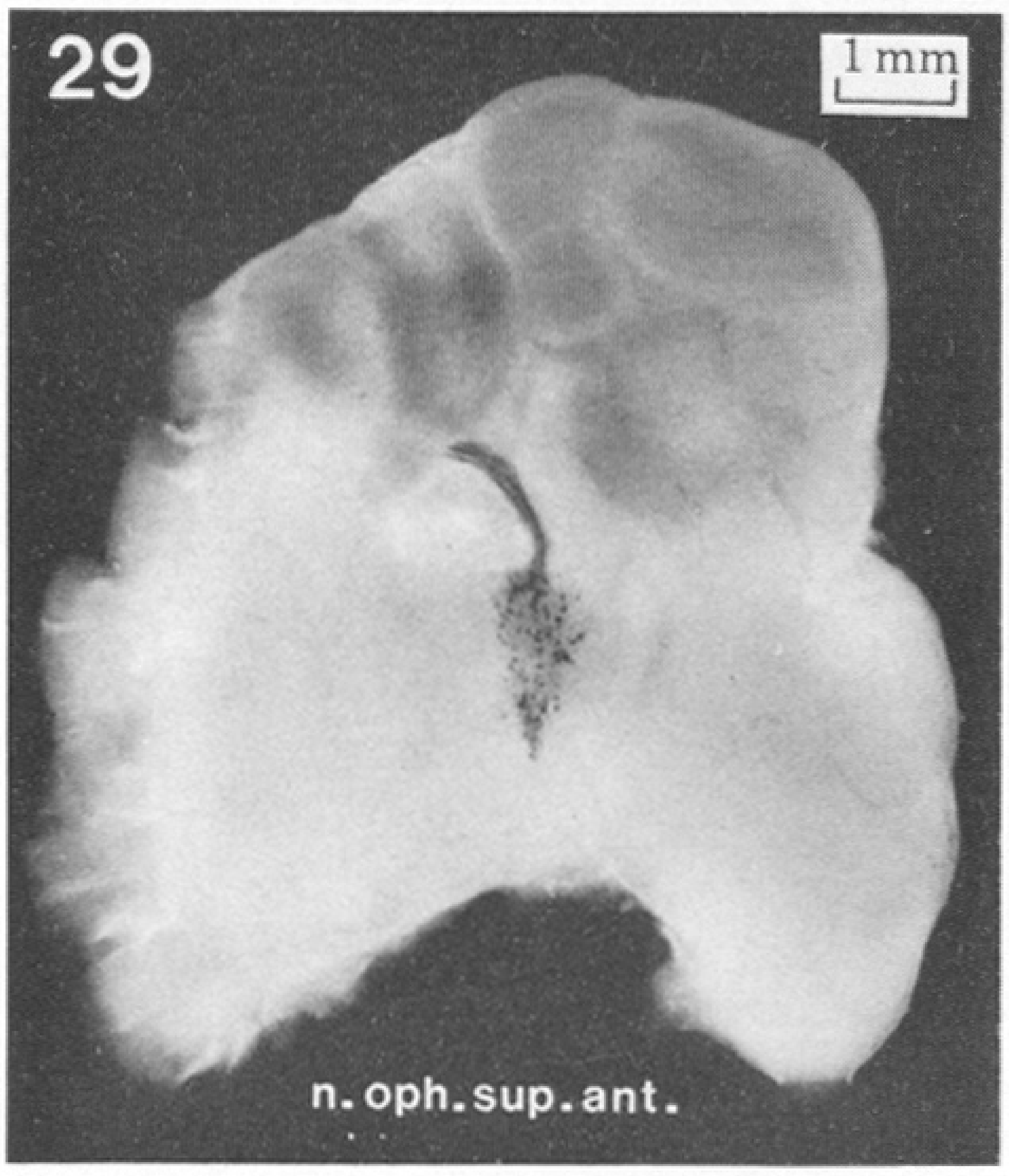

30

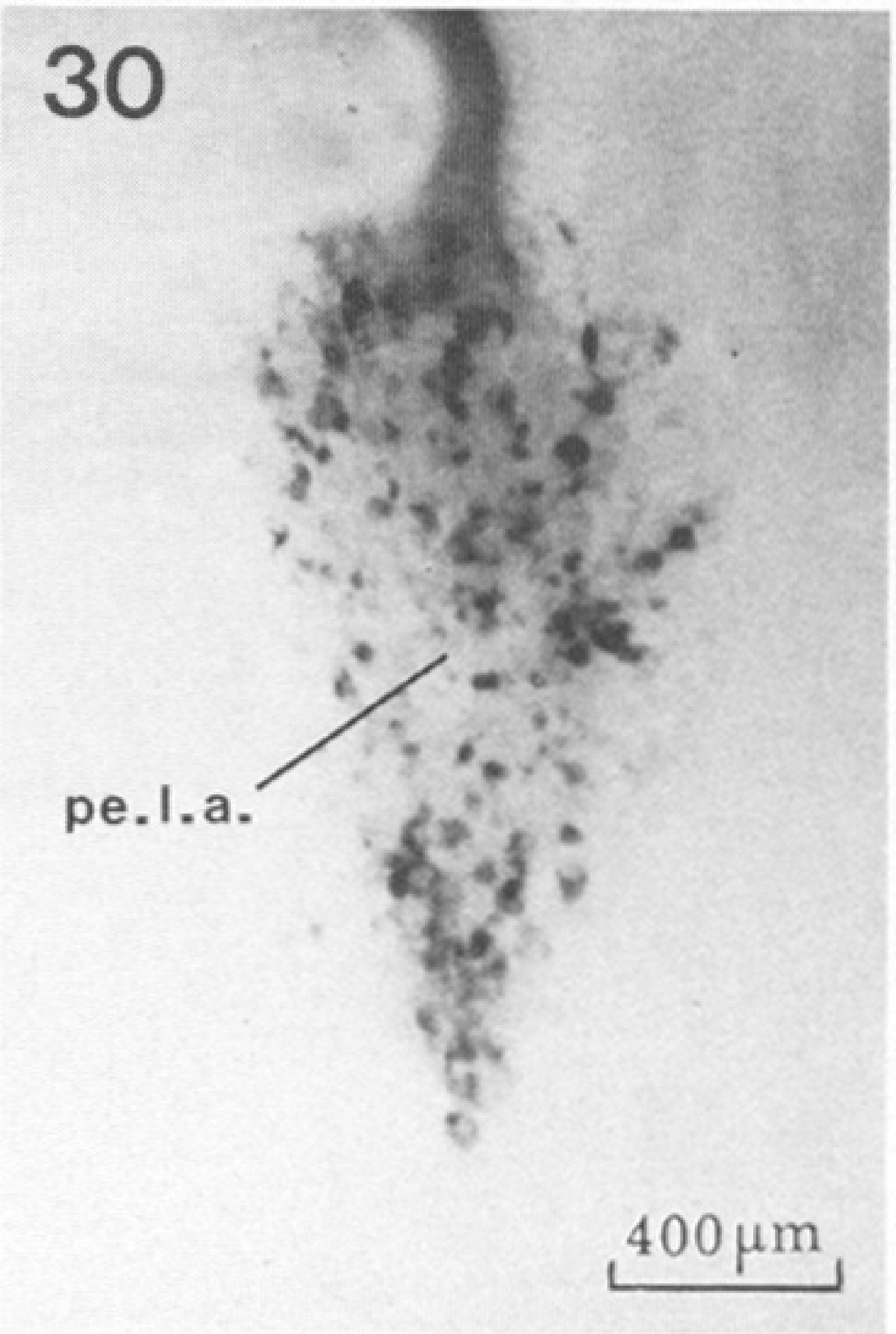

31

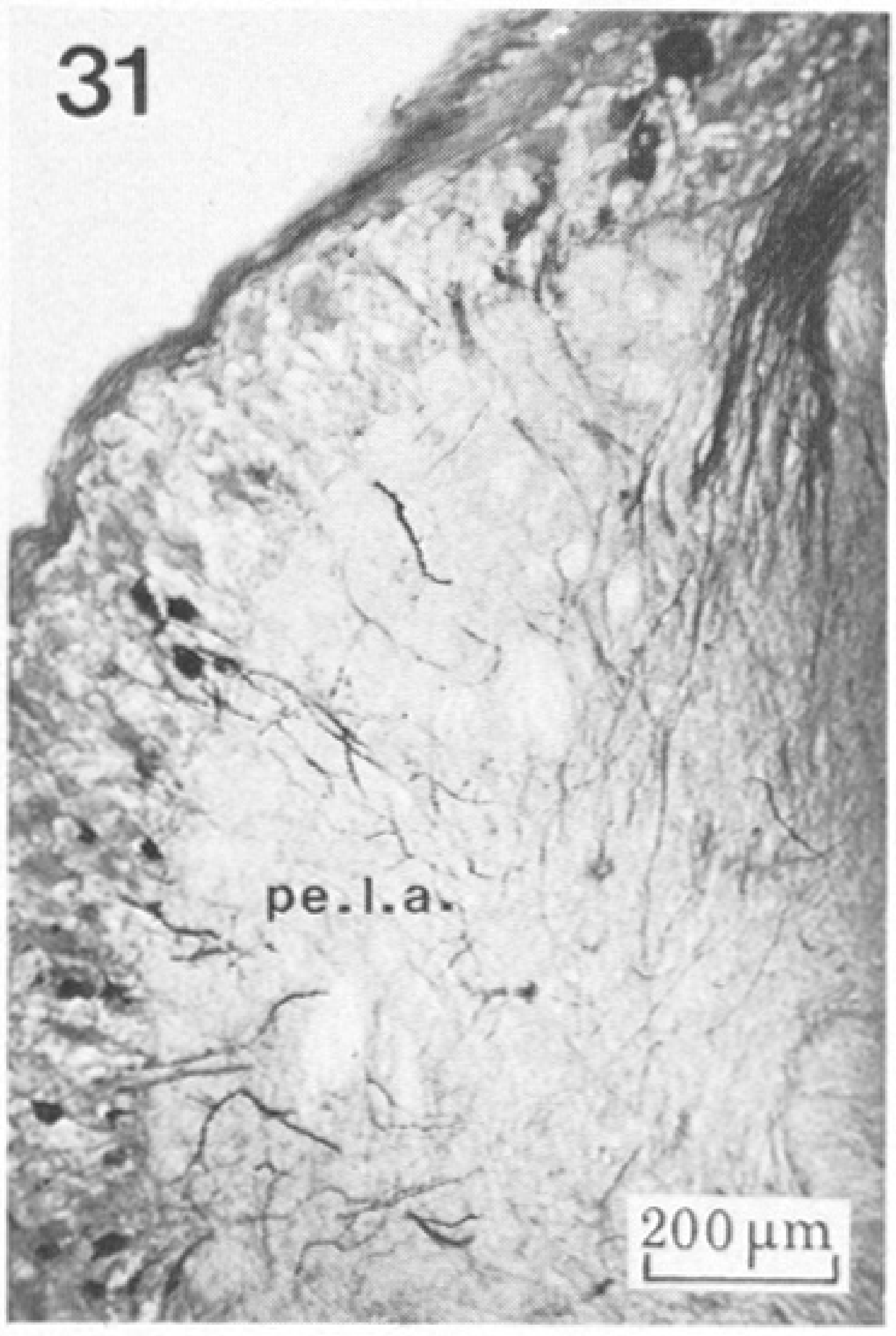

32

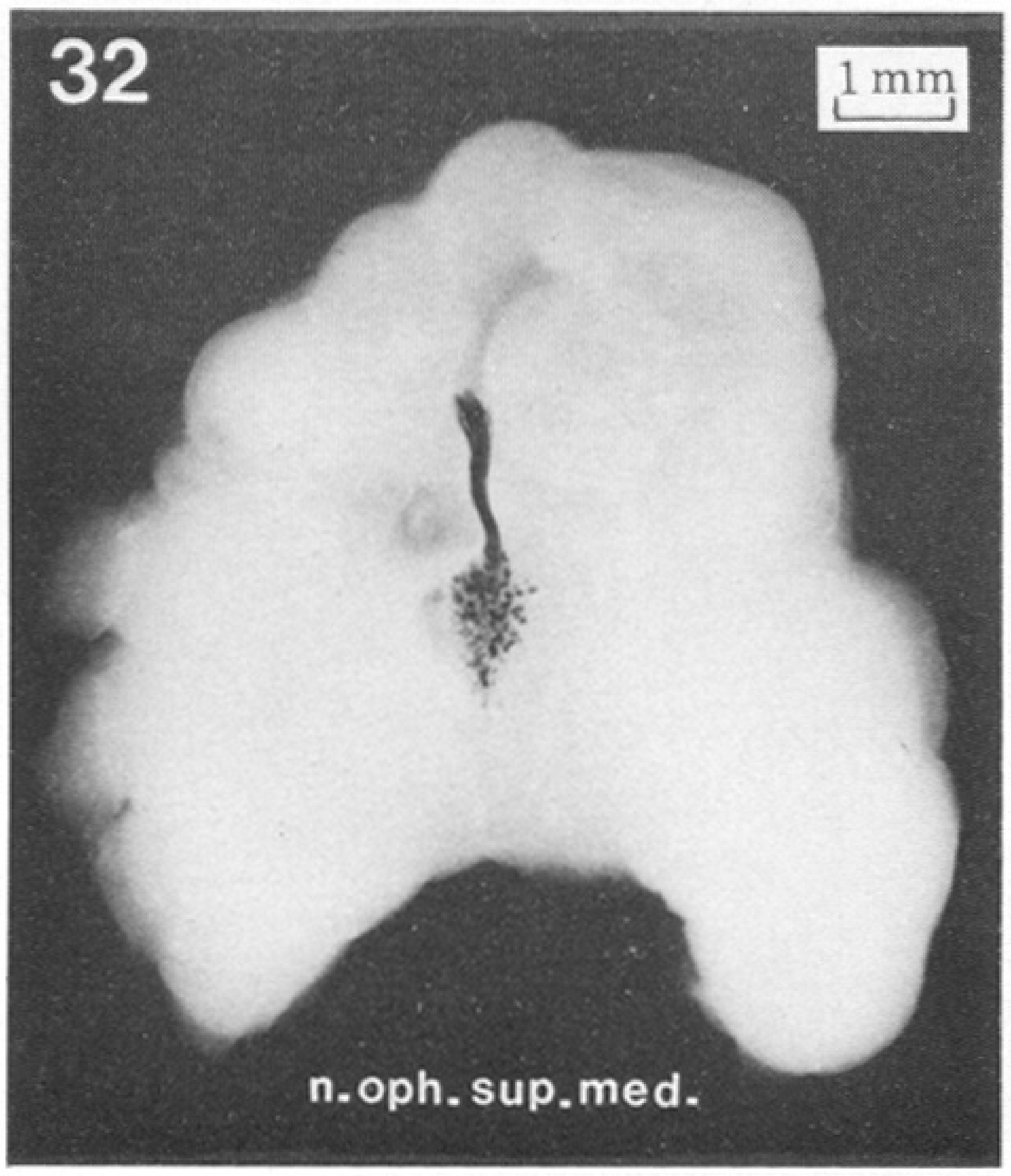

33

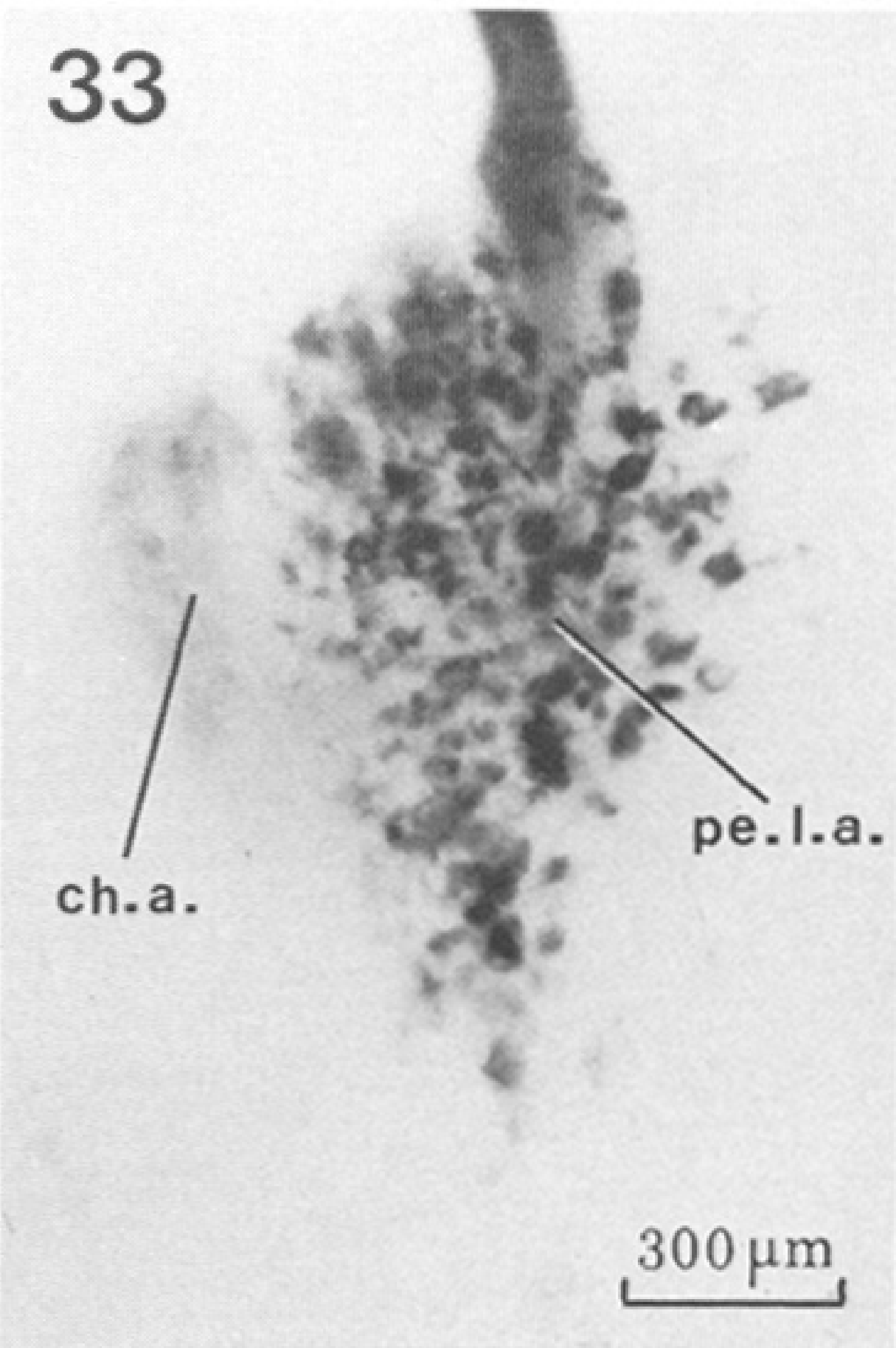

34

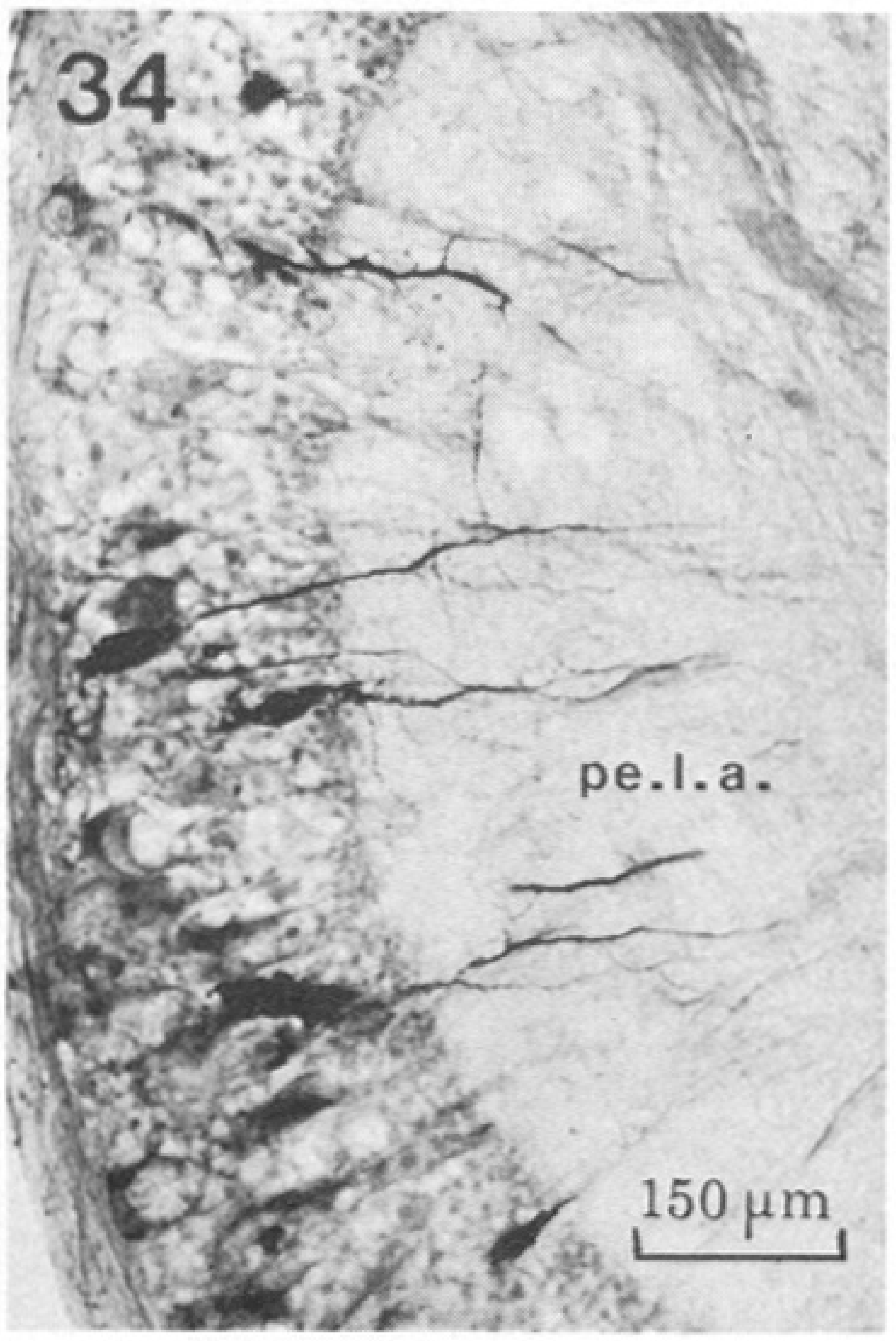

FIGURES 26–34. For description see p. 174.

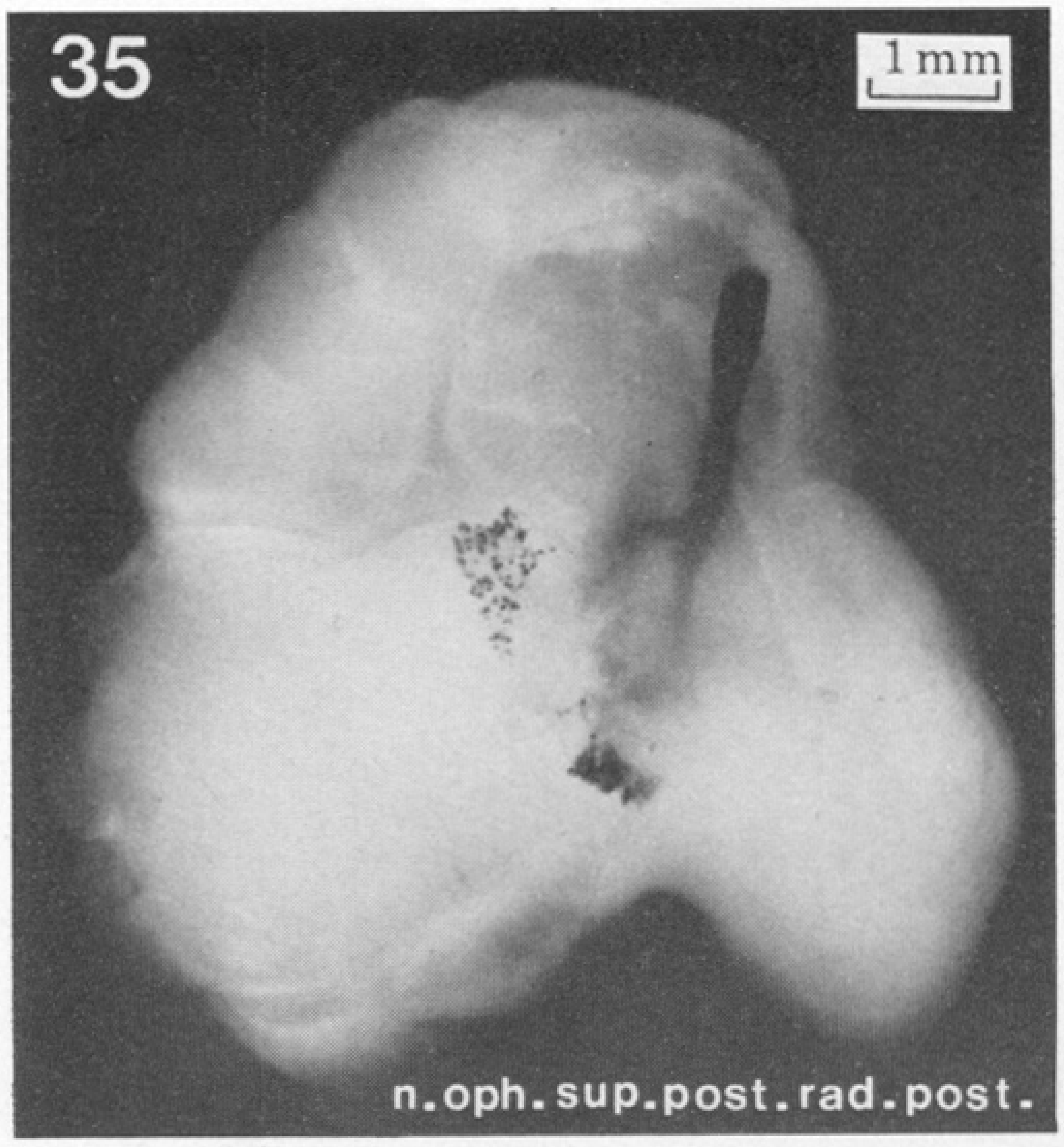

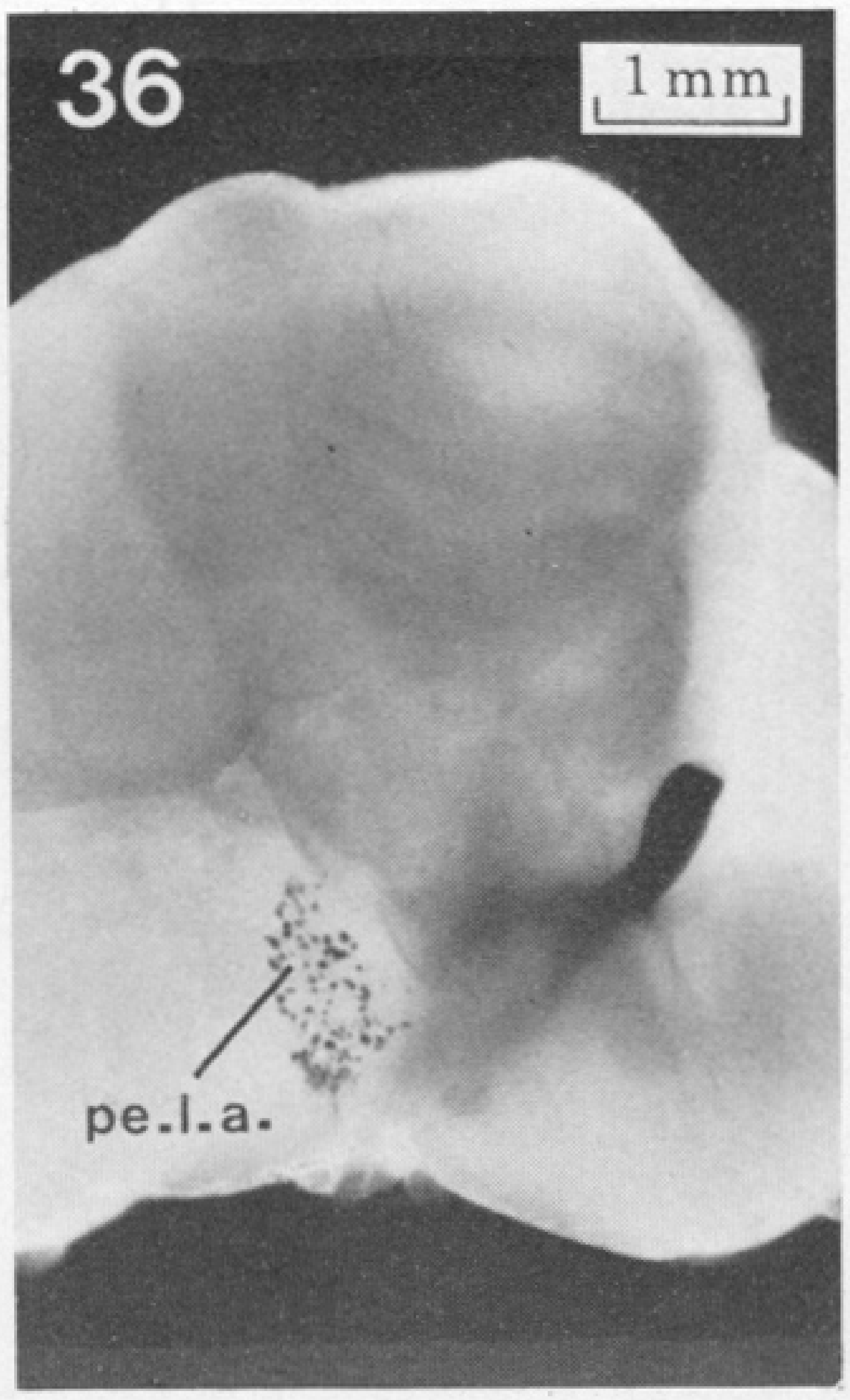

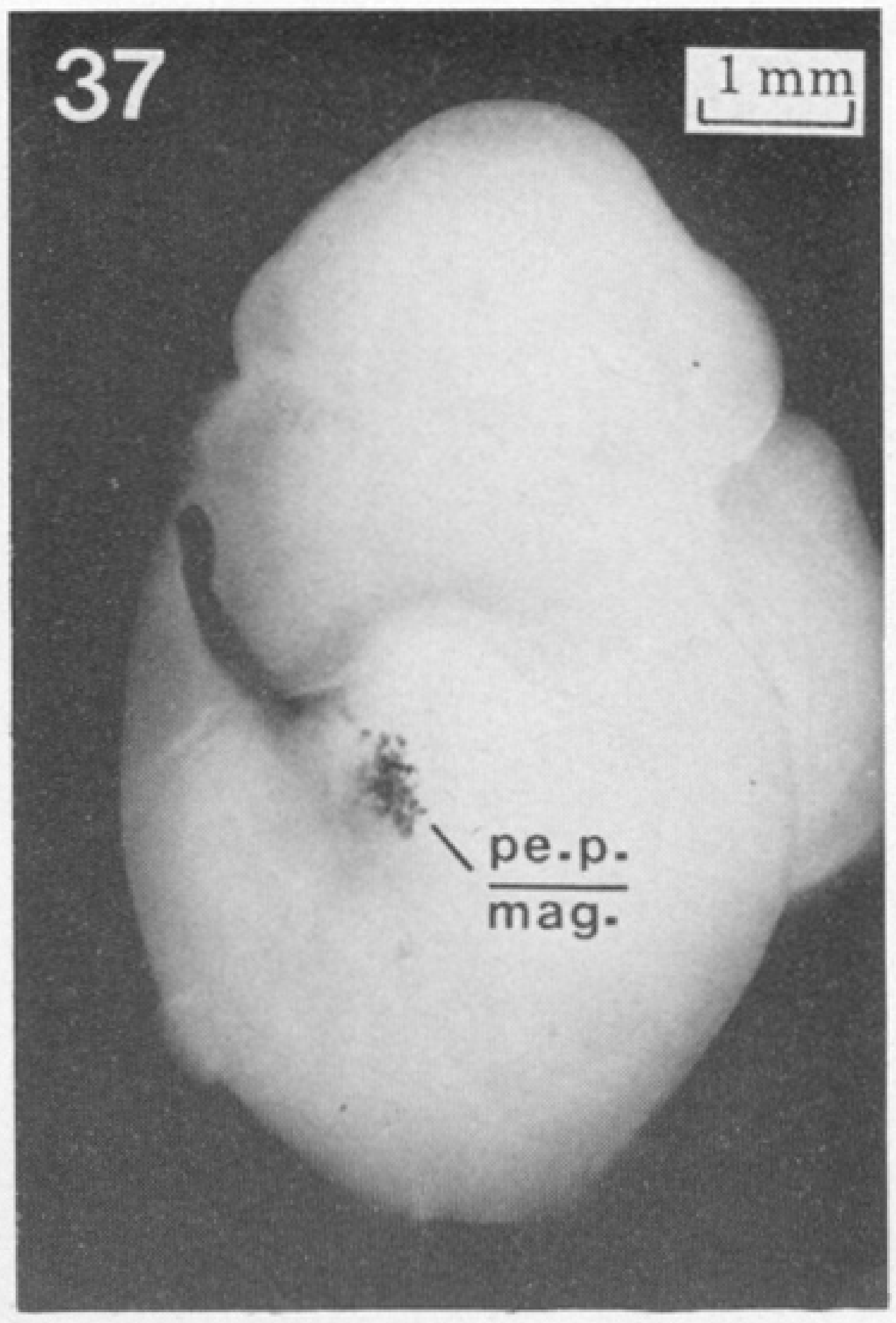

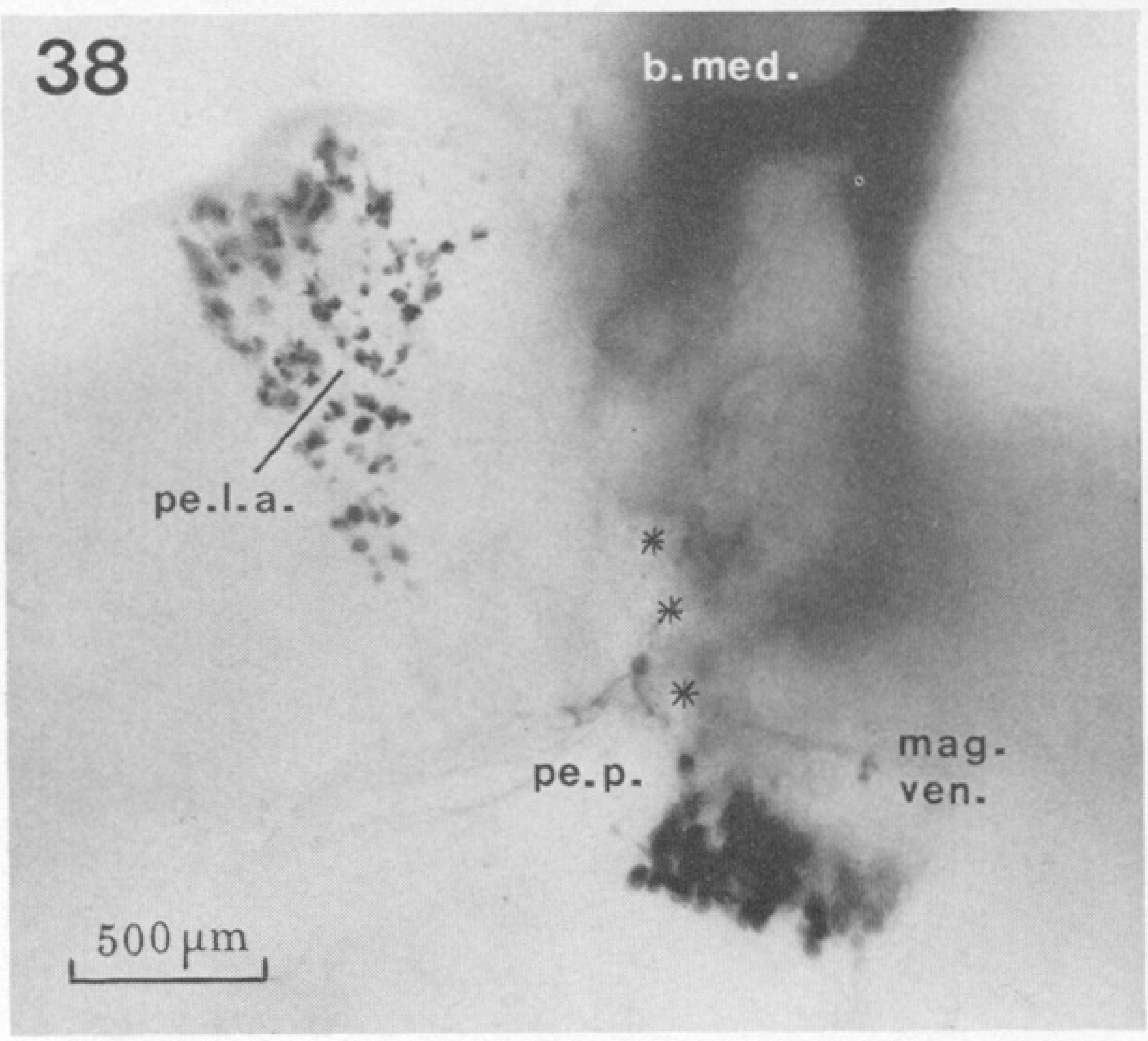

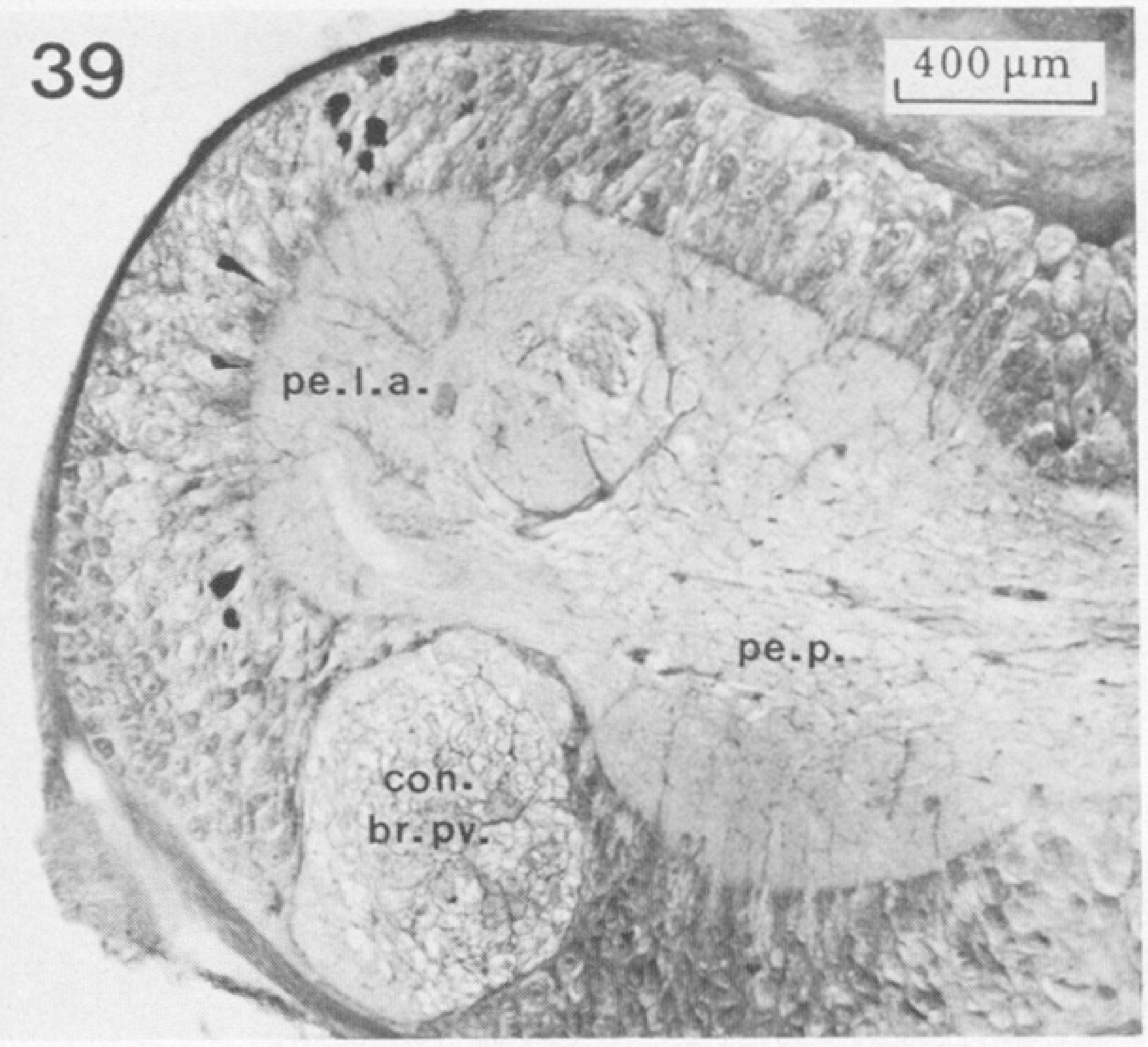

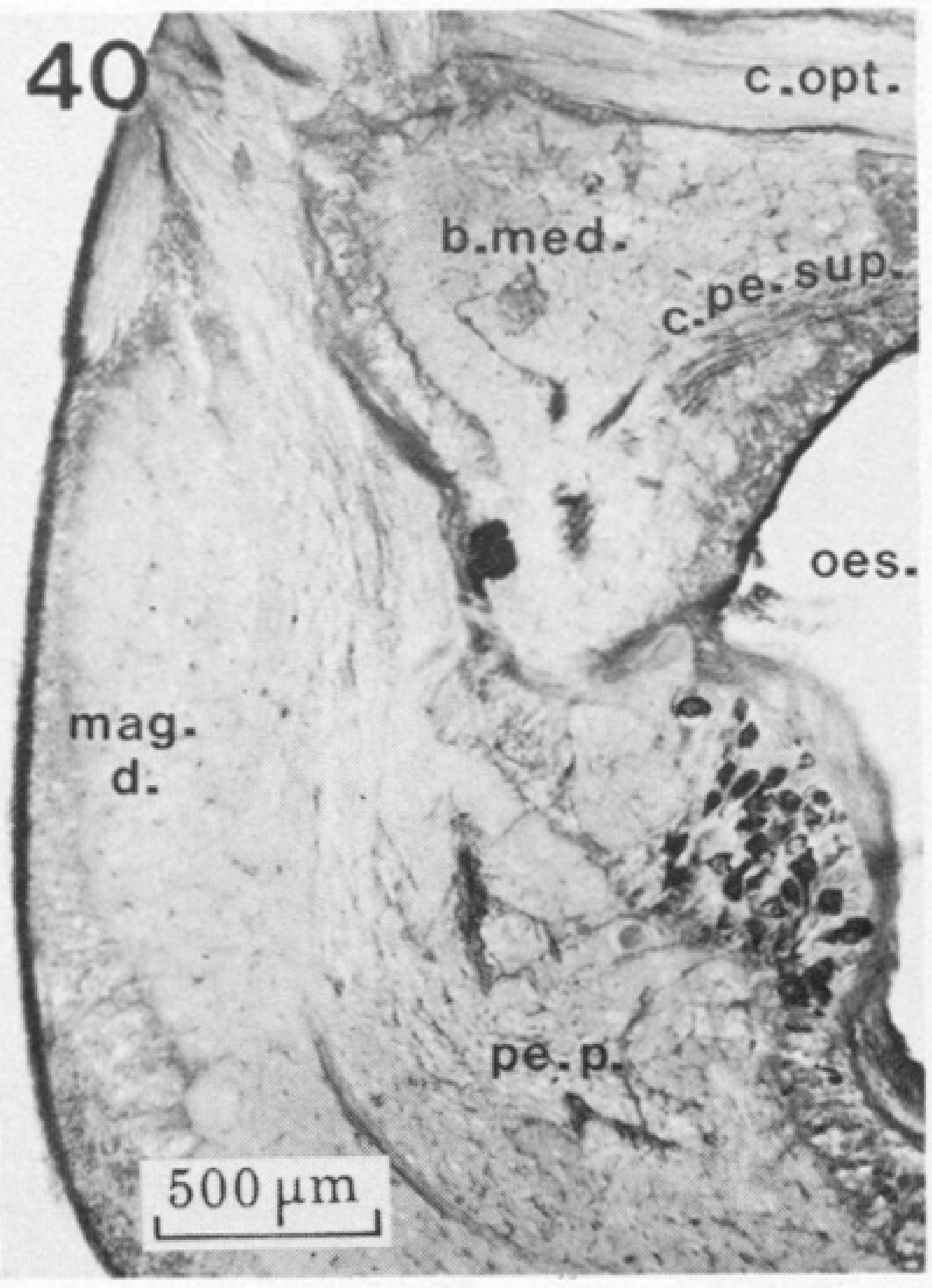

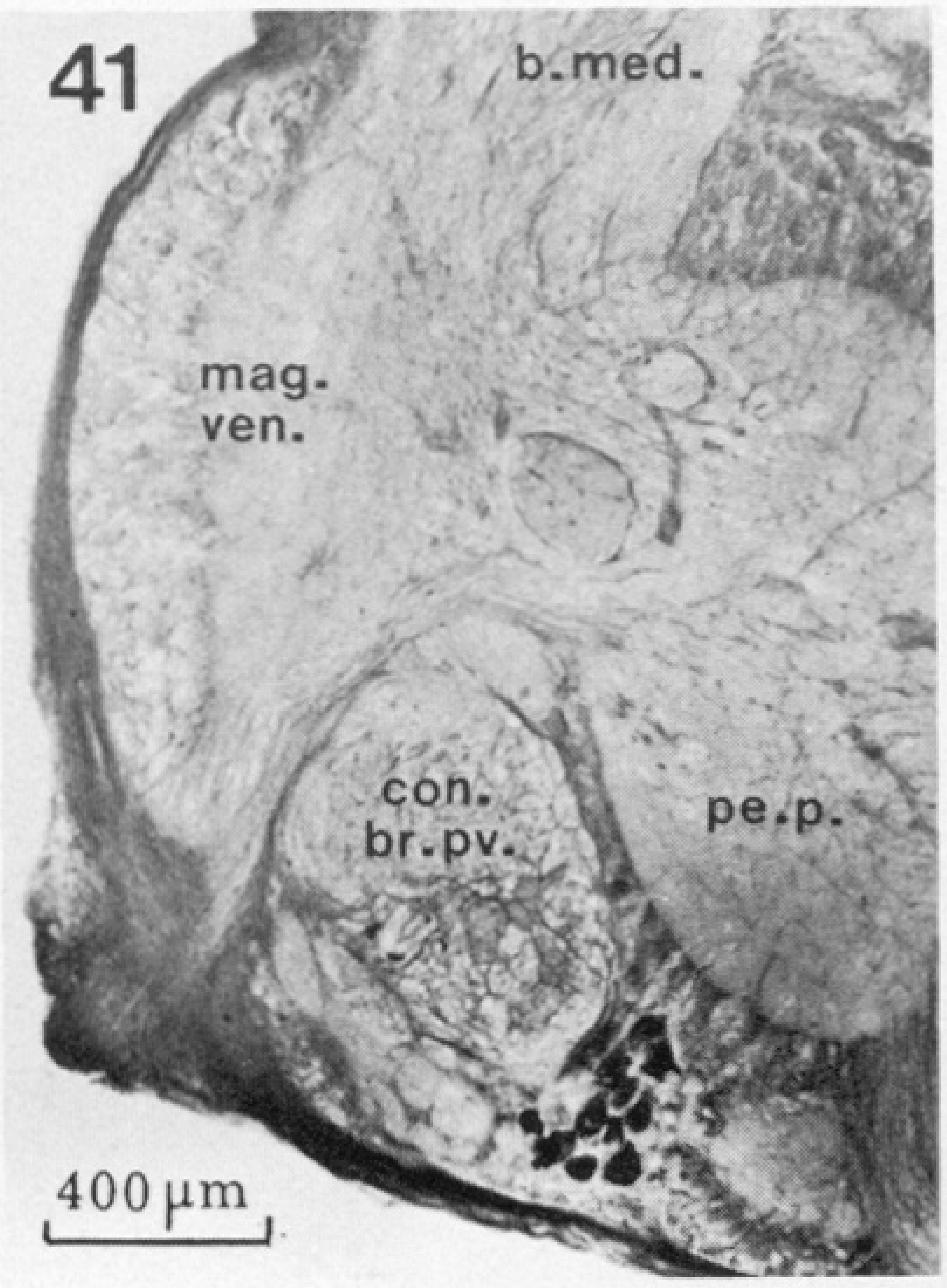

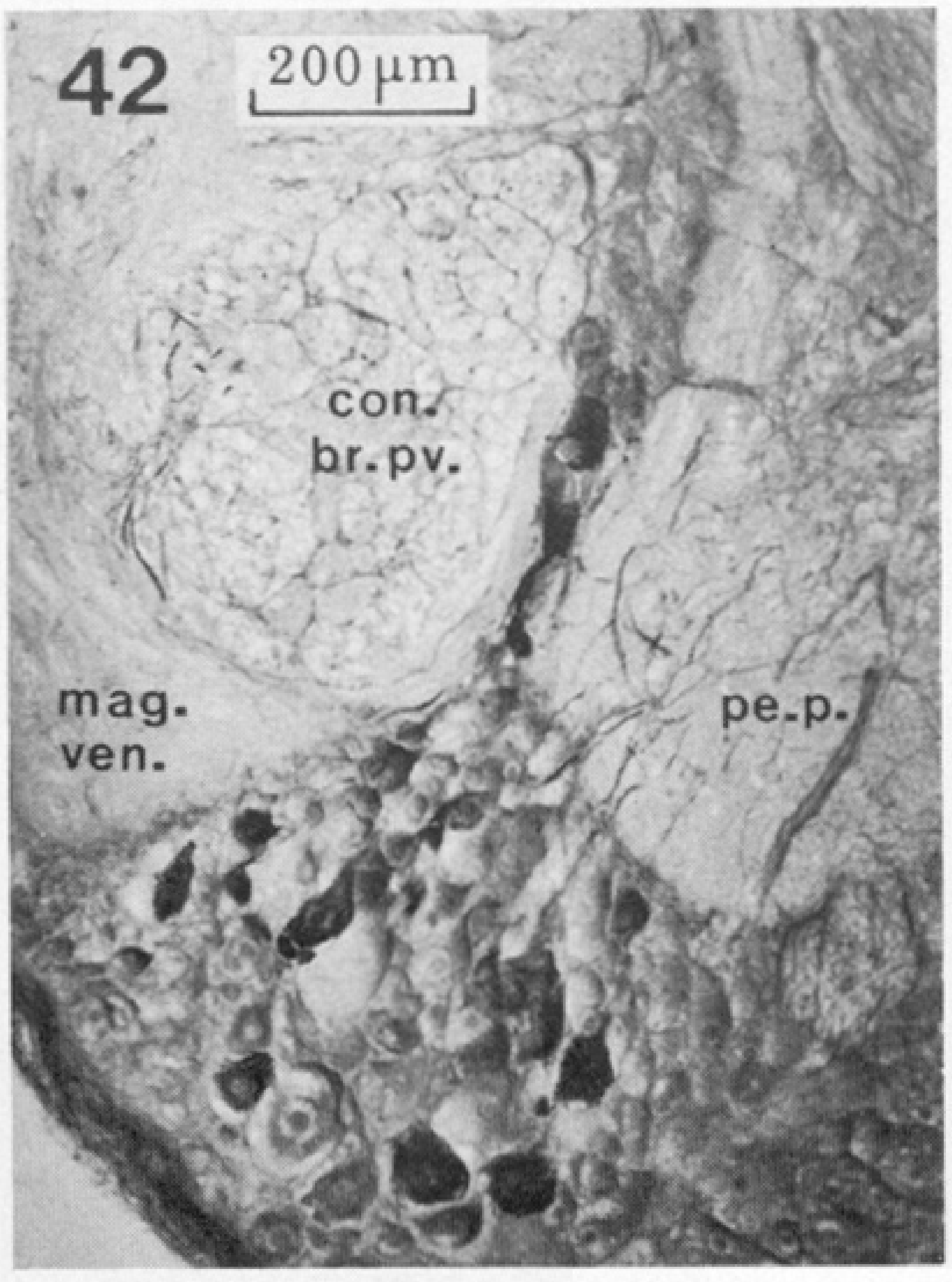

FIGURES 35–42. For description see p. 174.

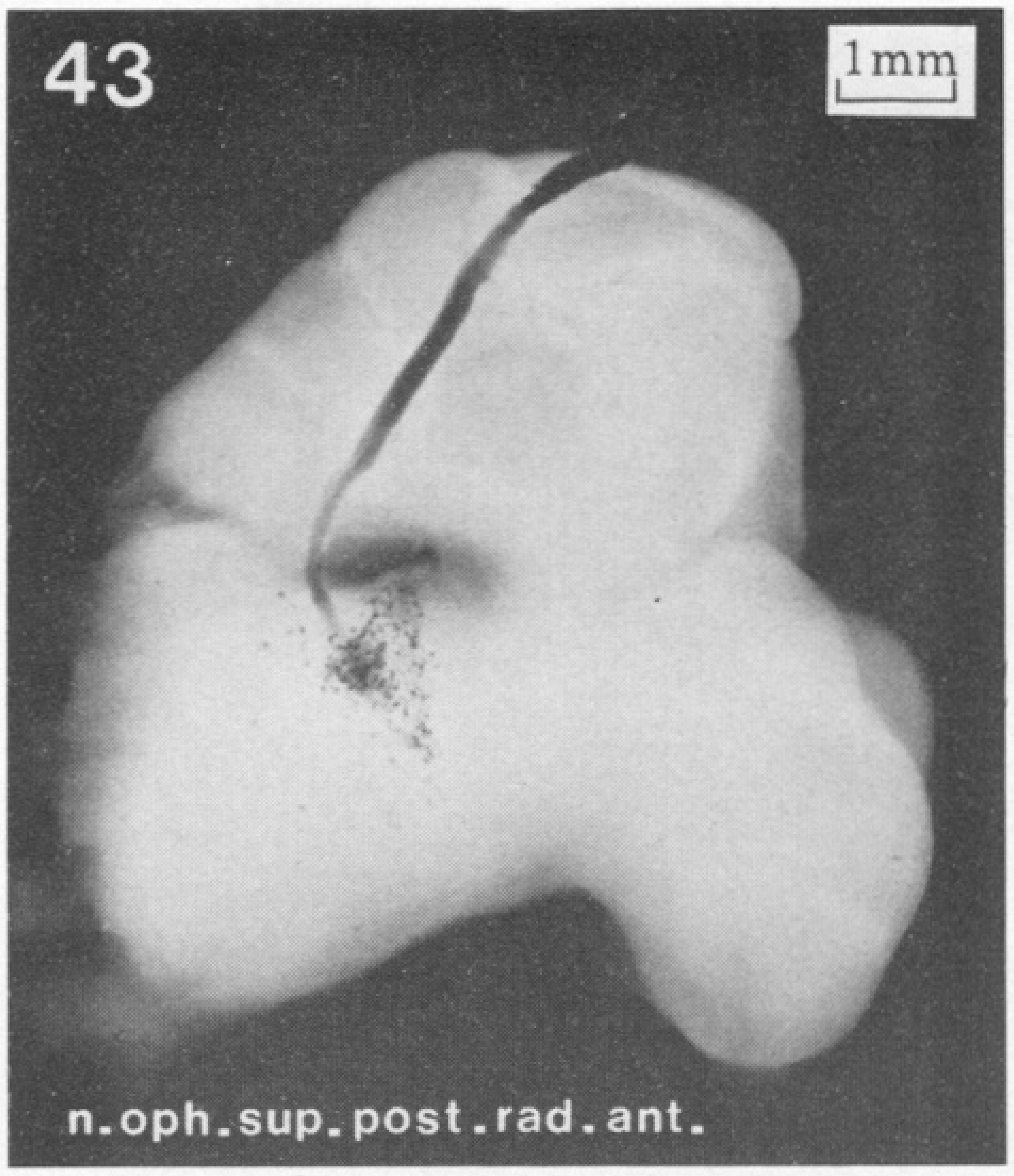

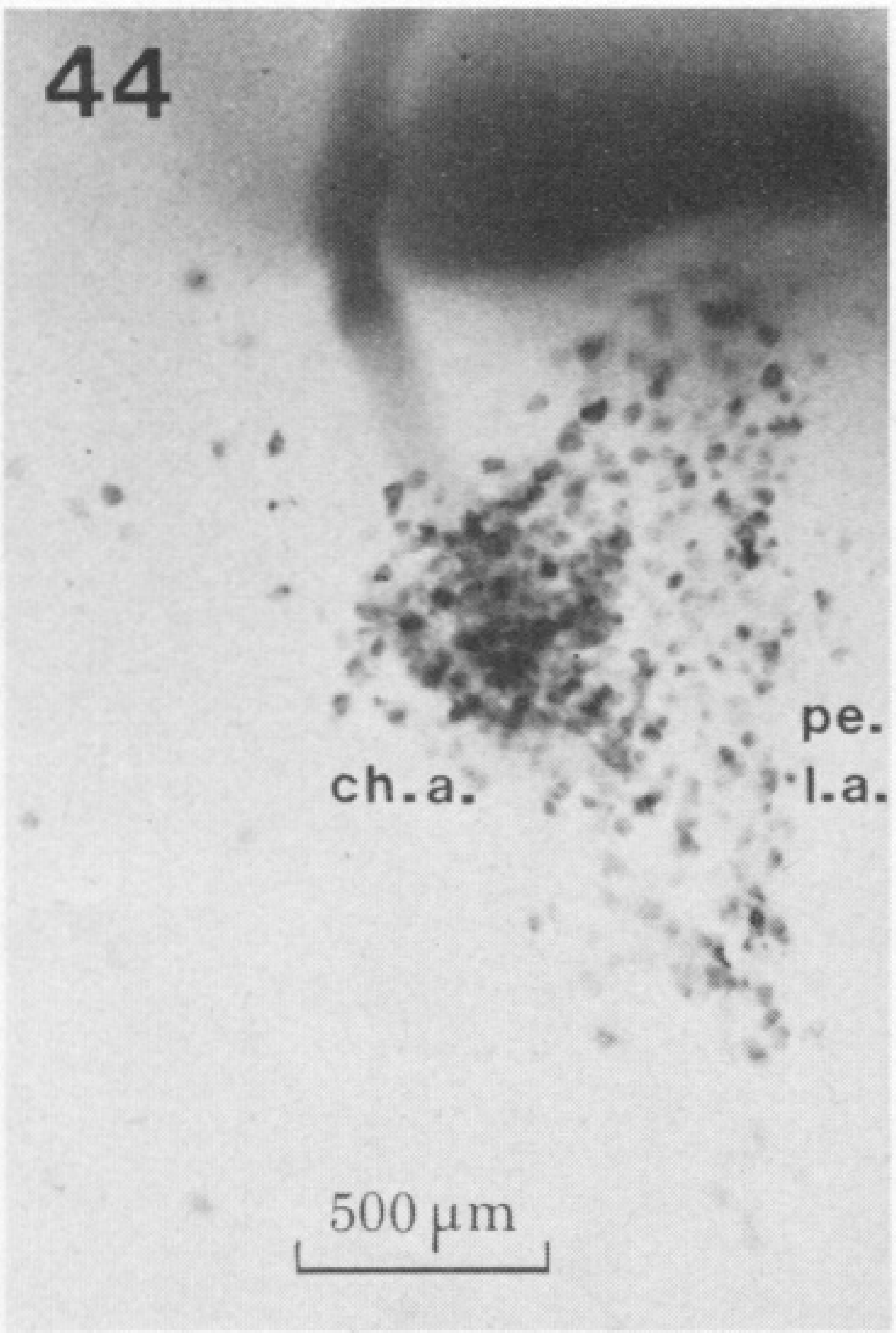

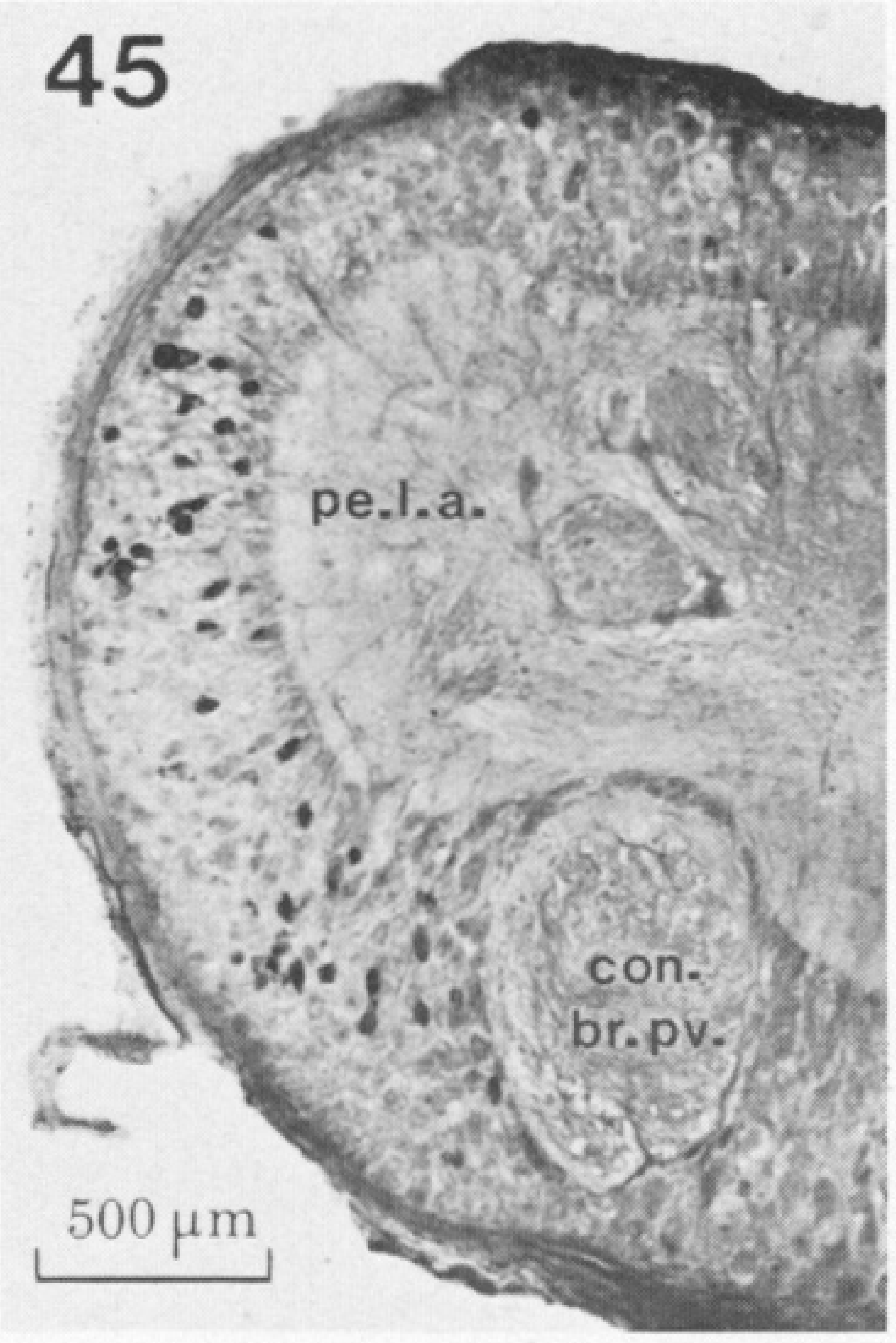

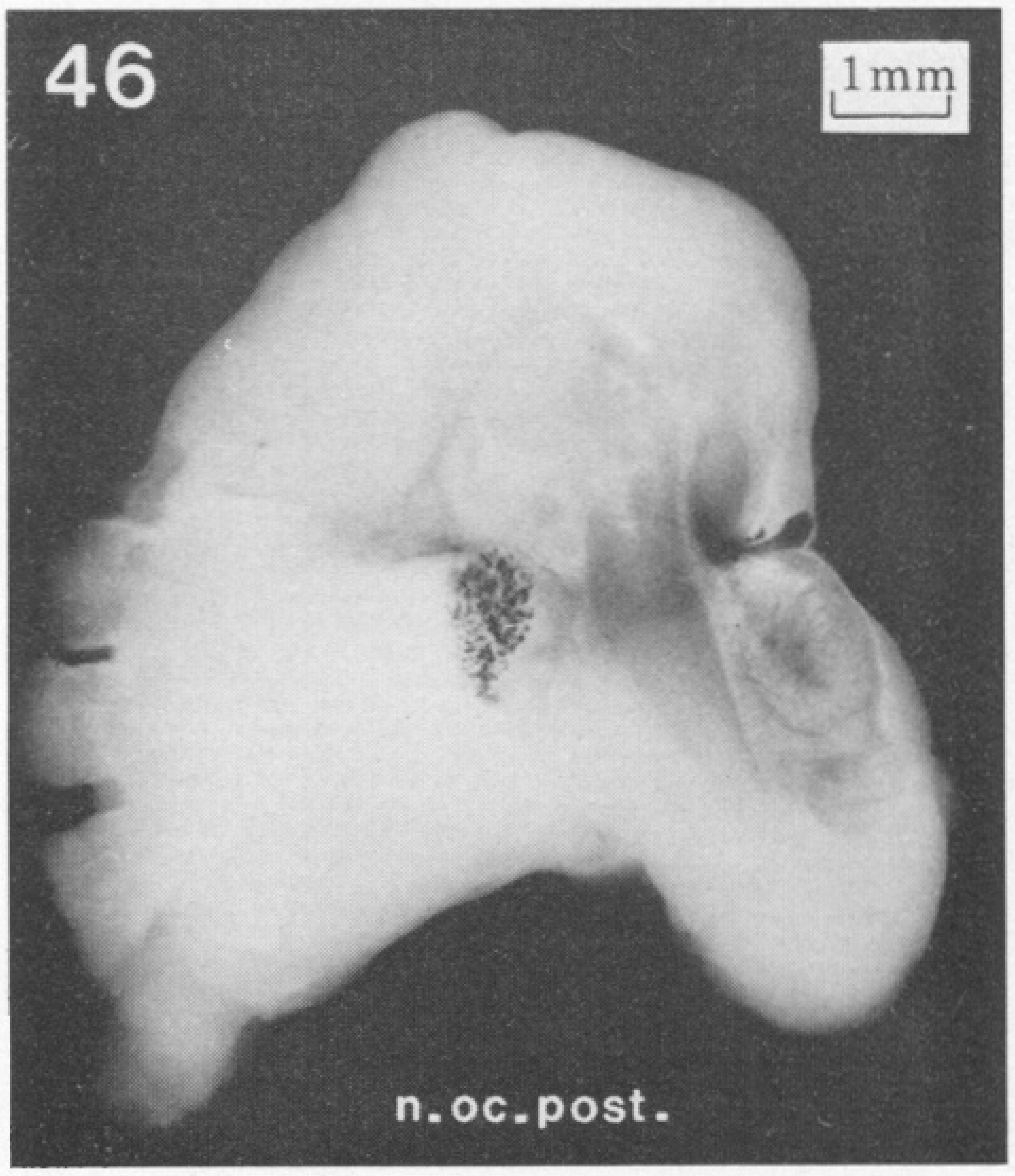

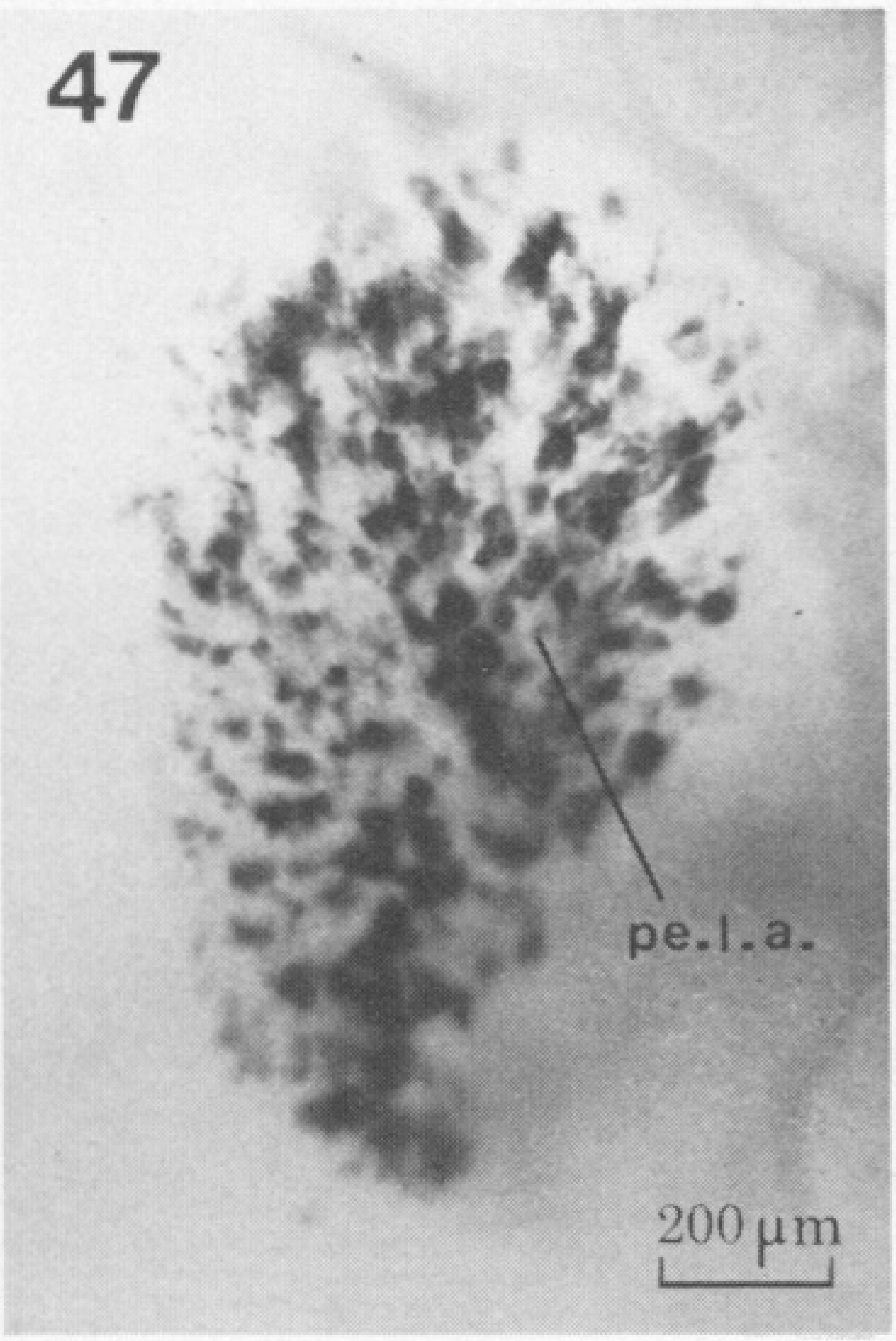

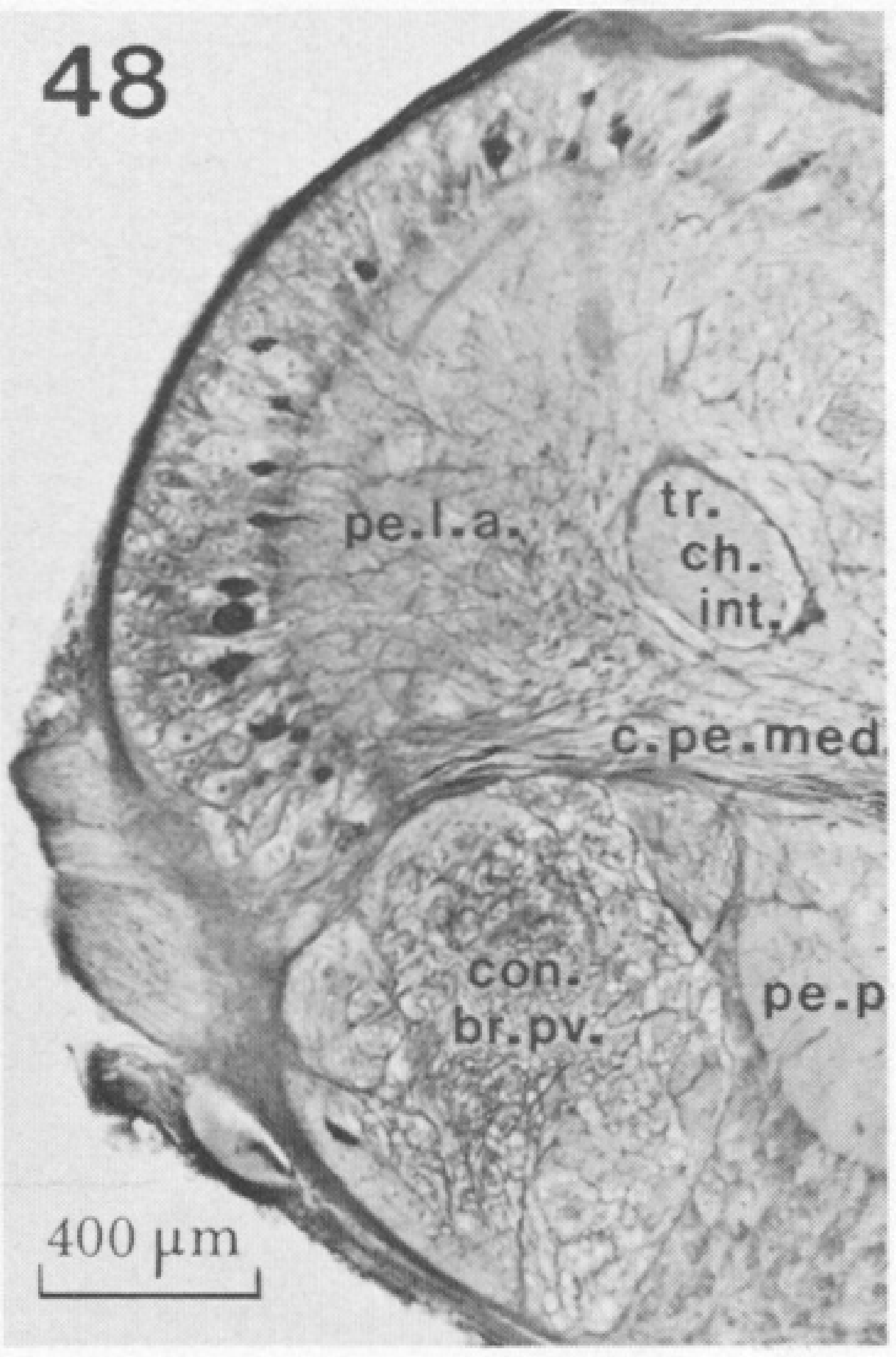

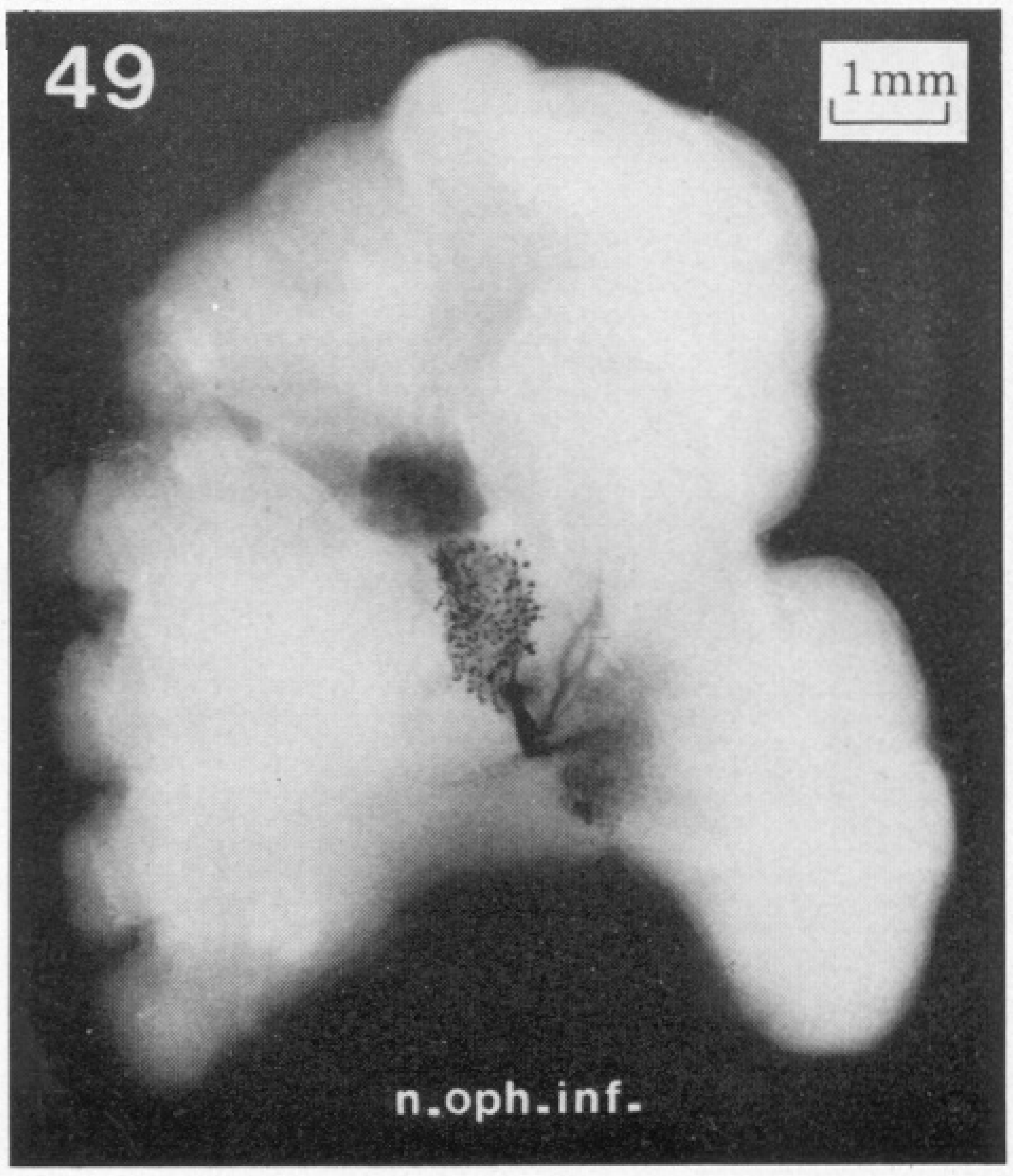

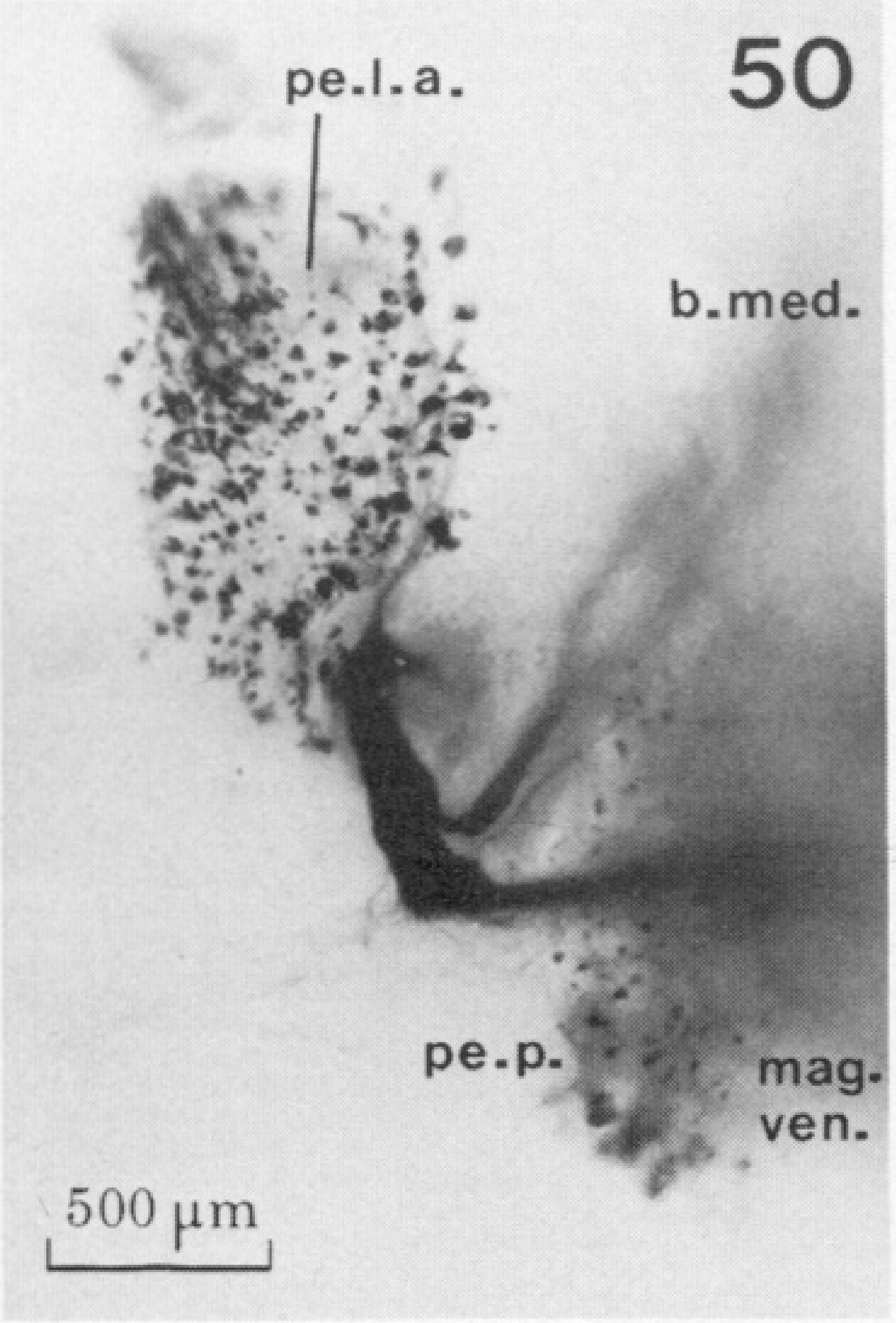

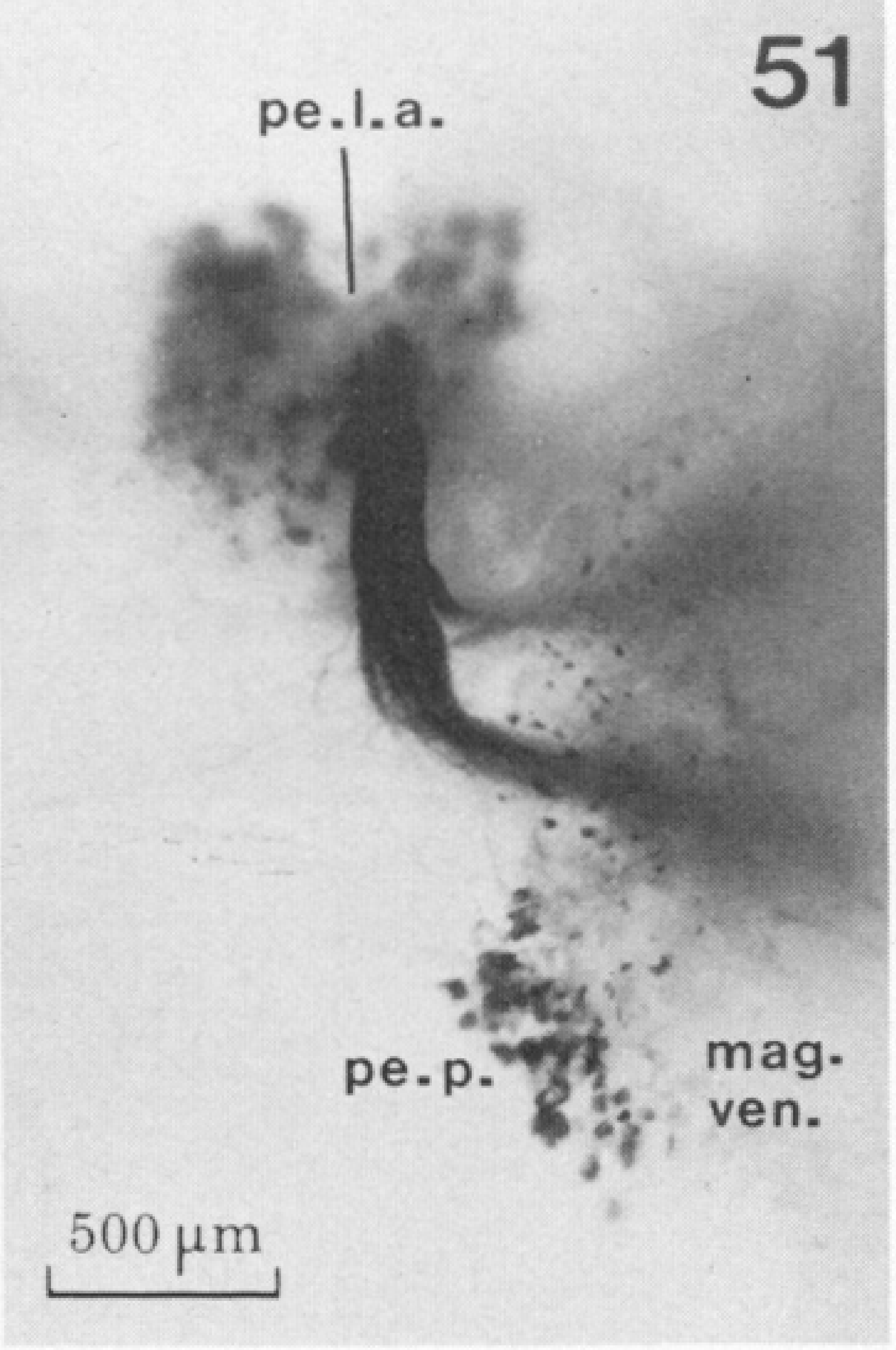

FIGURES 43–51. For description see p. 175.

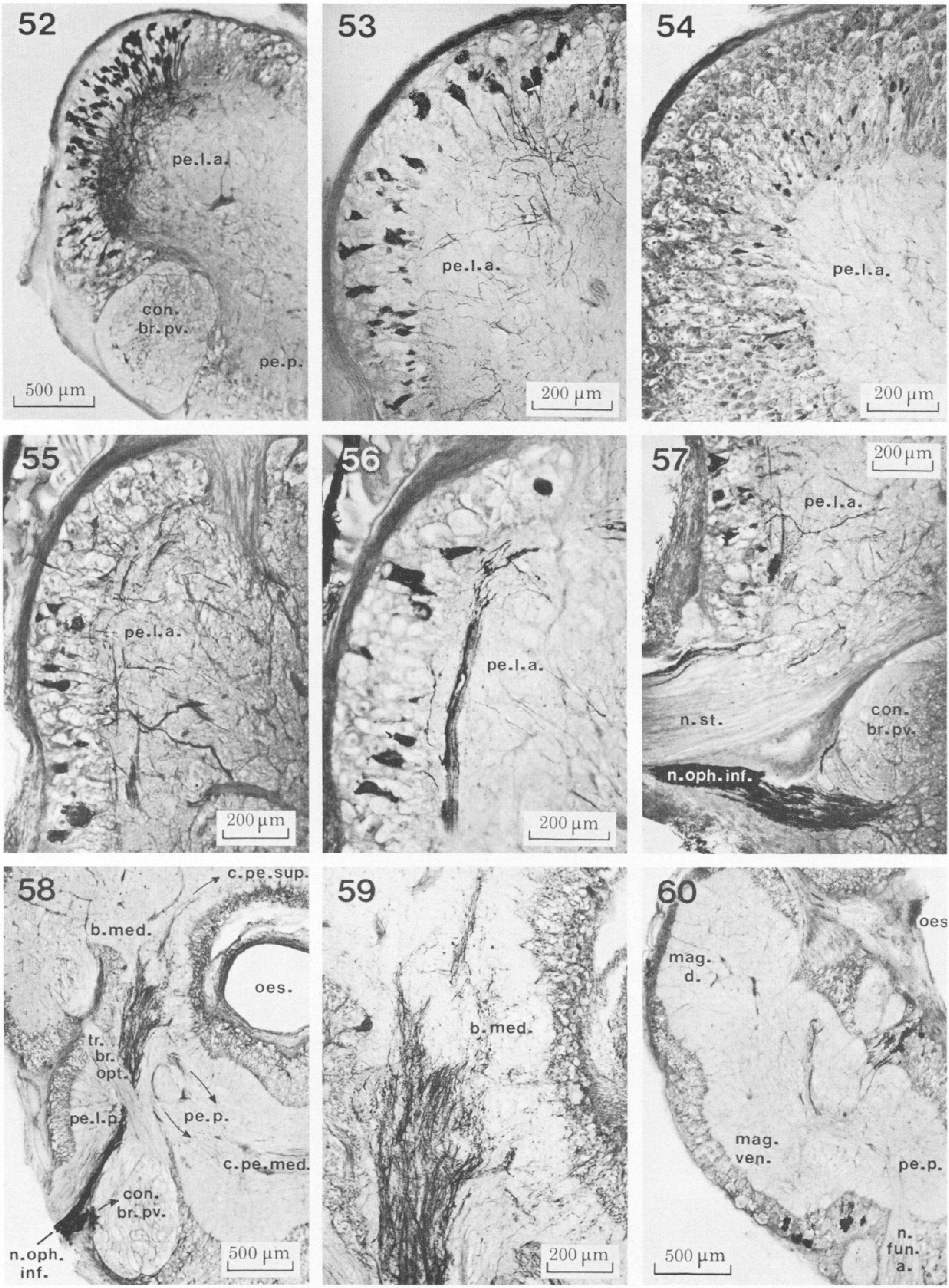

FIGURES 52–60. For description see p. 175.

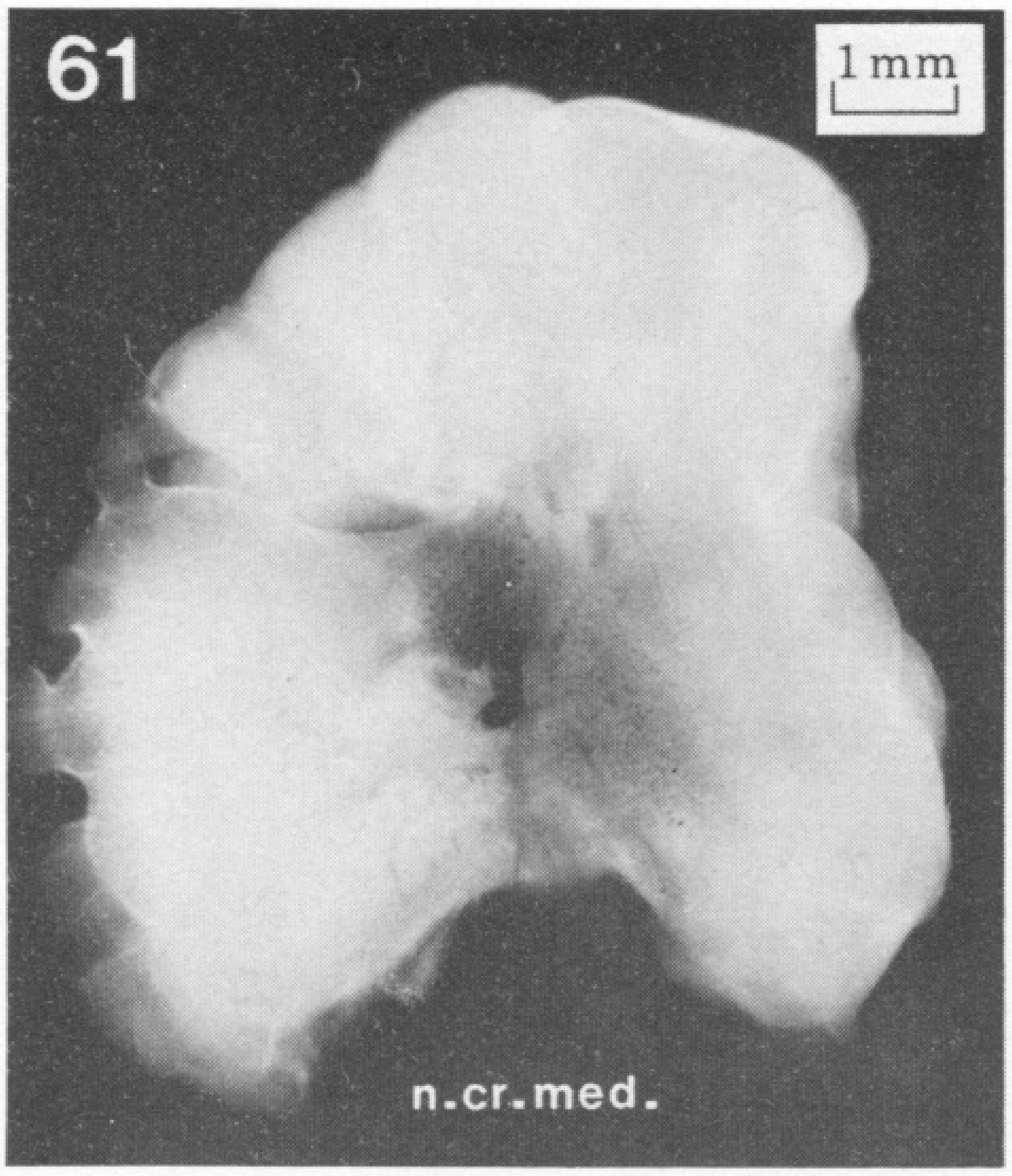

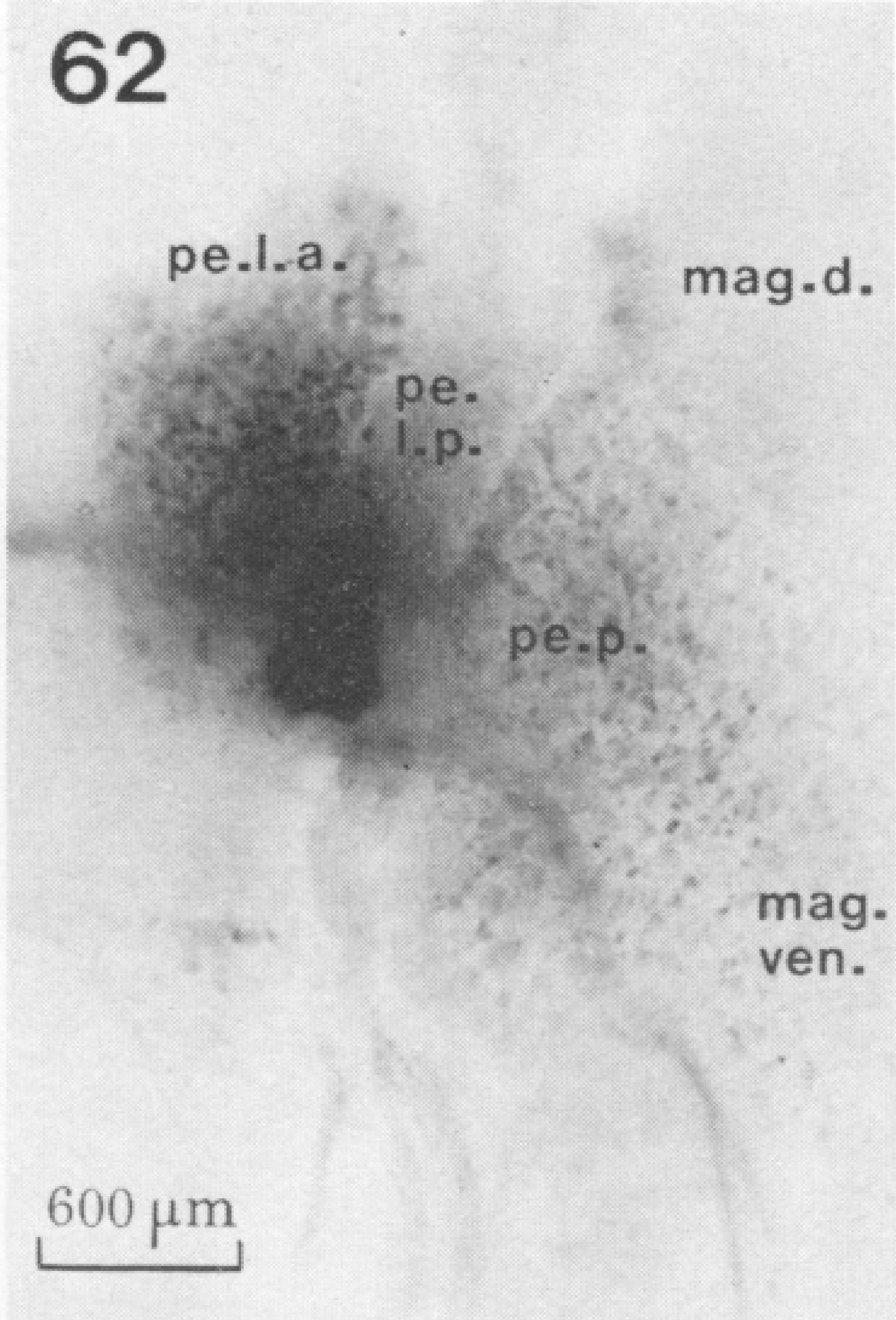

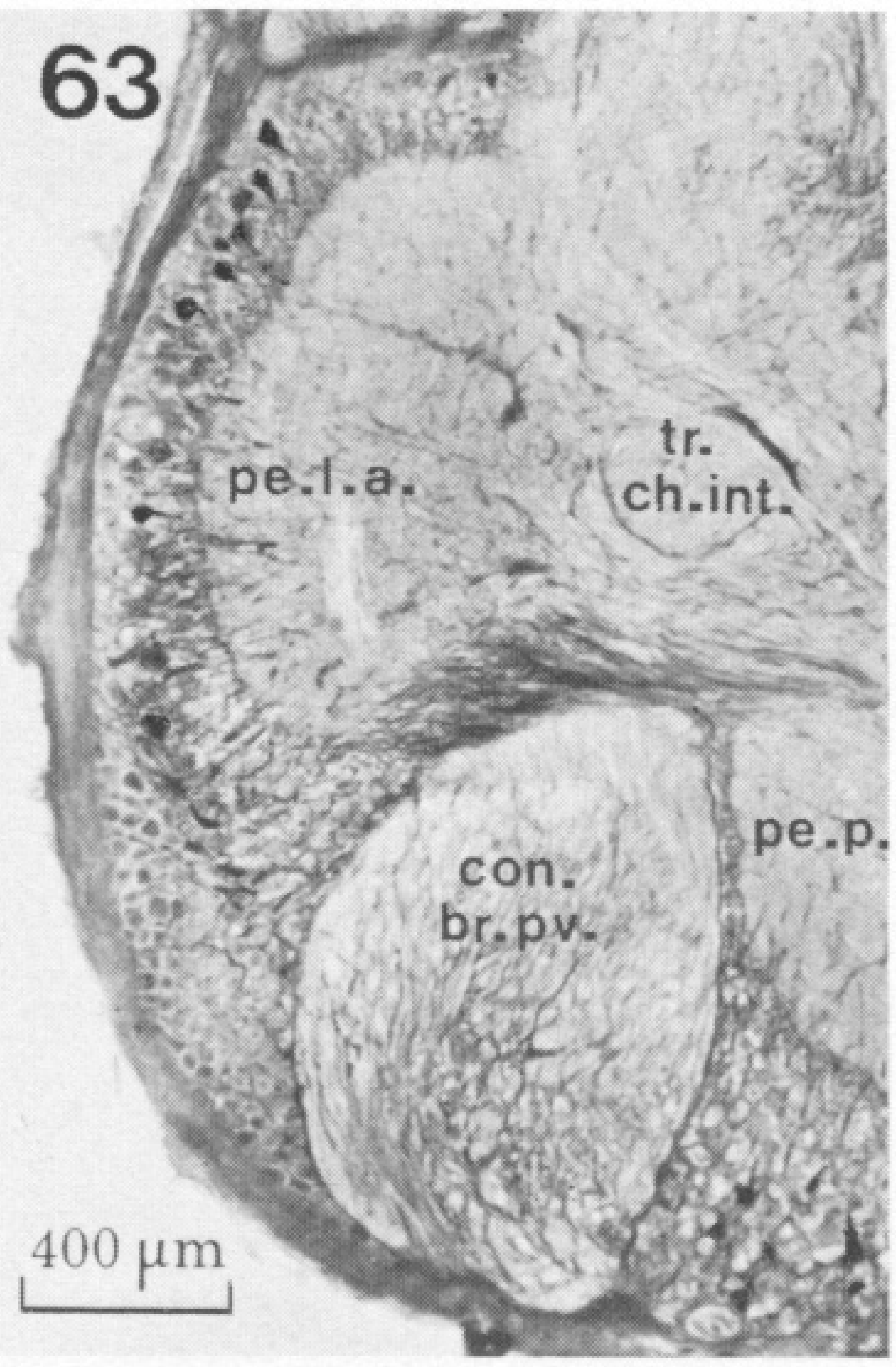

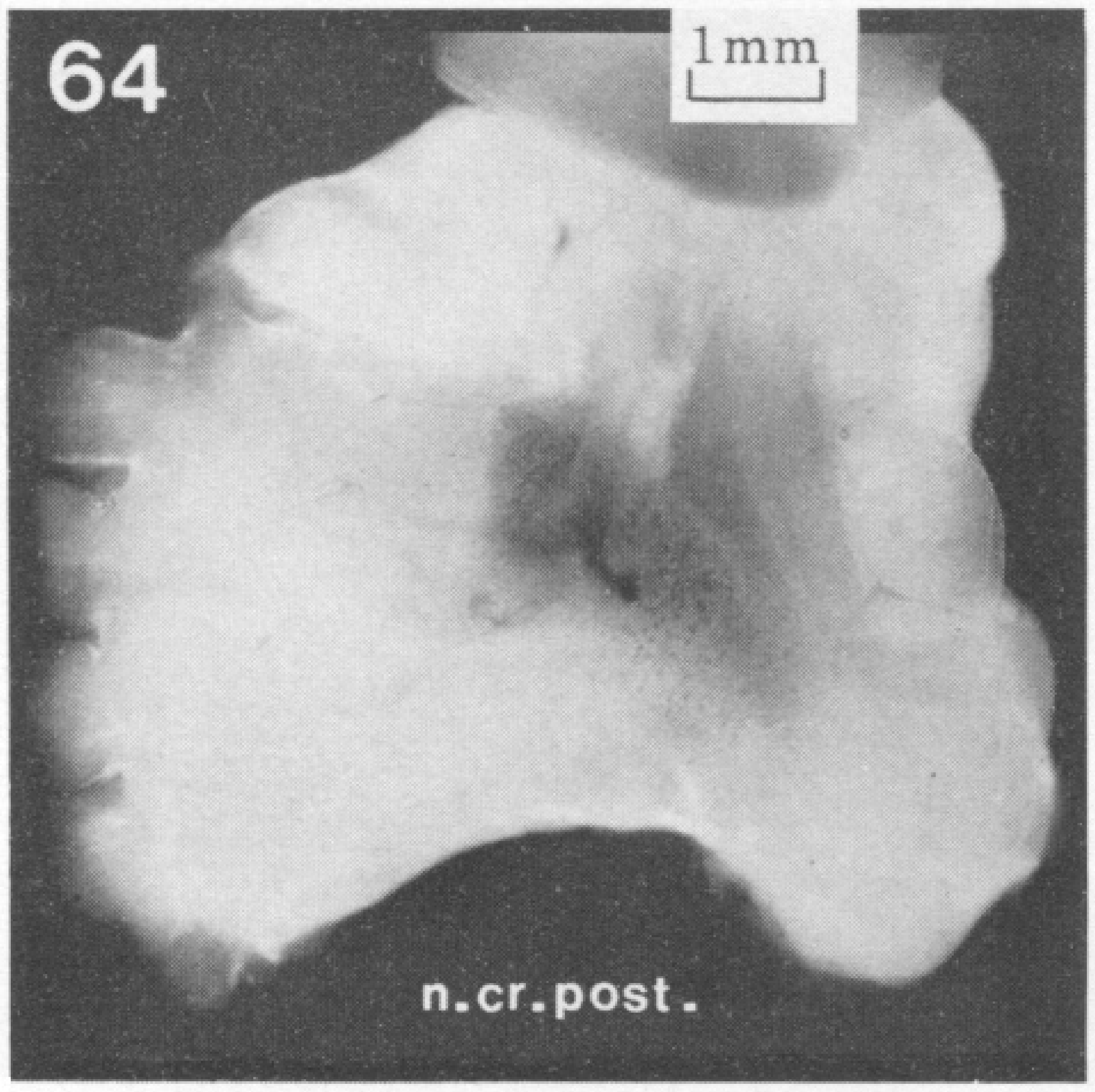

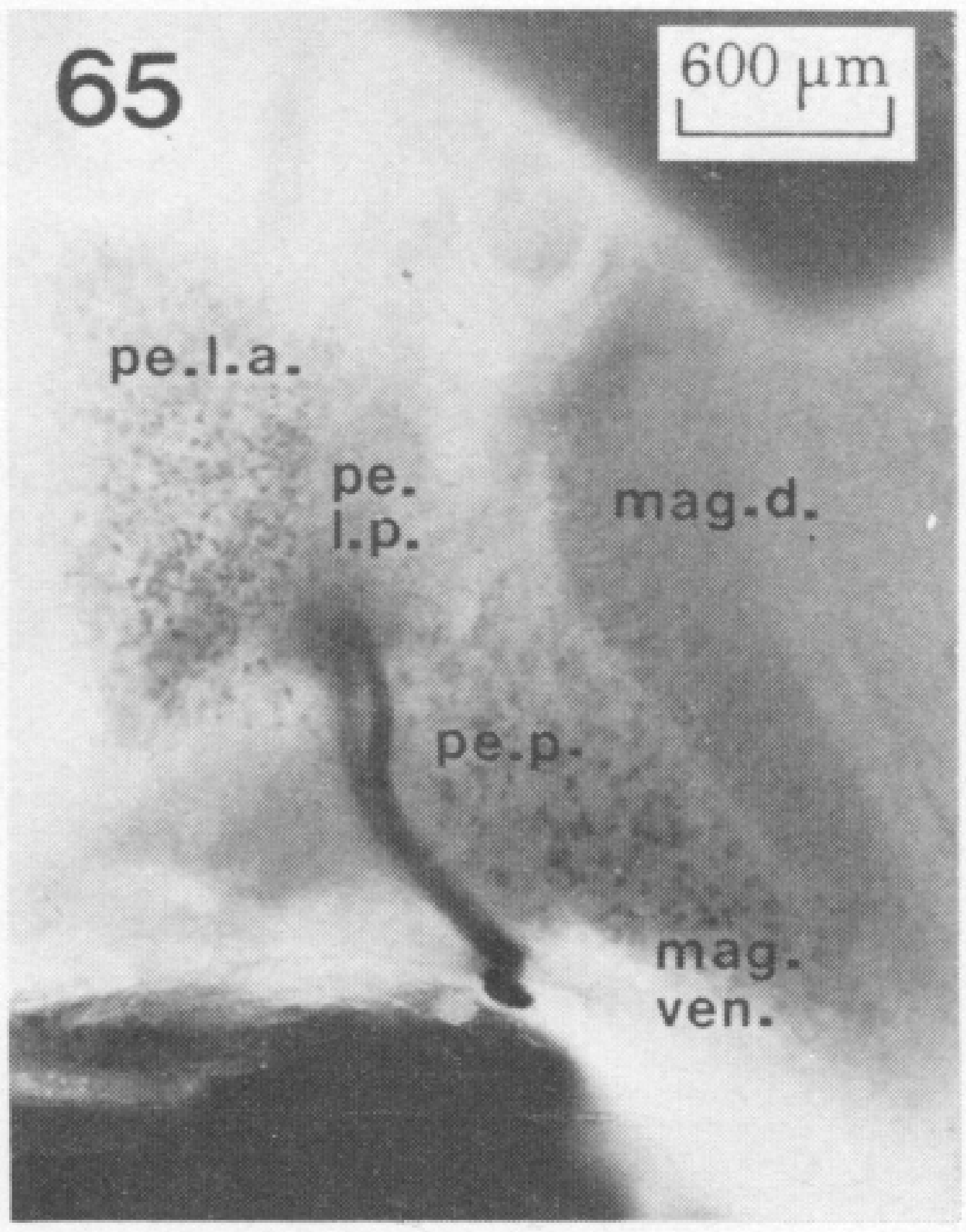

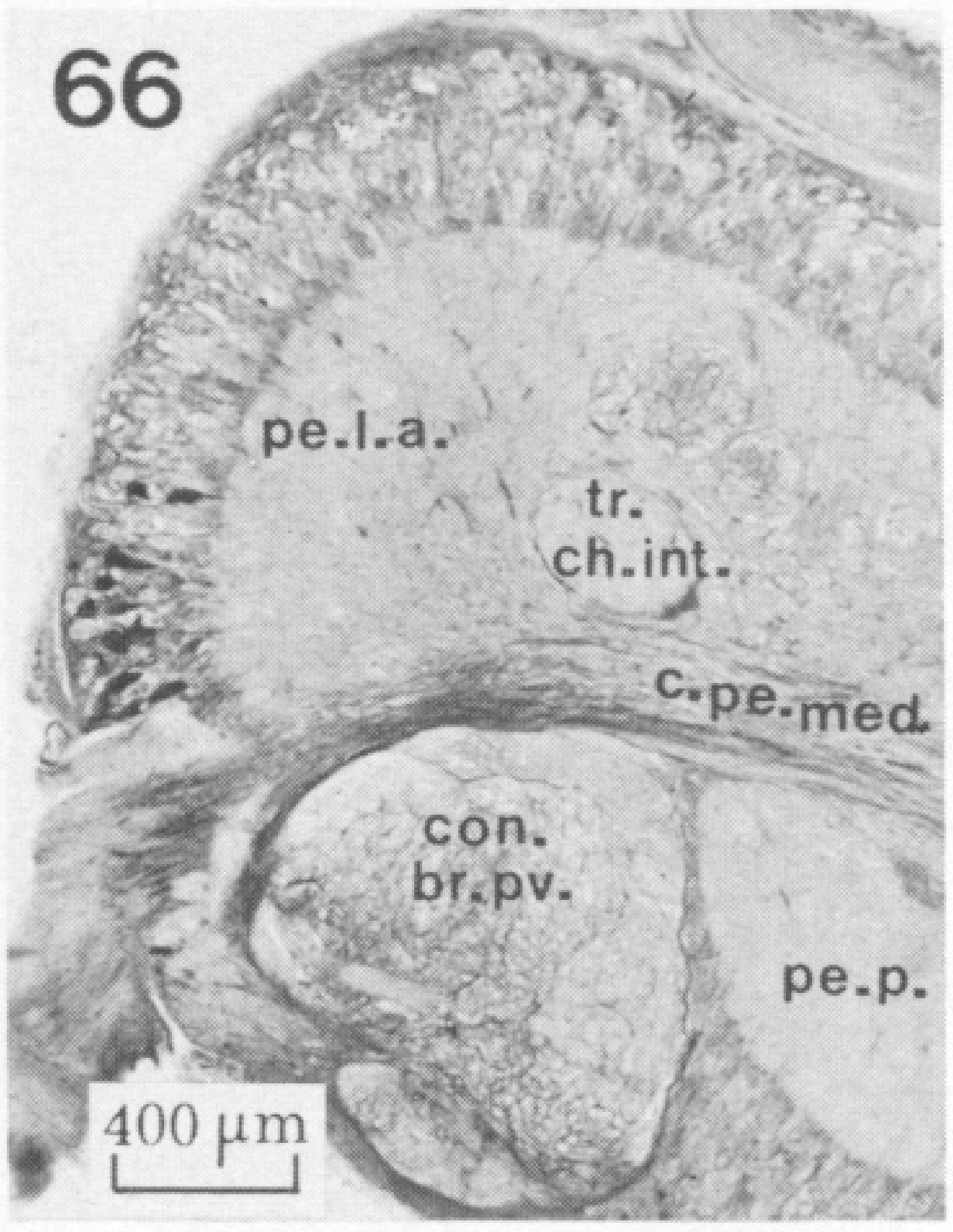

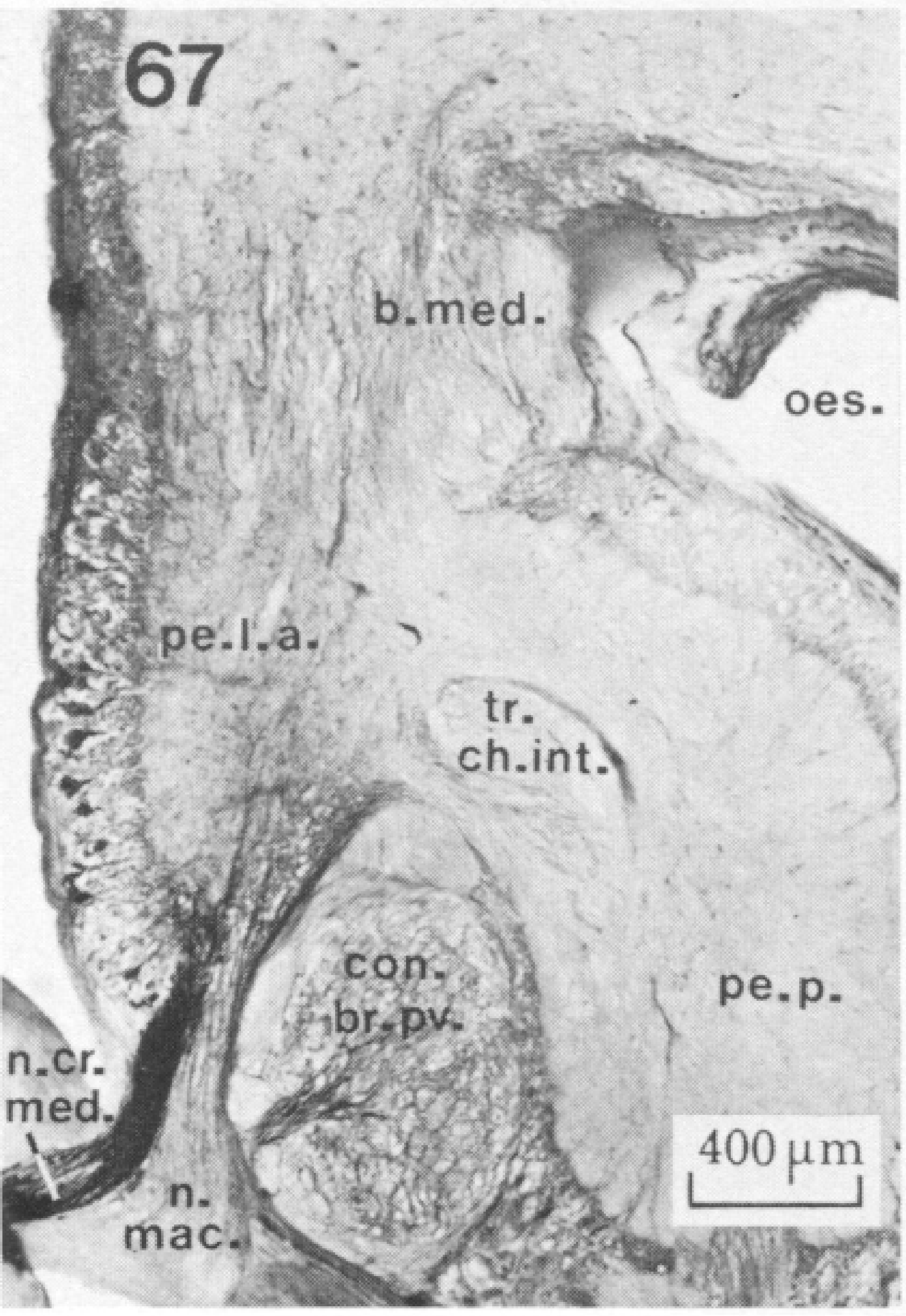

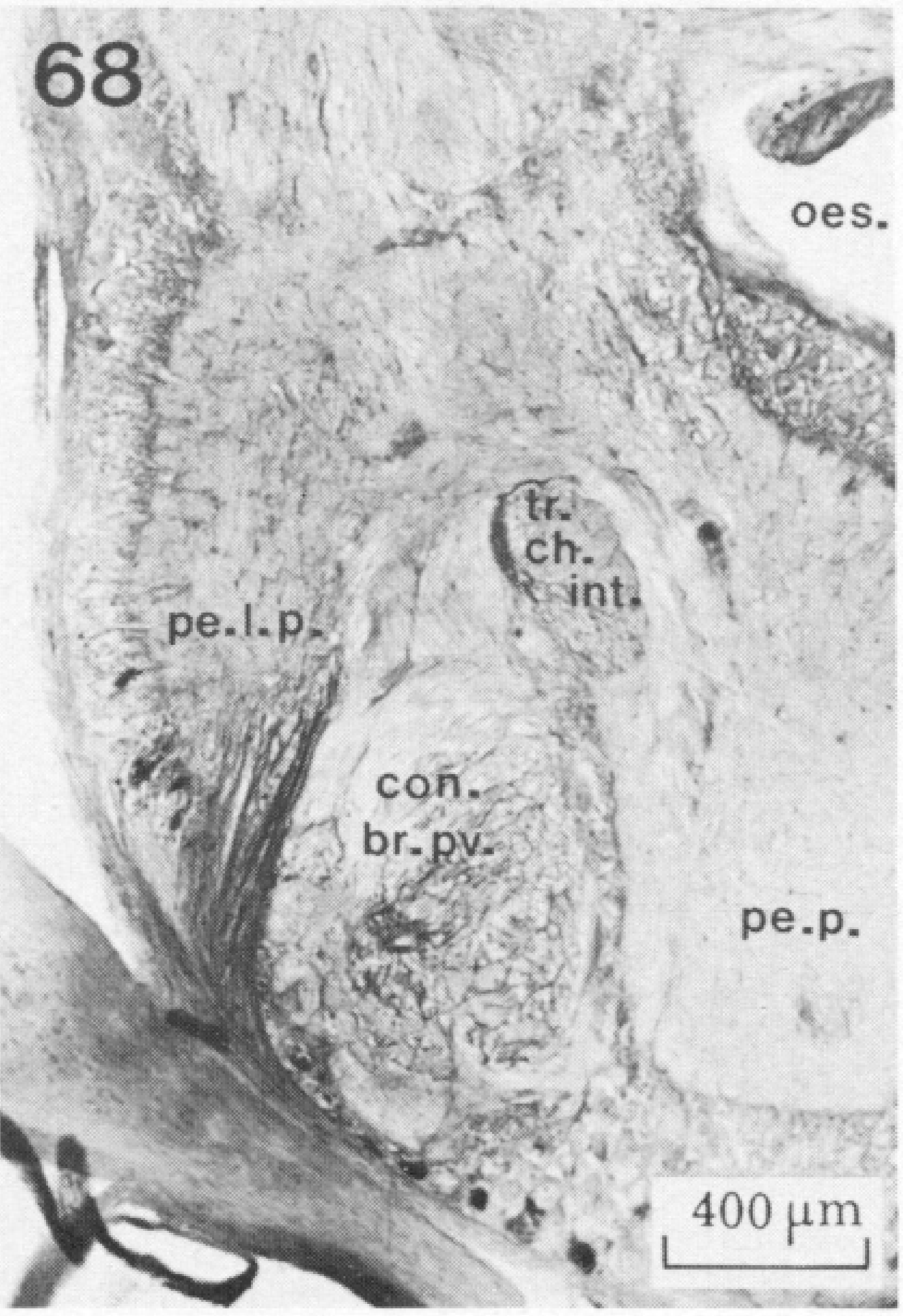

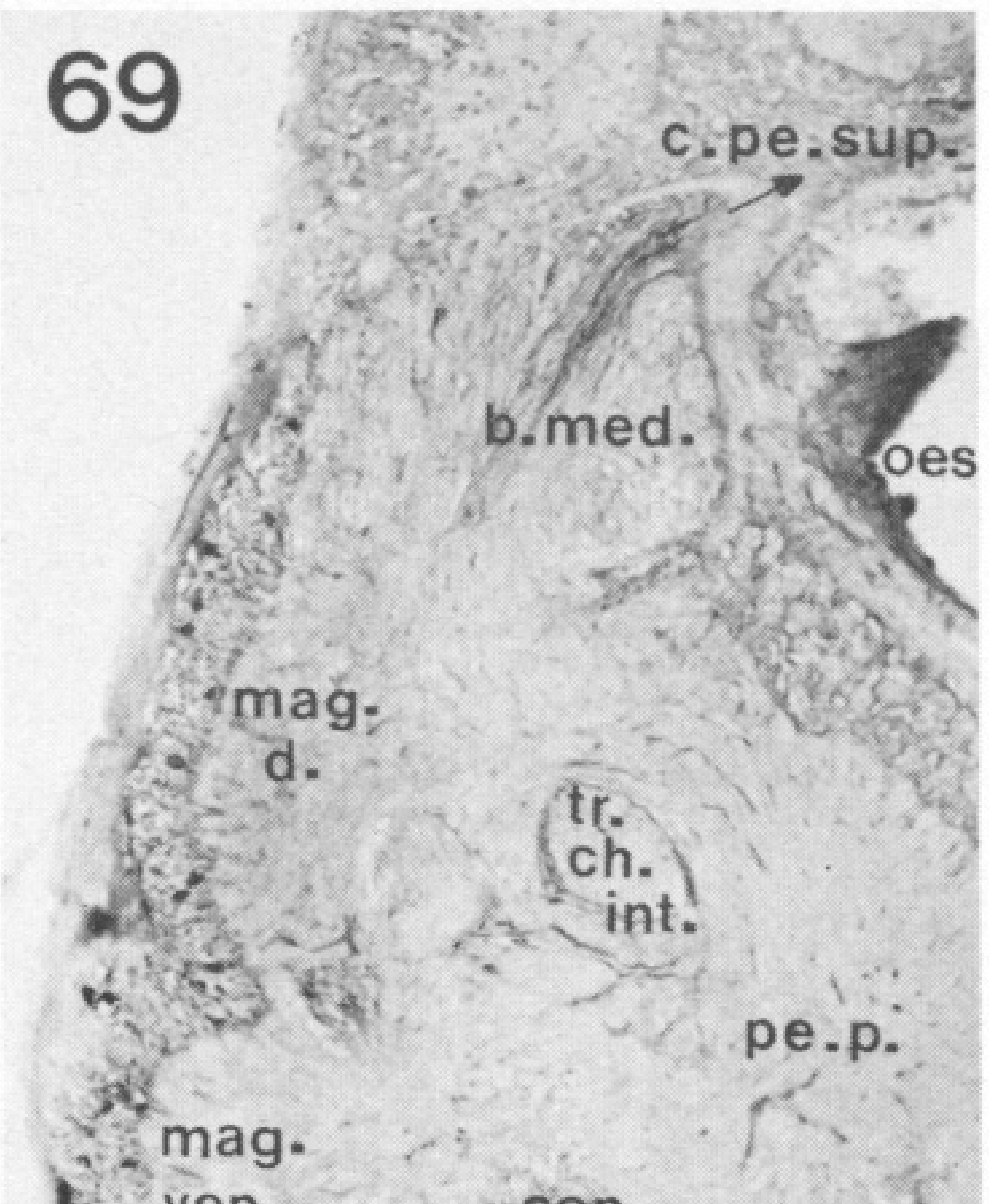

FIGURES 61–69. For description see p. 175.

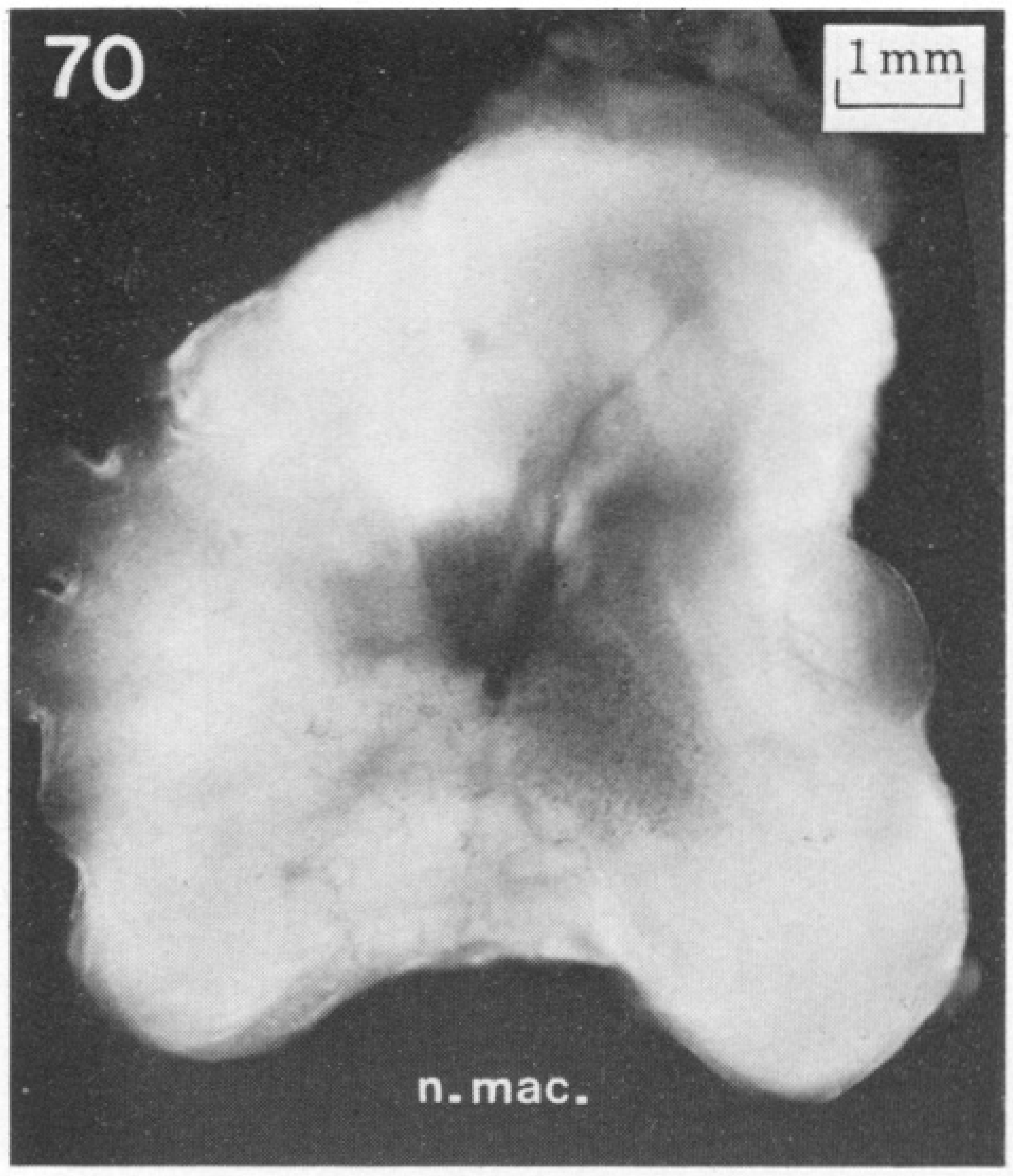

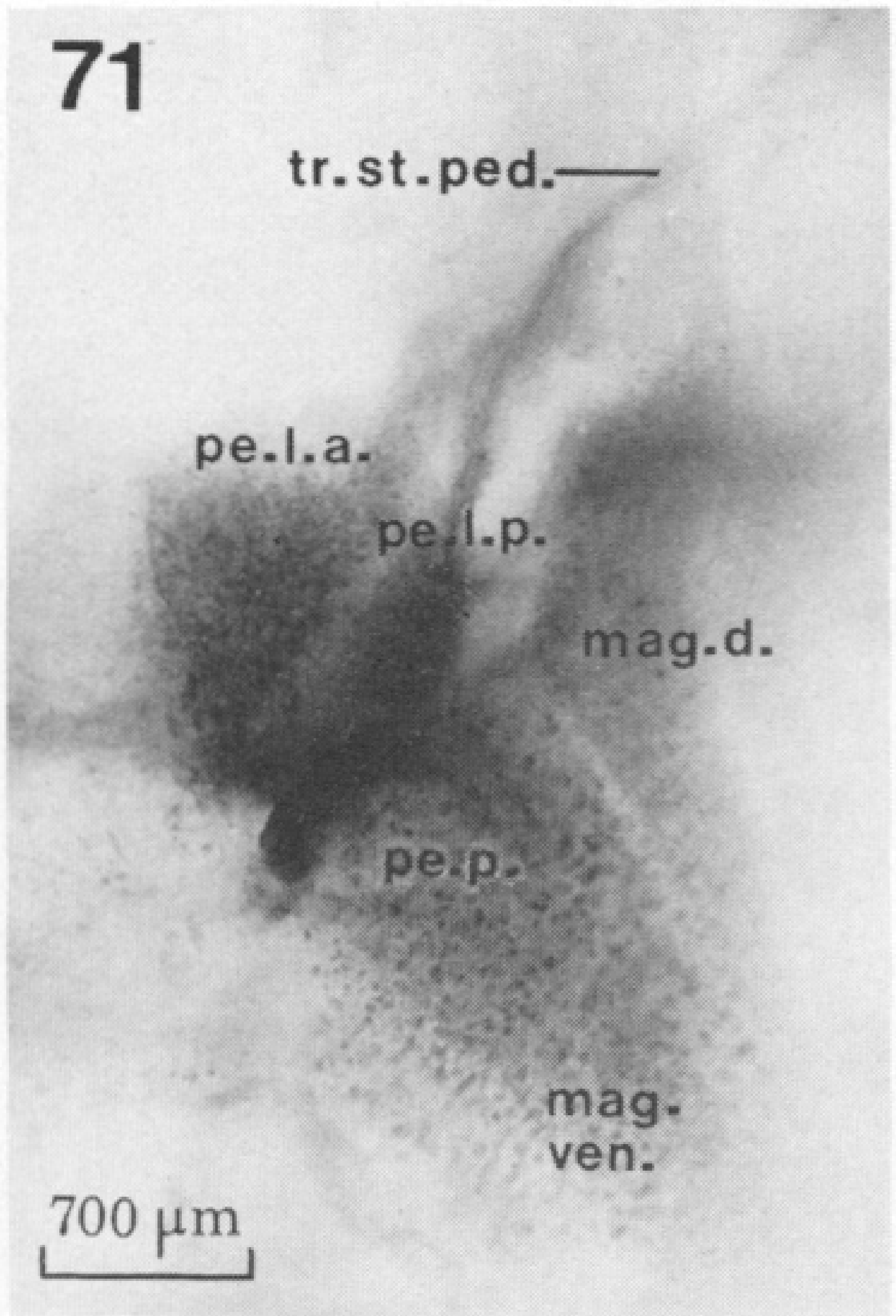

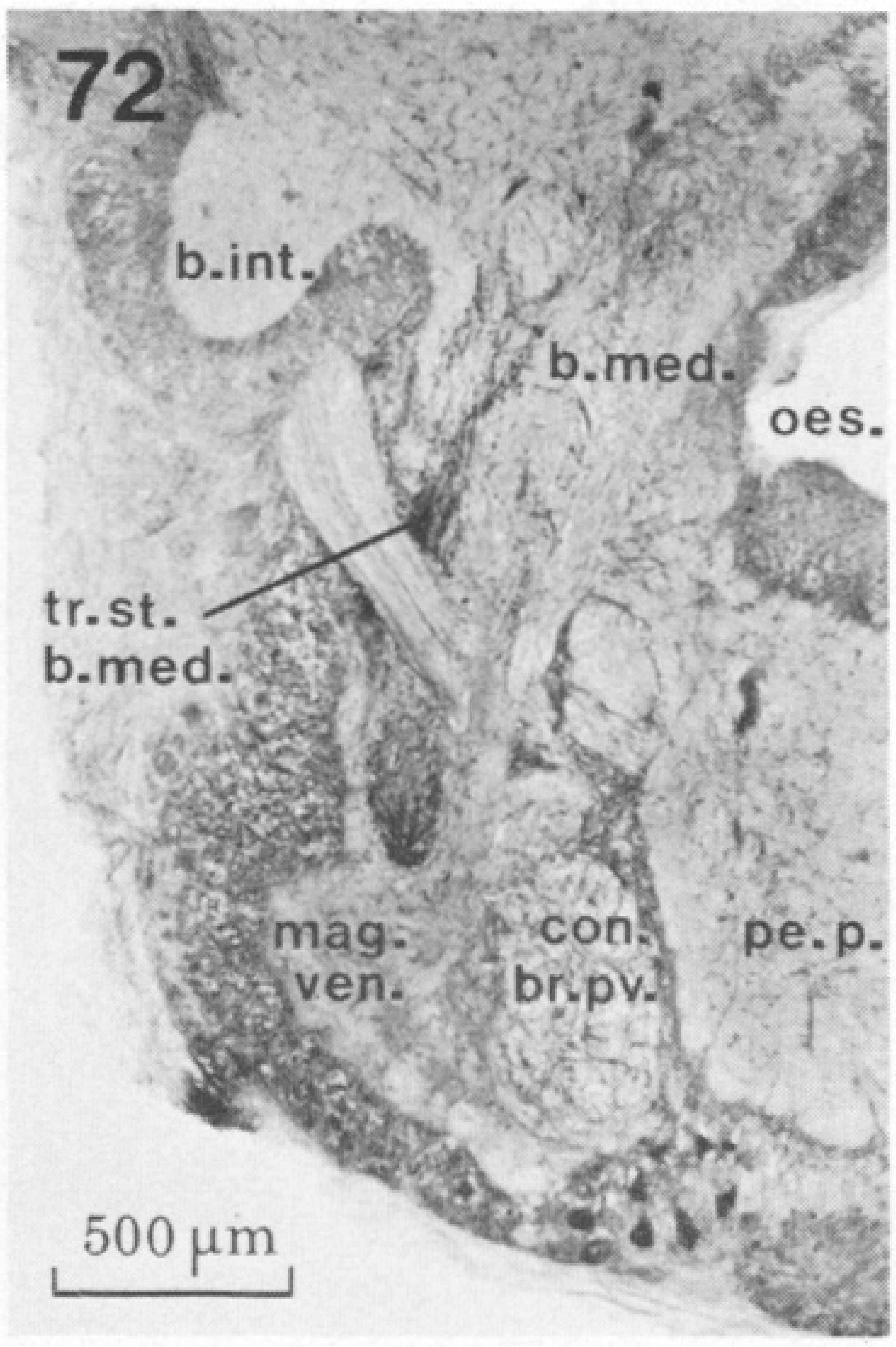

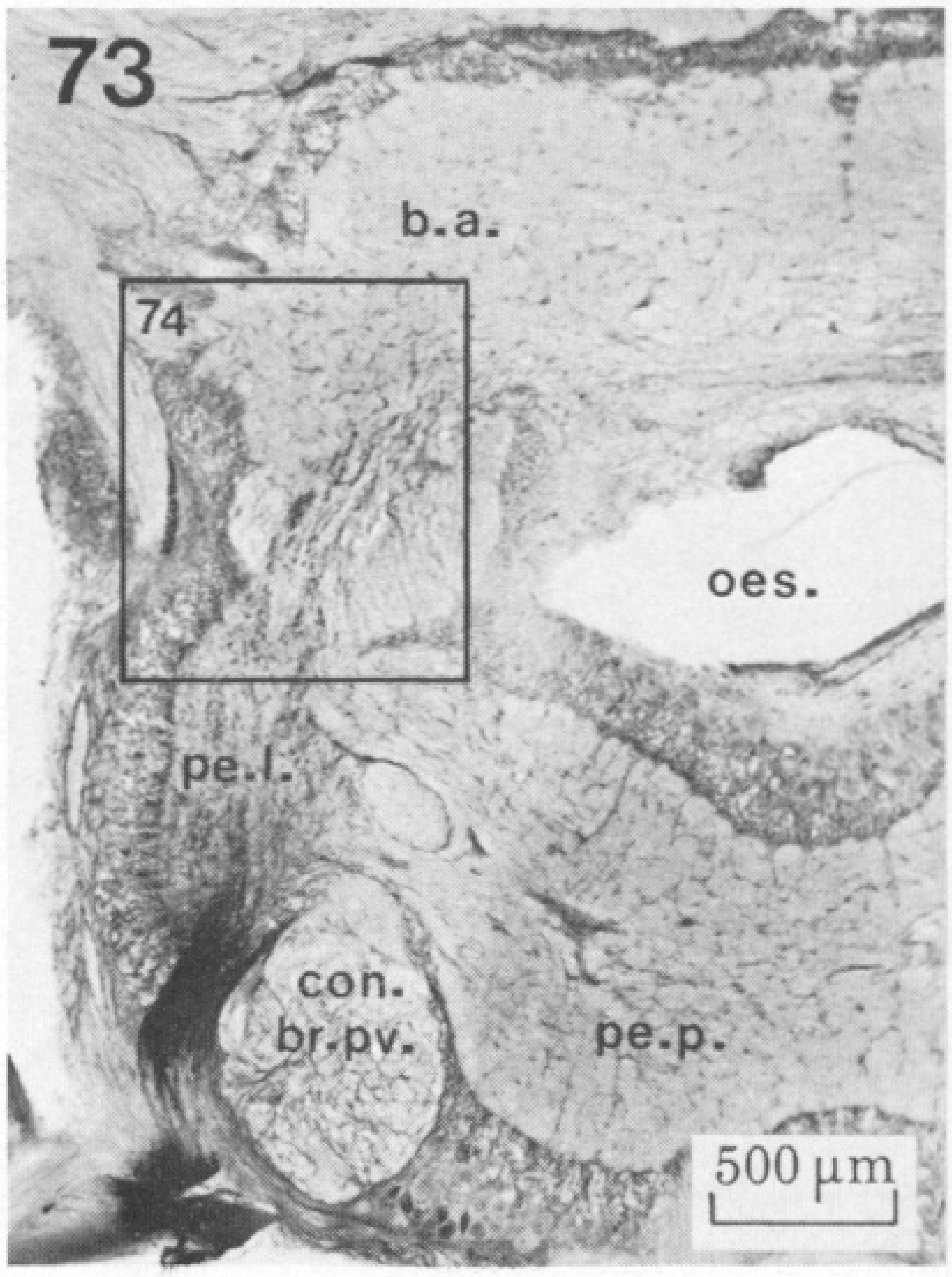

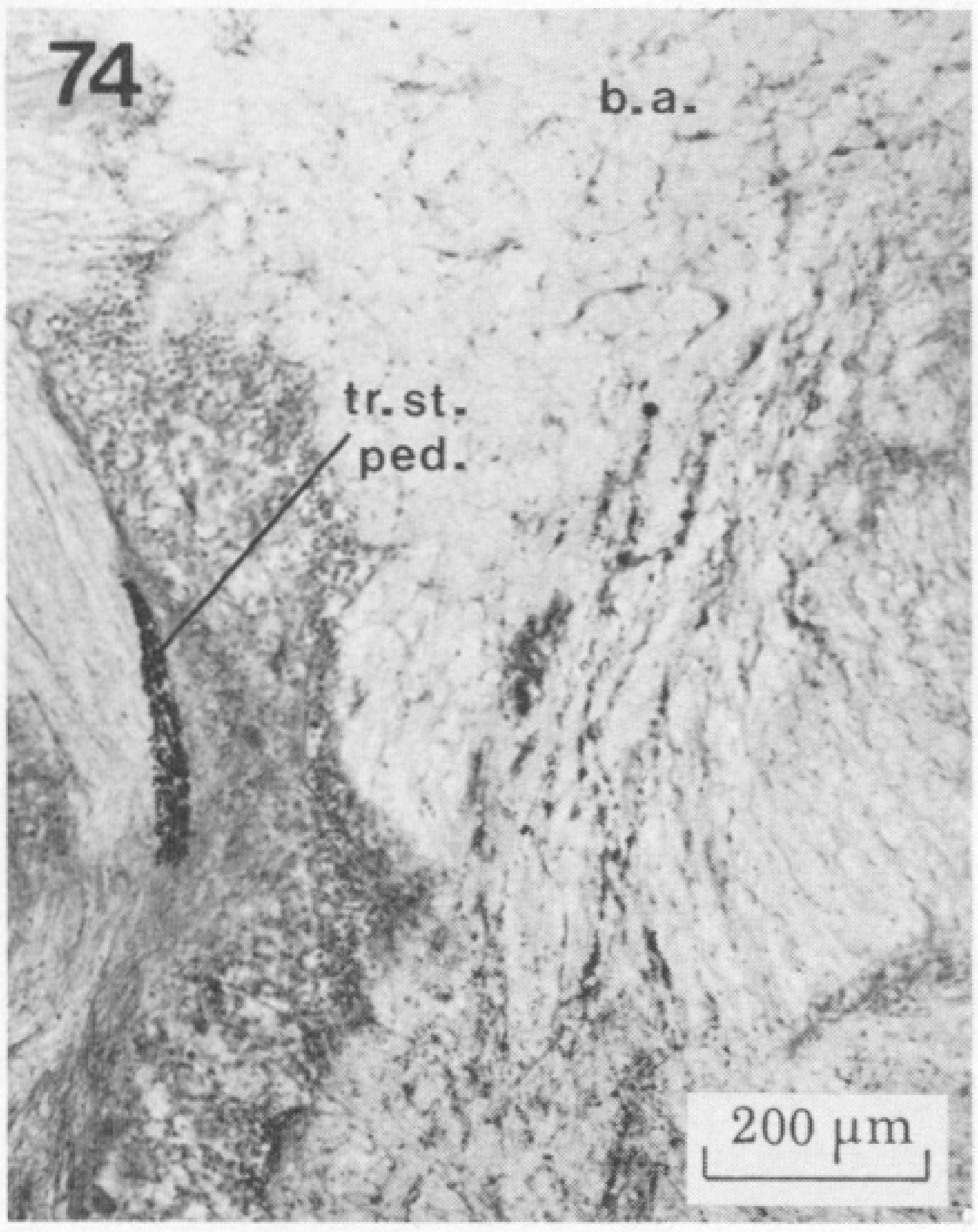

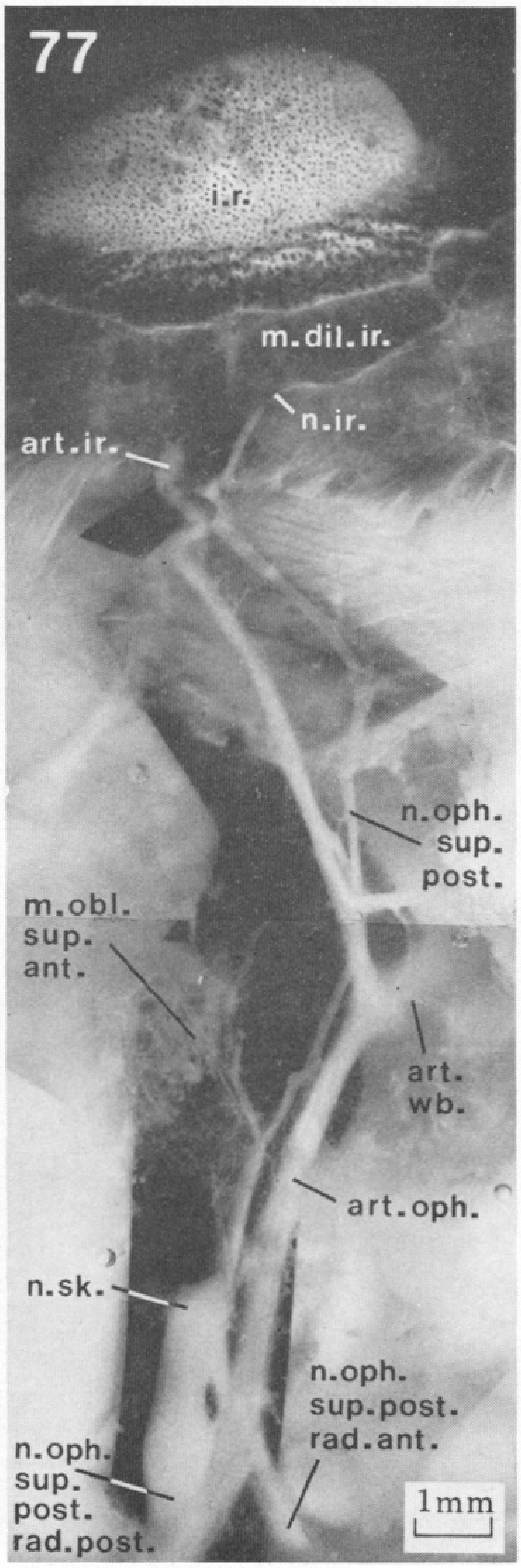

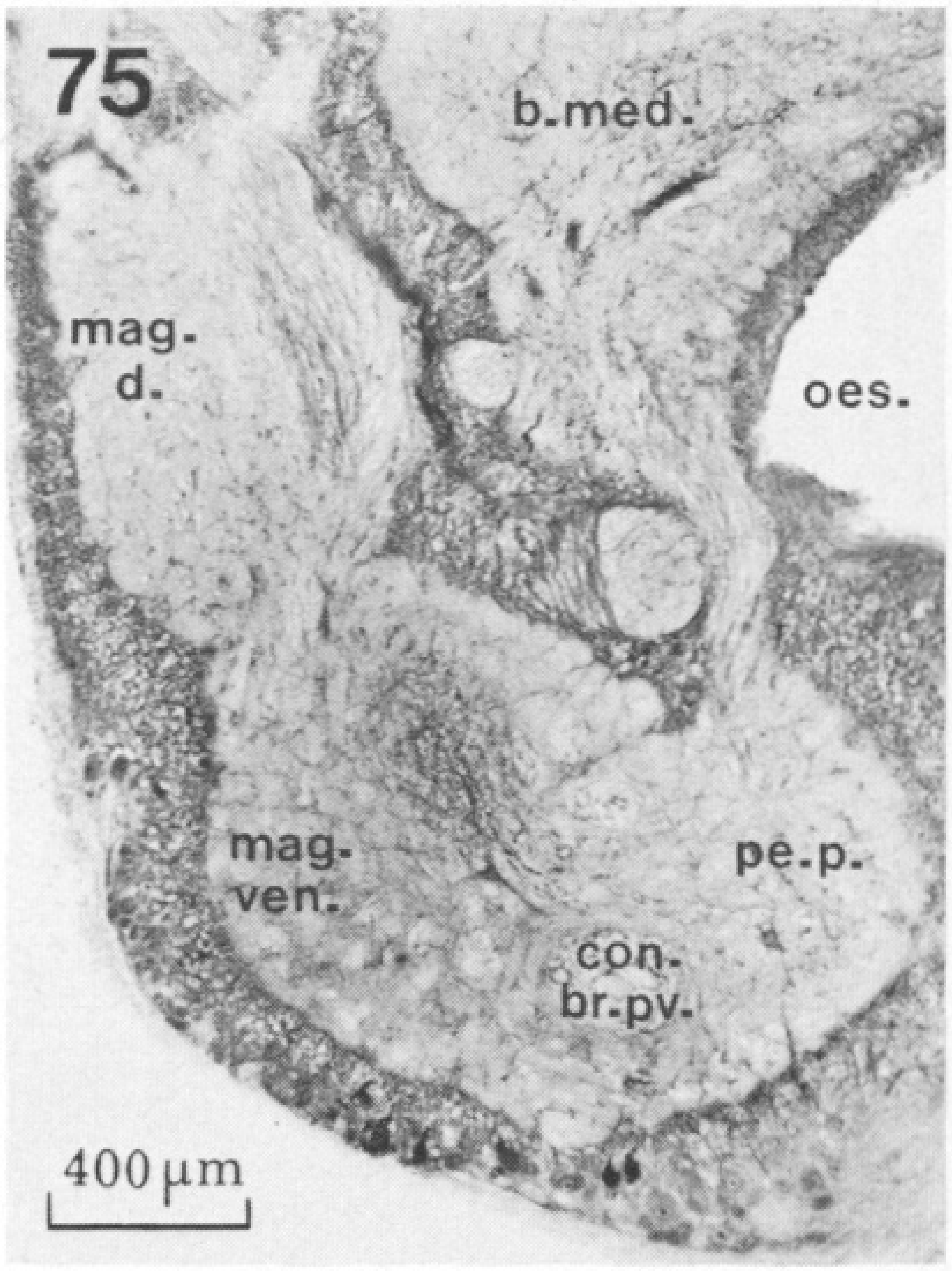

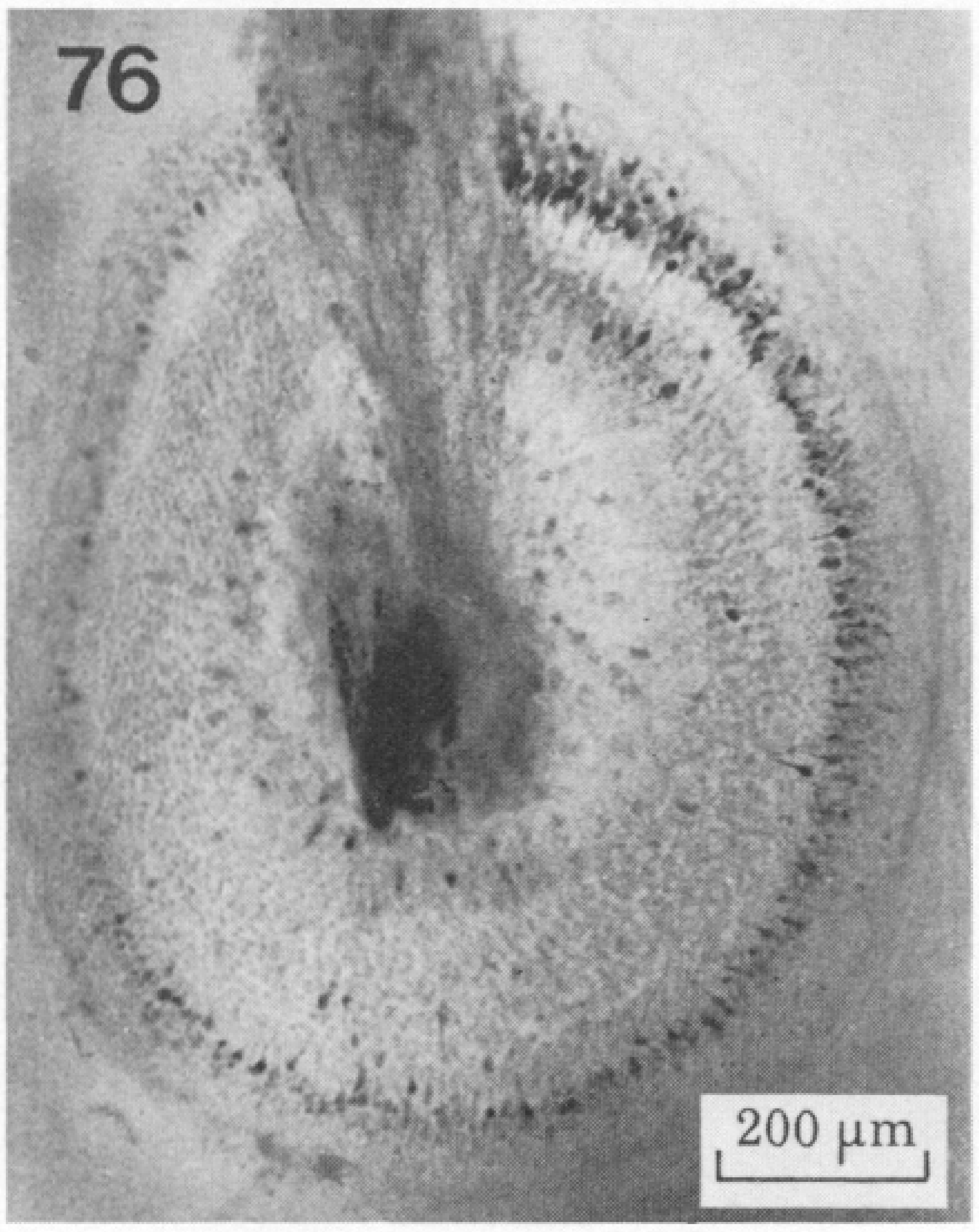

FIGURES 70–77. For description see p. 176.